

CASE REPORT

DOI: 10.15517/IJDS.2020.41206

Received:
24-I-2020

No-Prep Semidirect Composite Resin Veneer. A Step-by-Step Case Report in a Deciduous Canine with a One-Year Follow-Up

Accepted:
16-III-2020

Published Online:
25-III-2020

Carilla de resina semidirecta sin preparación. Un reporte paso a paso en un canino deciduo con seguimiento de un año

Gerardo Durán O. DDS, MSc¹; Katherine Zamora²

1. Assistant Professor. Facultad de Ciencias de la Salud, Universidad Arturo Prat, Iquique, Chile.
2. Undergraduate Student. Facultad de Ciencias de la Salud, Universidad Arturo Prat, Iquique, Chile.

Correspondence to: Dr. Gerardo Durán O. - gerardo.duran@unap.cl

ABSTRACT: The presence of deciduous canines in adulthood may be of aesthetic concern for patients. Many clinical alternatives include surgical and orthodontic treatment. Since patients search for highly esthetic results and more conservative alternatives, the present clinical report describes a treatment for deciduous canine through an indirect composite resin veneer and an indirect composite resin fragment restoration in a premolar to improve esthetic outcomes with a one-year follow up.

KEYWORDS: Composite resin veneer; Indirect composite veneer; Deciduous canine; Restoration.

RESUMEN: La presencia de caninos deciduos en adultos puede ser de preocupación estética por parte de los pacientes. Diversas alternativas clínicas pueden incluir tratamientos quirúrgicos y ortodóncicos. Desde que los pacientes buscan por resultados de alta estética y cada vez más conservadores, es que el presente caso clínico describe el tratamiento de un canino deciduo mediante una carilla indirecta de resina compuesta junto a un fragmento indirecto de resina de un premolar con el fin de mejorar los resultados estéticos, y con un año de seguimiento.

PALABRAS CLAVE: Carilla de resina; Carilla indirecta; Canino deciduo; Restauración.

INTRODUCTION

Nowadays, patients request for more esthetic and imperceptible treatment in the anterior dentition (1), which forces the clinician to perform more exquisite Restorative Dentistry (2). Likewise, the fast development in dental materials technology have allow for more conservative procedures and long-lasting restorations, (3-4) ensuring the conservation of pulp vitality and the functionality of tooth structure (5).

Composite resin materials have also evolved, achieving improvements in the optical and biomechanical properties, resembling more and more the natural dental structure (6-7). The above has allowed to extend their therapeutic indications at present, being able to be used as indirect resin veneers for anterior dentition with similar survival rates than ceramic laminate veneers at short-term (8-9). To ensure better performance of indirect composite resin restorations, the post-curing process and the bonding protocol of the restoration becomes most relevant and requires the clinician to highly respect every protocol in order to reduce any possible clinical mistake that could compromise a long-lasting result.

The following case report, describes a simple step-by-step adhesive procedure of an indirect composite resin veneer over a deciduous canine in an adult patient together with an indirect composite resin fragment to enhance harmony and function in a premolar cemented with pre-heated composite resin.

CASE REPORT

A 40-year-old female patient presented to the private practice of one of the authors with a chief complaint of unaesthetic concern of her deciduous teeth #63 (Figure 1). According to the clinical examination and x ray, tooth #23 was non erupted and was retained on the palatal

region Tooth #63 presented as a dark tooth with a non-carious cervical lesion at the vestibular aspect and an obvious smaller size (Figure 2).

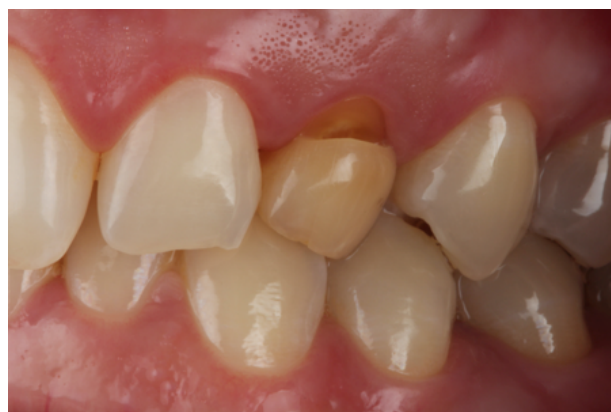

Figure 1. Initial situation.

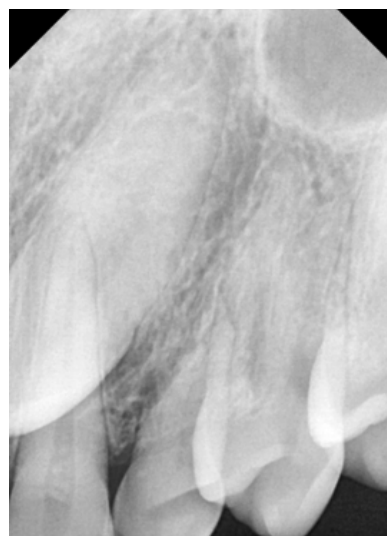

Figure 2. Initial X-ray image.

After talking with the patient all the possible alternatives, she decided not to remove her deciduous tooth and try the most conservative approach as possible. For this reason, considering costs and the functionality of tooth which requires mechanical properties improvement, it was decided to perform an indirect composite resin veneer together with a small indirect composite resin fragment in the mesial aspect of tooth #24. For this purpose, the patient signed an informed consent and agreed upon her case for publication.

After impression taking with polyvinyl-siloxane and once the restorations were finished, the bonding procedure will be performed as follows:

Treatment surface of the indirect restorations:

- Airborne-particle abrasion with 27micron aluminum oxide or 30micron silica-coating at 1cm of distance, 2,3 bar pressure and 2 seconds (Figure 3. A). This will allow a rough surface that will ensure micromechanical retention of a polymerized monomer within the surface.
- Chemical cleaning of the surfaces with 35% phosphoric acid during 60 seconds followed by rinsed-off with water until a clean surface is obtained (Ultra-etch, Ultradent Inc.) (Figure 3. B).
- No silane is applied. According with several authors, the use of silane after sandblast won't improve bond strength of the bonding system over indirect composite resin restorations (10).
- Application of a thin layer of a hydrophobic HEMA-free resin (Heliobond, Ivoclar Vivadent) (Figure 3. C).
- Do not light cure and leave the restorations out of light exposure. Polymerizing this layer without taking care the amount of applied resin may change fitting of the restoration over the prepared tooth, being possible that the restoration won't fit or adapt due to the shape of the deciduous canine.

Tooth treatment surface:

The procedure must be performed under rubber dam isolation.

- Airborne-particle abrasion with 27micron aluminum oxide or 30micron silica-coating.
- Clean the surfaces with plenty of water for 60 seconds.
- Apply 35% Phosphoric acid for 30 seconds at tooth surfaces, and rinse-off with water for the same time (Ultra-etch, Ultradent Inc.) (Figure 4. A).
- Apply a thin layer of primer, rubbing the dentin for 20 seconds (in case of tooth #H), and gently over the enamel without rubbing (Primer, Optibond FL, Kerr).
- Apply a thin layer of bonding gently over the enamel and dentin, do not rub, do not polymerize (Bonding, Optibond FL, Kerr). To polymerize may interfere with the settlement of the restorations (Figure 4. B).

Parallel to these procedures, the selected composite resin must be warming up according to the manufacturer instructions, so that the clinician can quickly charge the pre-heated composite resin over the treated surface of the restorations (Figure 3.D), and so then position them on the teeth with soft pressure. At that moment, pressure must be done vertically and horizontally towards the tooth, allowing the exit of pre-heated resin through the interphase (Figure 5 and Figure 6). The excess of resin must not be light-cured and then cutted with a scalpel, this could leave areas of microleakage at the interphase in case of lack of adaptation. Eliminate and drain excesses of resin through the interphase could ensure sealing voids or gaps. A final control image after 1 year is shown in Figure 7.

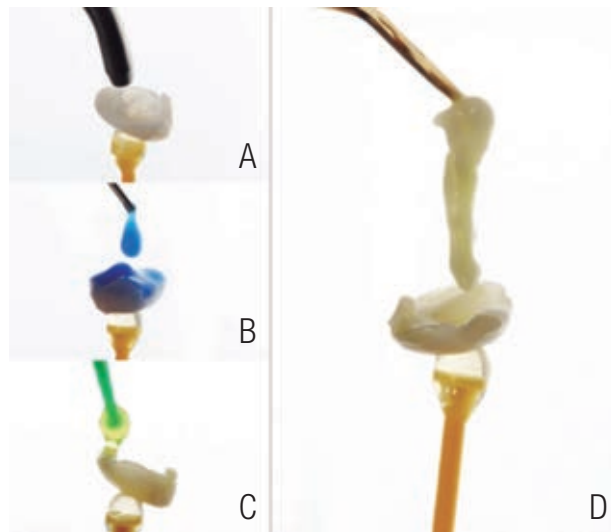


Figure 3. Indirect composite resin surface treatment. A, sandblast of the intaglio surface of the restoration. B, cleaning with phosphoric acid. C, application of bonding. D, pre-heated composite resin for cementation charged into the intaglio surface of the restoration.

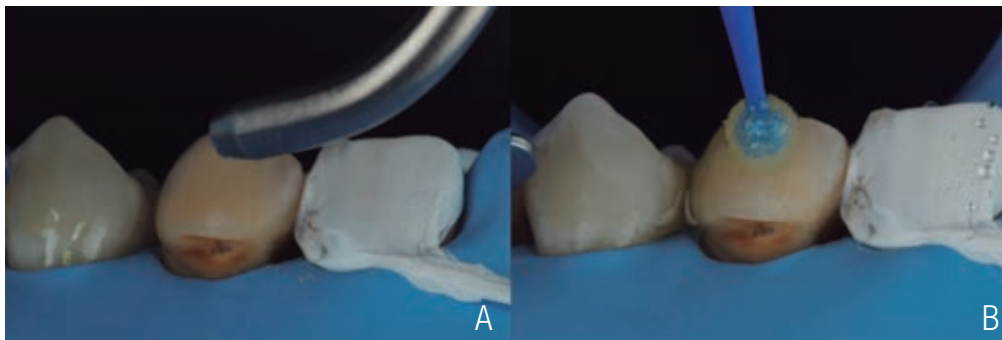


Figure 4. Tooth surface treatment. A, Phosphoric acid application. B, Application of bonding.

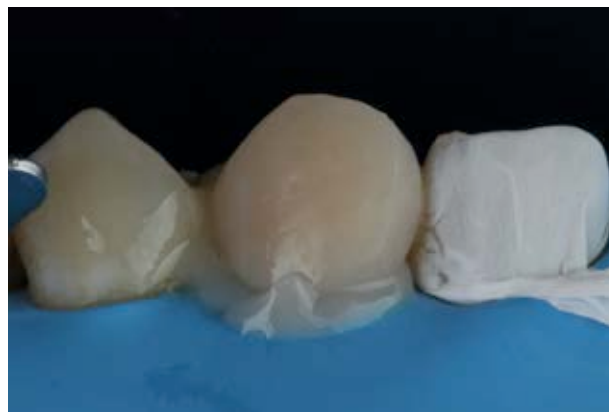

Figure 5. Cementation of the veneer.

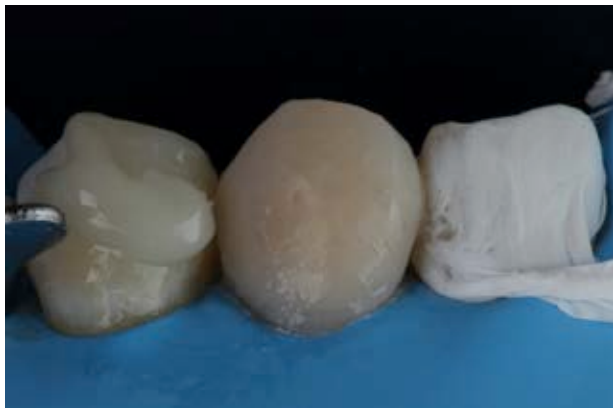

Figure 6. Cementation of the indirect composite resin fragment.

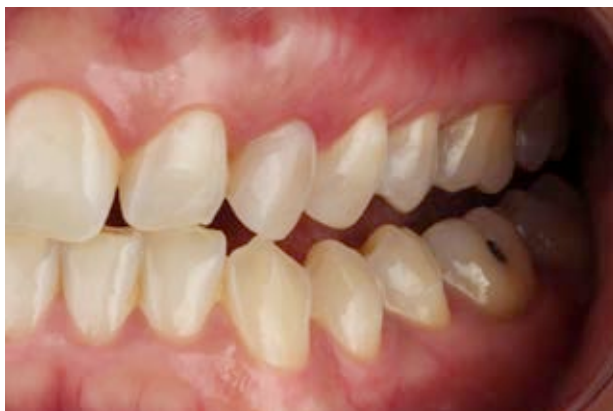

Figure 7. One-year follow up. Clinical appearance in function.

DISCUSSION

Many options can be assessed when a non-erupted canine is found. According to Francisco S *et al.*, (11) extraction of the primary canine may be performed allowing the spontaneous eruption of the permanent tooth or with transplantation of the retained canine to the correct site. Spontaneous eruption may not be suitable if the non-erupted canine is impacted or the orientation does not allow for passive eruption through the alveolar space left by the deciduous canine. In such cases, the transplantation or implant placement may be indicated (12-13).

Orthodontic traction is another clinical option that includes an initial surgical approach to expose the retained canine and to allow the

installation of orthodontics appliances. Its principal advantage is related to optimal tooth positioning but requires more clinical time to accomplish. According to Montenegro *et al.*, many factors must be considered for orthodontic traction that conditions the clinical time needed to correctly position the canine such as distance to the alveolar space, angulation, position inside the maxillary arch, root dilacerations and resorptions, and ankyloses (14).

In this particular case, the patient rejected for every surgical approach and also for long lasting treatment. Based on this requirement, the possibility of restoring the deciduous canine was analyzed. The choice to perform a ceramic crown was evaluated, but considered less conservative and the reduction of tooth it is of concern given the reduced size of the tooth. This approach has been presented by Fernandes *et al.*, (15) obtaining acceptable esthetic results independent of the average size of the deciduous canines.

More conservative treatment than ceramic crowns can include ceramic veneers. In this type of cases, Bin-Shuwaish (16) recommends to maintain occlusion in group function in order to reduce stress and to eliminate destructive forces over the deciduous canine. Even so, tooth preparation is still needed.

Another conservative approach may include direct composite resins. To consider this clinical option may bring several advantages such as no need for tooth preparation, reparability, reversibility, acceptable esthetic outcomes, less clinical appointments and reduced costs (17).

Indirect composite resins can be also considered as a reliable alternative, since it brings all the advantages of a composite resin restoration. Also, their clinical performance is better since the post-curing process allow for mechanical properties improvement of the restoration because of the increased degree of conversion of the monomers.

This has been proved by Benitez Sellan and Bresciani, (18) in a case report where they restored a deciduous canine using indirect composite resins that included tooth preparation. In the presented case report, no tooth preparation was performed, and an indirect composite resin fragment was also included for the mesial aspect of tooth #24 to improve the esthetic outcome, finally being the most conservative approach possible.

CONCLUSIONS

Indirect composite resin veneer and fragment restorations can be safely used in the anterior dentition when indicated. The bonding procedure must be respected step-by-step to ensure high quality bonding to the tooth substrate and to achieve a long-lasting restoration. Finally, the correct assess of the clinical condition of a non-erupted canine and its restoration must include evaluation of functionality to ensure the success of the restoration.

REFERENCES

1. Spear F., Kokich V., Mathews D. Interdisciplinary management of anterior dental esthetics. *J Am Dent Assoc.* 2006; 137 (2): 160-169.
2. Nahsan F., Mondelli R., Franco E., Naufel F., Ueda J., Schmitt V. et al. Clinical strategies for esthetic excellence in anterior tooth restorations: understanding color and composite resin selection. *J Appl Oral Sci.* 2012; 20 (2): 51-156.
3. Walsh L., Brostek A. Minimum intervention dentistry principles and objectives. *Aust Dent J.* 2013; 58: 3-16.
4. Simonsen R. From prevention to therapy: Minimal intervention with sealants and resin restorative materials. *J Dent.* 2011; 39: S27-S33.
5. Demarco F., Collares K., Coelho-de-Souza F., Correa M., Cenci M., Moraes R. et al. Anterior composite restorations: A systematic review on long-term survival and reasons for failure. *Dent Mater.* 2015; 31 (10): 1214-1224.
6. Douglas R. Color stability of new-generation indirect resins for prosthodontic application. *J Prosthet Dent.* 2000; 83 (2): 166-170.
7. Schulze K., Marshall S., Gansky S., Marshall G. Color stability and hardness in dental composites after accelerated aging. *Dent Mater.* 2003; 19 (7): 612-619.
8. Gresnigt M., Kalk W., Özcan M. Randomized Clinical Trial of Indirect Resin Composite and Ceramic Veneers: Up to 3-year Follow-up. *J Adhes Dent.* 2013; 15 (2): 181-190.
9. Gesnigt M., Cune M. S., Jansen K., van der Made S. A. M., Özcan M. Randomized clinical trial on indirect resin composite and ceramic laminate veneers: Up to 10-year findings. *J Dent.* 2019; 86: 102-109.
10. Honda M. I., Flório F. M., Basting R. T. Effectiveness of Indirect composite resin silanization evaluated by microtensile bond strength test. *Am J Dent.* 2008; 21 (3): 153-158.
11. Francisco S., Cappellette Junior M. Aspects and clinical procedures of eruptive changes of permanent upper canines. *Dental Press J Orthod.* 2012; 17 (2): 132-139.
12. El Haddad E. Treatment of Maxillary Retained Canine With Implants: New Perspectives. *Oral Implantol (Rome).* 2017; 10 (3): 343.
13. Zuiderveld E., Meijer H., Vissink A., Raghoobar G. Immediate placement and provisionalization of an implant after removal of an impacted maxillary canine: two case reports. *Int J Implant Dent.* 2015; 1 (1).
14. Montenegro P. M. A., Hara O. F. Orthodontic traction of retained upper canine with Edgewise appliances: Case report. *Rev Mex Ortod.* 2013; 1 (1): 61-71.
15. Fernandes P. F., Almeida T. C., Sampaio-Fernandes J., Pinto M. G., Guimarães P. A. Coroas totalmente cerâmicas em caninos decíduos: abordagem multidisciplinar. *Rev Odontol UNESP.* 2010; 39 (6): 373-378.

16. Bin-Shuwaish M. Ceramic Veneers for Esthetic Restoration of Retained Primary Teeth: A 4-year Follow-up Case Report. *Oper Dent.* 2017; 42 (2): 133-142.
17. Báez Rosales A., De Nordenflycht Carvacho D., Schlieper Cacciutolo R., Gajardo Guineo M., Gandarillas Fuentes C. Conservative Approach for the Esthetic Management of Multiple Interdental Spaces: A Systematic Approach. *J Esthet Restor Dent.* 2015; 27 (6): 344-354.
18. Benitez Sellan P., Bresciani E. Reshaping a retained deciduous canine with a semidirect composite resin veneer: A clinical report. *J Prosthet Dent.* 2019. Article in Press.



Attribution (BY-NC) - (BY) You must give appropriate credit, provide a link to the license, and indicate if changes were made. You may do so in any reasonable manner, but not in any way that suggest the licensor endorses you or your use. (NC) You may not use the material for commercial purposes.