

## CASE REPORT

DOI: 10.15517/IJDS.2020.41231

Received:  
25-II-2020

Lingual Focal Hyperplastic Lesion in a Pediatric Patient:  
Report of an Unusual Case

Accepted:  
19-III-2020

Published Online:  
26-III-2020

Lesión hiperplásica focal lingual en un paciente pediátrico:  
Informe de un caso inusual

Denisse A. Herrera B. DDS<sup>1</sup>; Joselin Flores V. DDS<sup>1</sup>; Francisco J. Tejada N. DDS, MS<sup>1</sup>;  
Victor Fierro S. DDS<sup>1</sup>; Amaury J. Pozos G. DDS, MS, PhD<sup>1</sup>;  
Arturo Garrocho R. DDS, MS, PhD<sup>1</sup>

1. Pediatric Dentistry Posgraduated Program, Faculty of Dentistry, San Luis Potosí University, San Luis Potosí, S.L.P., México.

Correspondence to: Dr. Arturo Garrocho R. - [agarrocho@hotmail.com](mailto:agarrocho@hotmail.com)

**ABSTRACT:** Focal fibrous hyperplasia (FFH) is an oral mucosal localized non-neoplastic enlargement representing a reaction to chronic local irritations or injuries. The purpose of this report is to describe the management of an asymptomatic fibrotic lesion located in the tongue, in a preschooler boy. A 7-year-6-month old boy attended our clinic for the evaluation of an exophytic pedunculated tumor-like round mass located in the dorsal surface of the tongue. Based on the initial examination and the natural history of the lesion, the presumptive clinical diagnosis determined an irritation FFH. The lesion was surgically excised with a diode laser device, and the postoperative period evolution occurred without any complication. The appropriate treatment of FFH in children initially consists of the removal of local irritant factors. Excellent oral hygiene maintenance and close follow-up care are strongly suggested. Surgical excision is the most frequent modality for persistent lesions. Early diagnosis and proper management of FFH can reduce the risk of future recurrences or complications.

**KEYWORDS:** Focal hyperplasia lesion; Oral cavity; Tongue; Children; Surgical treatment; Laser.

**RESUMEN:** La hiperplasia fibrosa focal (HFF) es un agrandamiento no neoplásico localizado en la mucosa oral que representa una reacción a irritaciones o lesiones locales crónicas. El propósito de este informe es describir el tratamiento de una lesión fibrótica asintomática ubicada en la lengua, en un niño en edad preescolar. Un niño de 7 años y 6 meses de edad asistió a nuestra clínica para la evaluación de una masa redonda exofítica y pedunculada con forma de tumor ubicada en la superficie dorsal de la lengua. Basado en el examen inicial y la historia natural de la lesión, el diagnóstico clínico presuntivo determinó una irritación HFF. La lesión se extirpó quirúrgicamente con un láser de diodo, y la evolución en el período postoperatorio se produjo sin ninguna complicación. El tratamiento apropiado de HFF en niños inicialmente consiste en la eliminación de factores irritantes locales. Se recomienda un excelente mantenimiento de la higiene bucal y una estrecha atención de seguimiento. La escisión quirúrgica es la modalidad más frecuente para lesiones persistentes. El diagnóstico temprano y el manejo adecuado de la HFF pueden reducir el riesgo de futuras recurrencias o complicaciones.

**PALABRAS CLAVE:** Hiperplasia fibrosa focal; Cavidad oral; Lengua; Niños; Tratamiento quirúrgico; Laser.

## INTRODUCTION

Pediatric oral mucosa and soft tissues are constantly exposed to the influence of multiple predisposing low-intensity internal and external injuries, which may produce diverse reactive developmental anomalies, including chronic infectious/inflammatory processes, physical or chemical irritations, and neoplastic tumor-like conditions (1); common examples of this type of stimuli are cheek biting, trapped food, impacted biofilm/debris, sharp edges of broken or carious teeth, and overhanging dental restorations or orthodontic appliances (2). One of the consequences of such irritating factors is the occurrence of localized proliferative hyperplastic progressive lesions (3,4).

Focal fibrous hyperplasia (FFH) (traumatic fibroma, irritation fibroma, fibrous epulis, fibromatosis fibroma) is considered the most common soft-tissue benign neoplastic lesion in the oral cavity (5,6). Although this condition occurs mainly in patients older than 30 years old, some cases in children have

been reported in the literature (7). In young female adolescents, FFH can be further aggravated by systemic factors, particularly alterations in serum levels of certain endocrine hormones (3,5,8). These lesions have been also associated with the erupting process of both primary and permanent teeth and to the ingestion of some drugs such as phenytoin, cyclosporine, and calcium channel blockers (3).

FFH constitutes around 20% of the oral reactive hyperplastic lesions and females are affected almost twice as frequently as males (1,6). It is clinically manifested as a pedunculated or sessile firm mass, with a few centimeters in diameter, smooth-surfaced (surface can be hyperkeratotic or ulcerated), yellowish-white or mucosal colored (pink to red), and more frequently present in the gingiva and mucosa (along the line of occlusion) (9). Other less common intraoral sites are the tongue, lower lip, hard palate, and mouth floor (4,9). Histologically, this entity is characterized by an unencapsulated solid, nodular mass of dense and sometimes hyalinized fibrous

connective tissue; it is composed of interlacing collagen fiber bundles, within which there are fibroblasts and some small blood vessels (2). FFH rarely causes erosions in the underlying bone tissue or separation of adjacent teeth (6). Other similar types of localized reactive anomalies in the oral cavity are the vascular or hemorrhagic lesion, pyogenic granuloma, peripheral giant cell granuloma, and peripheral ossifying fibroma (6,7,10).

The removal of the etiological factor is mandatory. In several cases, the FFH disappears after this measure. When the lesion persists, the first treatment option for FFH is surgical excision and recurrences are very uncommon (11). Diverse surgical options, including the conventional or electric scalpel and the minimally invasive surgical laser, have been suggested; electrosurgery and cryotherapy are other available treatment options (12). The aim of this report is to describe the clinical presentation, provided treatment, and follow-up of a focal massive fibrous lesion in the tongue, an unusual location, in a 7-year-6-month old boy.

## CASE REPORT

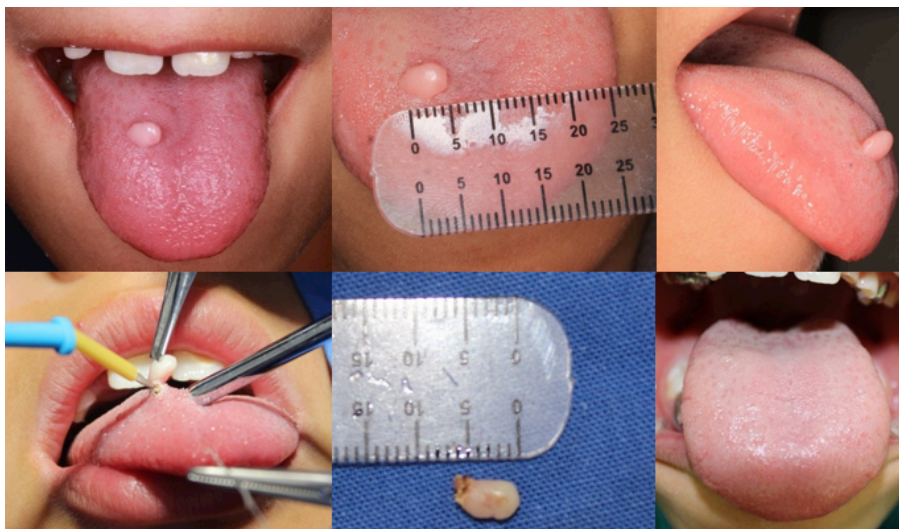
A 7-year-6-month old boy was referred from a private general dentist to the Pediatric Dentistry Postgraduate Program clinic (Faculty of Dentistry; University of San Luis Potosí, México) for the evaluation of an exophytic tumor-like round mass located in the dorsal surface of the tongue, just right to the midline. Medical history revealed a healthy child. The parents discovered the lesion around six months ago with a slow increase in size. No antecedents of dentofacial trauma were mentioned. The pedunculated and firm-consistency lesion was about 6 mm in size, white/pink in color, without any report of pain or feeding/swallowing or speech interference; however, the child frequently scrubbed the lesion against the incisal edges of

the upper anterior teeth. The lingual frenulum was normal and oral hygiene was considered as poor. Based on the initial examination and the natural history of the lesion, the presumptive clinical diagnosis determined an irritation FFH. Other suspected lesion considered during the process of differential diagnosis was the lingual papilloma, although this condition occurs more frequently in older patients (>30 years).

The surgical treatment plan was thoroughly discussed and approved by the patient and his parents by means of a signed informed consent form; in this same document, the parents also authorized the publication of the present clinical case, respecting the confidentiality issues regarding the patient's personal information. The patient exhibited an excellent cooperation level during the first dental appointments, so it was decided to perform the surgical excision of the lesion under local anesthesia (2% lidocaine with 1:100,000 epinephrine). The perioral area was fully disinfected. Then, the surgical procedure was carried out through a high-frequency diode laser desiccator (Aaron 900). The laser power was set at 3200 mW, in continuous mode at an average energy of 300 J. The mean radiation dose was 2.0 W/cm<sup>2</sup>. Laser energy was delivered avoiding the deep penetration up to the tongue muscle fibers and removing the lesion at the base. Finally, resorbable sutures were appropriately placed. Oral hygienic measures (careful dental cleaning with a soft brush after each meal and use of an alcohol-free oral mouthwash three times a day) to be performed with caution were strongly recommended; only analgesics (paracetamol 15 mg/kg, every 6 hours) were prescribed for the first two days. The immediate postoperative period proceeded without complications such as significant bleeding, swelling, pain, or discomfort. One week later, the surgical area had healed well, and the patient did not report any difficulty in eating.

The lesion specimen was preserved in 10% formalin and submitted to the Oral Pathology Department for a histopathological examination. The results of this analysis confirmed the diagnosis of FFH. The patient was further examined three

months after the surgery, without complication and without recurrence of the lesion (Figure 1). Future clinical control appointments were programmed every 4 months for monitoring any possible lesion recurrence.



**Figure 1.** Descriptive views showing the sequential process of the lesion: clinical detection, surgical excision, and 6-month follow-up.

## DISCUSSION

Nowadays, there is a notorious scarcity of epidemiological studies in children and young adolescents about oral reactive hyperplastic lesions because of their low incidence in this patient population. However, pediatric dentistry practitioners must be constantly aware of the possible onset of oral mucosal growths or lesions -even at very early ages-, to perform a correct differential diagnosis and participate in the institution of an adequate treatment plan (13). It is suggested that these tasks be performed by a multidisciplinary health team including, in addition to pediatric dentists, maxillofacial surgeons, periodontologists, and oral pathology/medicine specialists (14).

An inadequate systematic oral mucosa examination (normal size, shape, color, and texture)

can lead that important lesions are overlooked and, as a consequence, to the indication of equivocating treatments (13,15). In general, oral fibrous reactive lesions show several variations in terms of age distribution, gender, race, location, and clinical behavior in different populations. Their visual appearance can be similar to other neoplastic conditions. In this same regard, it has been reported that up to 77% of lesions in the oral cavity are reactive in nature (4). Thus, the diagnostic process may be challenging for the practitioner. The differential diagnosis of FFH should consider other non-neoplastic lesions of the oral cavity in children, particularly the giant cell fibroma; this entity occurs most commonly on the tongue and gingiva, without gender predilection (9). Other potentially comparable anomalies are neurofibroma, peripheral giant cell granuloma, mucocele, and salivary gland tumors (11). On

the other hand, the possibility that the lesion is a true papilloma or a small verrucous carcinoma is extremely low (6).

According to the American Association of Pediatric Dentistry (AAPD) (16), any abnormal tissue mass found in the oral mucosa of children and young adolescents, including the FFH, must be submitted for histopathological examination in order to establish a definitive diagnosis, the possible clinical management, and prognosis. The biopsy is indicated when the lesion persists for more than two weeks, despite the elimination of the suspected causative factor or after the empirical pharmacological treatment. In this respect, many oral biopsies in children are within the scope of the pediatric dentistry practice; if the procedure is indicated, it is strongly recommended to follow the steps mentioned by the AAPD for optimal outcomes (16).

## CONCLUSIONS

The present report emphasizes that early diagnosis and proper management of FFH in children can reduce the risk of future recurrences or complications to the stomatognathic system. The appropriate management of FFH in children initially consists of the removal of local irritant factors; excellent oral hygiene maintenance and close follow-up care are also crucial. Surgical laser excision is the most frequent modality for persistent lesions.

## CONFLICT OF INTEREST

No conflict of interest was declared by the authors.

## FINANCIAL DISCLOSURE

The authors declared that this study has received no financial support.

## REFERENCES

1. Kadeh H., Saravani S., Tajik M. Reactive hyperplastic lesions of the oral cavity. *Iran J Otorhinolaryngol.* 2015; 27 (79): 137-44.
2. Manchanda A. S., Narang R. S., Singh B., Mahajan K. Retrospective analysis of focal fibrous hyperplasia. *Indian J Comprehensive Dent Care.* 2015; 5 (2): 598-602.
3. Da Silva F. C., Piazzeta C. M., Torres-Pereira C. C., Schussel J. L., Amenábar J. M. Gingival proliferative lesions in children and adolescents in Brazil: A 15-year-period cross-sectional study. *J Indian Soc Periodontol.* 2016; 20 (1): 63-6.
4. Soyele O. O., Ladeji A. M., Adebisi K. E., Adesina O. M., Aborisade A. O., Olatunji A. S., et al. Pattern of distribution of reactive localized hyperplasia of the oral cavity in patients at a tertiary health institution in Nigeria. *Afr Health Sci.* 2019; 19 (1): 1687-94.
5. Kashyap B., Reddy S., Nalini P. Reactive lesions of oral cavity: A survey of 100 cases in Eluru, West Godavary district. *Contemp Clin Dent.* 2012; 3 (3): 294-7.
6. Kale T. A. Focal fibrous hyperplasia. A reactive lesion. *Int J Dent Clinics.* 2013; 5 (3): 29-30.
7. Buchner A., Shnaiderman A., Vered M. Pediatric localized gingival lesions: A retrospective study from Israel. *Pediatr Dent.* 2010; 32 (7): 486-92.
8. Sangle V. A., Pooja V. K., Holani A., Shah N., Chaudhary M., Khanapure S. Reactive hyperplastic lesions of the oral cavity: A retrospective survey study and literature review. *Indian J Dent Res.* 2018; 29 (1): 61-6.
9. Santana-Santos T., Saquete-Martins-Filho P. R., Rabello-Piva M., De Souza-Andrade E. S. Focal fibrous hyperplasia: A review of 193 cases. *J. Oral Maxillofac Pathol.* 2014; 18 (Suppl): S86-9.

10. Seyedmajidi M., Hamzehpoor M., Bagherimoghaddam S. Localized lesions of oral cavity: A clinicopathological study of 107 cases. *Res J Med Sci.* 2011; 52 (1): 67-72.
11. Vergotine R. J. A giant cell fibroma and focal fibrous hyperplasia in a young child: A case report. *Case Rep Dent.* 2012; 2012: 370242.
12. Oliveira-Andriola F., Santolim-Zanetti L. M., De Marco R. G., Kunz C., Machado-Vaz C. S., Miranda-Pagnoncelli R. Diode laser in the surgical treatment of inflammatory fibrous hyperplasia: Case report and literature review. *Rev Odonto Ciencia (J Dent Sci).* 2017; 32 (3): 154-9.
13. Rioboo-Crespo M. R., Planells-Del Pozo P., Rioboo-García R. Epidemiology of the most common oral mucosal diseases in children. *Med Oral Patol Oral Cir Bucal.* 2005; 10 (5): 376-87.
14. Reddy V., Saxena S., Saxena S., Reddy M. Reactive hyperplastic lesions of the oral cavity: A ten year observational study on North Indian Population. *J Clin Exp Dent.* 2012; 4 (3): e136-40.
15. Yáñez M., Escobar E., Oviedo C., Stillfried A., Pennacchiotti G. Prevalence of oral mucosal lesions in children. *Int J Odontostomat.* 2016; 10 (3): 463-8.
16. American Academy of Pediatric Dentistry. Management considerations for pediatric oral surgery and oral pathology. Reference Manual 2018-19. *Pediatr Dent.* 2017; 39 (6): 361-70.



Attribution (BY-NC) - (BY) You must give appropriate credit, provide a link to the license, and indicate if changes were made. You may do so in any reasonable manner, but not in any way that suggest the licensor endorses you or your use. (NC) You may not use the material for commercial purposes.