

## NEW PERSPECTIVE ARTICLE

DOI: 10.15517/IJDS.2022.50505

Received:  
10-I-2022

Changes in Somatosensory Perception Induced by Trigeminal Injury After Maxillofacial Surgical Procedures

Accepted:  
11-II-2022

Published Online:  
22-III-2022

Cambios en la percepción somatosensorial inducidos por lesiones trigeminales causadas por procedimientos quirúrgicos maxilofaciales

Mariana Irais Luna Velazquez DDS student<sup>1</sup>; Claudia Daniela Montes Ángeles DDS, MSc<sup>2</sup>; Isaac Obed Pérez-Martínez DDS, MSc, PhD<sup>3</sup>

1. Sección de Neurobiología de las Sensaciones y Movimientos Orales. Laboratorio de Investigación odontológica, Clínica Universitaria de Salud Integral Almaraz. Facultad de Estudios Superiores Iztacala, Universidad Nacional Autónoma de México, Tlalnepantla, Estado de México, México.  
<https://orcid.org/0000-0003-3713-0805>

2. Sección de Neurobiología de las Sensaciones y Movimientos Orales. Laboratorio de Investigación odontológica, Clínica Universitaria de Salud Integral Almaraz. Facultad de Estudios Superiores Iztacala. Programa de Maestría y Doctorado en Ciencias Médicas Odontológicas y de la Salud, Universidad Nacional Autónoma de México, Tlalnepantla, Estado de México, México.  
<https://orcid.org/0000-0002-3076-9481>

3. Sección de Neurobiología de las Sensaciones y Movimientos Orales. Laboratorio de Investigación odontológica, Clínica Universitaria de Salud Integral Almaraz. Facultad de Estudios Superiores Iztacala, Universidad Nacional Autónoma de México, Tlalnepantla, Estado de México, México.  
<https://orcid.org/0000-0003-1063-2063>

Correspondence to: Dr. Isaac Obed Pérez-Martínez - [isaac.perez@unam.mx](mailto:isaac.perez@unam.mx)

**ABSTRACT:** Evidence has been reported that shows that somatosensory perception can be altered by a trigeminal injury resulting from maxillofacial surgical procedures. However, the surgical procedures that most frequently cause trigeminal lesions and the risk factors are unknown. In the same way, there is little information on what has been determined in preclinical models of trigeminal injury. This article integrates relevant information on trigeminal injury from both clinical findings and primary basic science studies. This review shows that the age and complexity of surgical procedures are essential to induce orofacial sensory alterations.

**KEYWORDS:** Neuropathic pain; Trigeminal injury; Orofacial surgery; Somatosensory perception; Sensory alterations; Trigeminal nerve.

**RESUMEN:** Se han reportado evidencias que demuestran que la percepción somatosensorial puede ser alterada por la lesión trigeminal producto de procedimientos quirúrgicos maxilofaciales. Sin embargo, se desconoce cuáles son los procedimientos quirúrgicos que más frecuentemente producen lesiones trigeminales, y los factores de riesgo. De la misma forma hay poca información sobre lo que se ha determinado en modelos preclínicos de lesión trigeminal. El objetivo de este artículo es integrar información relevante sobre la lesión trigeminal desde los hallazgos clínicos como los principales estudios de ciencia básica. Esta revisión demuestra que la edad y el tipo de procedimiento son fundamentales para inducir alteraciones sensoriales orofaciales, así como los procesos neurobiológicos que subyacen a estos padecimientos.

**PALABRAS CLAVE:** Dolor neuropático; Lesión trigeminal; Cirugía orofacial; Percepción somatosensorial; Alteraciones sensoriales; Nervio trigémino.

## INTRODUCTION

Quality control in orofacial surgical procedures is critical due to its impact on both the tissue extension and occupation (1); trigeminal injuries (TI) can have an irreversible impact on orofacial perception. Preclinical research has shown these have sensory, affective, and cognitive effects (2,3). At clinical level, it has been observed that TI have an additional psychosocial impact (4). Since this work shows that oral sensations are disturbed, this evidence indicates a decrease in the patients' quality of life who undergo TI (5). Despite all the existing evidence, there is no agreement regarding the outcome of TI, and their variability and neurobiological basis are not well understood. This review aims to present evidence of TI caused by surgical procedures and their effects on somesthetic perception in patients and discuss their possible neural basis with a translational perspective.

Somesthetic impairment caused by maxillofacial surgical procedures. Clinical evidence has shown that orofacial surgical procedures can induce alterations in orofacial somesthetic perception (Table 1). These occur most frequently in mental and lingual region (6). For example, a bilateral divided sagittal osteotomy had as a side effect a neurosensory injury. 127 patients were

studied and grouped by age (<24,24-25 and >35 years old), who received a short mandibular advancement (<or=7mm), large advancement (>7mm), with and without genioplasty. Results showed a smaller sensory loss in patients over 35 years old who received a large mandibular advancement and genioplasty. This study concluded that age and a larger advancement and genioplasty increase the risk of a TI (7). In a different study, hypoesthesia caused by bilateral divided sagittal osteotomy was assessed. That was made by measuring the evoked somatosensory potentials of the trigeminal nerve of 10 patients with prognathism during surgery (4 times) and in 5 postoperative sessions. Hypoesthesia was evaluated through P1 and N2 waves; results showed that the latency during medial periosteum dissection increased after fixation, with fast recovery after 2 to 4 weeks. Hypoesthesia is related to a direct injury to the inferior alveolar nerve (8). In another study, the authors proposed to evaluate the long-term effects on somatosensory perception after bilateral divided sagittal osteotomy. The study included 38 patients with an asymmetry greater than 4mm, preoperative and postoperative (6 months and 3 years). An improvement was observed in the midline of 56% of the patients. 58% of the patients showed a discrepancy of more than 3mm, 3 years after the surgery, and an improve-

ment in the dental midline in 80%. 44% of the patients reported normal sensitivity on the lower lip and mental region, but a difference was observed in the incidence of neurosensory impairment between both sides of the osteotomy (9). Sensory alterations after a divided sagittal osteotomy alone (n=84) or with genioplasty (n=37) occurred in 37% of the manipulated sides. Incidences were 36/101 for mandibular advancement and 12/30 for a mandibular setback. This study concluded that there are no significant differences between mandibular advancement or setback combined or not with genioplasty to show somesthetic impairment (10). These sensory signs have been associated to inferior alveolar nerve injury, produced by a divided sagittal osteotomy and distraction osteogenesis. 130 cases of inferior alveolar nerve injury were studied (70 bilateral divided sagittal osteotomies and 60 distraction osteogenesis). Results showed 23 cases of perception disorders, of which 14 were subjected to a bilateral divided sagittal osteotomy and 9 distraction osteogenesis. Furthermore, 107 inferior alveolar nerves did not show somesthetic impairment, of which 56 corresponded to bilateral divided sagittal osteotomy and 51 to distraction osteogenesis. It was also shown that there were no significant differences in inferior alveolar nerve injury between both surgical techniques (11). The maxillary nerve can also be injured after a Le Fort I bone fracture, with a postoperative evaluation in 12 men and 13 women. Skin, oral mucosa, and teeth sensitivity were assessed. An increase in the mechanical threshold of gums and palate was observed, and a higher thermal sensitivity in the infraorbital region 12 months after surgery. Sensory change was determined for the eyes, upper lip, gums, palate, and teeth (12). Other study assessed sensory recovery after orthognathic surgery. 47 patients (26 men, 21 women) were evaluated, 1, 3, and 6 months after surgery, using a visual analog scale. It was found that tactile sensory alterations occurred on the mental region in 55.7% of the cases and on the lips in 27.3%, similar to paresthesia, which decreased

over time. This study concluded that somesthetic impairment is an inevitable complication but can be solved spontaneously (13). Another study used self-monitoring of sensory impairment in patients, and it was compared with a quantitative sensory assessment instrument. These evaluations are important to obtain better quality control in orthognathic surgery and decrease risk factors. In 2 groups of patients programmed for bi-maxillary orthognathic surgery (cases and controls study), sensory tests were applied in 6 trigeminal sites and 1 extra- trigeminal site; patients' sensitivity to toothbrush bristles, prick, pressure, among others, was evaluated. 8% of the patients showed postoperative intraoral sensory disorders, and 46% showed extraoral sensory disorders. One and a half years after surgery, many patients reported sensory disturbances, such as mechanical hypersensitivity, compared to control groups or preoperative conditions. Patients could report their sensory conditions in addition to clinical assessment using sensory measurement instruments (1). Furthermore, the infraorbital nerve was assessed after zygomatic bone fractures. In a study with 25 patients, 15 displaced fractures from the zygomatic complex and 10 with minimal displacement. Of these cases, 7 were left with no treatment, 8 were treated with bone reduction but no fixation, and 10 cases with fixation, and somatosensory function was improved with electrical stimulation. This occurred 6 months after the TI produced on the group that received a bone fixation. Thus, bone fixation might allow the recovery of infraorbital nerve injury after bone fracture (14). This is corroborated by displacement of the zygomatic-maxillary fracture, which can induce peri-orbital hematoma, edema, diplopia, and mouth opening limitation, which is solved during the postoperative period. However, in 44% of displaced fractures, somatosensory impairment persisted until the end of follow-up (after 6 months), unlike non-displaced fractures, in which incidence is much lower (15). In a study that analyzed the somatosensory function of the lower lip and mental region after

divided sagittal osteotomy, 22 patients with skeletal class III were recruited. A quantitative sensory test was applied before the surgery, and 1 week, 1, 3, and 6 months after, cold, heat, and pressure pain threshold were measured on the lower lip and mental region. Results showed a decrease in sensitivity for all tests, except for pressure pain. After 3 months, threshold values returned to the baseline; thus, somatosensory function might fully

recover after 6 months (16). It has been found an increase of cold and heat threshold after divided sagittal osteotomy (17). Other studies showed that the risk of hypoesthesia after a bilateral osteotomy increases with age (5%) (18). For intraoral vertical osteotomy, the development of hypoesthesia in the lower lip has been observed. It has also been suggested that bone displacement can delay the recovery of lower lip hypoesthesia (19).

**Table 1.** Sensory changes associated with orofacial surgical procedures.

Surgical procedure	Sensory affection	Reference
Oral surgery (Inferior Alveolar Nerve)		
Third molar extraction	Tongue numbness. Increase in cold sensitivity and cold and heat pain.	(Yan et al., 2020)
Coronectomy	Lower lip numbness	
Bilateral divided sagittal osteotomy	An increased tactile threshold in the lower lip, two-point discrimination. Reduced pulp threshold.	(Thygesen et al., 2008)
Mandibular nerve lateralization during implant placement	Anesthesia (81 sites). Hypoesthesia (9 sites). Burning sensation (9 sites). Pain (8 sites). Tickling (1 site).	(Hashemi, 2010)
Third molar extraction	A reduced electrical detection threshold.	(Barron et al., 2004)
Maxillofacial Surgery		
Bilateral divided sagittal osteotomy/Le Fort I/Genioplasty	Dysesthesia. Hypoesthesia. Paresthesia.	(Y. K. Kim, Kim, & Kim, 2011)
Le Fort I	Increase of tactile threshold in gum and palate. Increase of thermal sensitivity in infraorbital region. Changes of eyes, upper lip, gum, palate, and teeth sensitivity. Increase of electrical stimulation pulp threshold.	(Thygesen, Bardow, Norholt, Jensen, & Svensson, 2009)
Bimaxillary orthognathic surgery	Increased sensitivity to brush stimulation. Decrease of two-points discrimination threshold (mental region). Hypersensitivity to brush, prick, two-point discrimination, and pain.	(Baad-Hansen, Arima, Arendt-Nielsen, Neumann-Jensen, & Svensson, 2010)
Sagittal split ramus osteotomy	Decrease of sensitivity of lower lip and mental region: cold. heat. cold-pain. heat-pain. detection of mechanical stimuli. mechanical-pain.	(He et al., 2021)

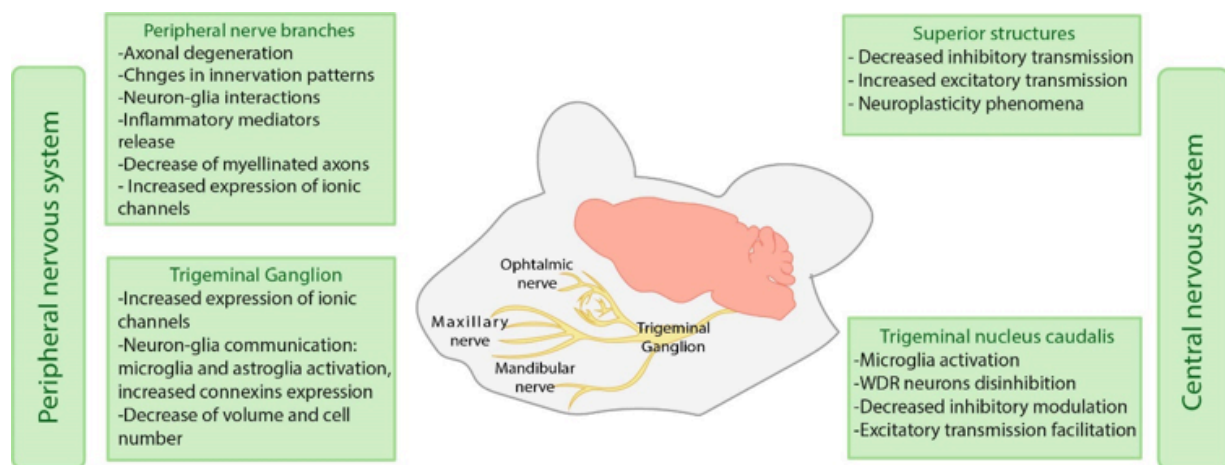
Surgical procedure	Sensory affection	Reference
Zygomaticomaxillary fracture fixation	Hyperesthesia. Anesthesia. Paresthesia. In the infraorbital and paranasal region, for displaced fractures (88.2%).	(Mueller, ZeiB, Mtsariashvili, Thorwarth, & Schultze-Mosgau, 2012)
Bilateral divided sagittal osteotomy	Lower lip/mental region sensitivity: Normal 44%. Slightly reduced (34%). Markedly reduced (10.5%). Hypersensitivity (7.9%). Complete loss (3.6%).	(Hågensli, Stenvik, & Espeland, 2014)
Zygomatic fracture fixation	Electrical stimuli: Hypersensitivity (8,3%). Hyposensitivity (50%) Fine mechanical stimuli hypoesthesia (55%). Thermal detection threshold: Hypersensitivity (10%). Hyposensitivity (40%).	(Benoliel, Birenboim, Regev, & Eliav, 2005)
Vertical intraoral ramus osteotomy with and without Le Fort I	Lip hypoesthesia.	(Ueki et al., 2009)
Bilateral divided sagittal osteotomy	Trigeminal hypoesthesia Increase in the latency of evoked somatosensory trigeminal potentials	(Nakagawa, Ueki, Takatsuka, Takazakura, & Yamamoto, 2001)
Divided sagittal osteotomy	Anesthesia (3 nerves). Hypoesthesia/paresthesia. (11 nerves).	(Baas, de Lange, & Horsthuis, 2010)
Distraction osteogenesis	Anesthesia (2 nerves).	
Bilateral sagittal ramus osteotomy	For the mental region, an increase of: Cold threshold. Heat threshold.	(Kabasawa et al., 2006)
Bilateral divided sagittal osteotomy	Increase in sensory thresholds (over 35 years old, with genioplasty) Tactile sensory loss (advancements of 7 mm or more, patients over 35 years old).	(Van Sickels, Hatch, Dolce, Bays, & Rugh, 2002)
Glossectomy	No sensory alterations were observed in sensory tests after tongue reduction.	(Matsumoto, Morita, Jinno, & Omura, 2014)
Bilateral divided sagittal osteotomy	Hypoesthesia.	(Politis, Sun, Lambrichts, & Agbaje, 2013)

For divided sagittal osteotomy, an increase in the tactile threshold for the lower lip and a decrease of self-perception of mouth opening have been found. These changes depend on the intraoperative risk factors and individual preoperative sensation (20). This result could lead to prediction and prevention of the development of disturbances in somesthetic perception after osteotomies. In soft tissue surgical procedures, it has been less likely to find somatosensory changes, as reported for macroglossia surgical reduction (21). Some procedures have been proposed to reduce the risk of trigeminal injuries, such as the coronectomy (22). Practicing coronectomies for dental extractions have been shown to decrease the sensory changes observed in conventional extractions, such as increased thermal and pain sensitivity. Therefore, coronectomy might imply a lower risk of TI than a conventional total extraction (23). One of the main problems in assessing the somesthetic changes associated with TI caused by surgical procedures is the absence of an agreement for it. In a prospective study of up to 20 years, postoperative sensory changes were measured following 75 mandibular surgical procedures. Most of the procedures were osteotomies and bone fractures, compared to third molar extrac-

tions. This study used the light touch test with Semmes-Weinstein filaments, accompanied by a visual analog scale, to evaluate sensitivity (24). Another efficient strategy to prevent sensory impairment caused by sagittal mandibular osteotomies is steroids in patients over 40 years old, whose incidence increases the risk of developing an orofacial somesthetic perception disturbance (25). Dipyron and preoperative dexamethasone treatment can prevent the development of somatosensory alterations induced by third molar surgery (26).

These effects on somatosensory perception are more significant if the surgical procedures are directly performed in nervous branches (27).

Neurobiological Aspects of trigeminal injury. Additionally to their clinical study, orofacial nervous injuries have been evaluated experimentally, mainly in murine models. The scientific assessment of these injuries has allowed to study them in a controlled way and, despite these models do not completely reflect the clinical conditions of trigeminal injuries, they have been helpful to assess these phenomena in a greater depth, from a molecular to a behavioral approach (Figure 1).



**Figure 1.** Mechanisms involved in orofacial chronic neuropathic pain in both peripheral and central nervous systems in preclinical models.

The studies mentioned above have been made at peripheral level, evaluating the trigeminal branches and trigeminal ganglion; and at the central level, studying the different brain structures involved in orofacial areas somatosensory processing. For peripheral structures' assessment, the changes after mental nerve injury include axonal degeneration and alterations in the lower lip's innervating patterns, involving sensory and autonomous fibers. Autonomous fibers show changes in their length and the innervation site (28). These changes occur during the first days after the injury and are maintained over several weeks, suggesting long-term effects. These effects are associated with hypersensitivity in rodents, observed through an increased grooming behavior.

Nerve degeneration signs have been observed in infraorbital nerve compression models, showing a deficient repair process compared to what can occur in a facial nerve injury. That highlights the importance of the consequences of nerve injuries in somatosensory functions (29). It has been proposed that sensory impairment extends beyond the injured nerve region, as observed after a mental nerve constriction and transection. The rodents showed hypersensitivity signs on the whisker pad, a region innervated by the maxillary branch of the trigeminal nerve (28). Hypersensitivity signs in a region beyond the territory of an injured nerve indicates that its changes might affect a more significant proportion of the trigeminal system, not only locally.

The effects of TI on the trigeminal ganglion have also been assessed, and there have been observed both molecular and cellular alterations. After a mandibular branch injury, axonal damage is seen as a high expression of the transcription factor-dependent ATF3 (ATF3). However, not only the neurons that showed axonal damage participate in the sensory alterations induced by TI, since the neurons in the trigeminal ganglion that did not express ATF3 showed an increased expression of

the transient receptor potential vanilloid 1 (TRPV1) channels, involved in the processing of noxious stimuli (30, 31). Different evaluations suggest that these are long-term changes because around 180 days after trigeminal injury, the volume and number of neurons in the trigeminal ganglion decrease and do not recover over time (32). Regarding neural activity in the trigeminal ganglion, inferior alveolar transection can produce a state of hyperexcitability of nerve fibers. This phenomenon is associated with hypersensitivity signs (33).

The immune response role can also affect the development of sensory impairment after a nerve injury, and a cross-communication might explain it between nervous and immune system cells. Thus, nerve damage causes the activation of immune cells and the release of inflammation mediators, stimulating nerve cells. This stimulation can origin the peripheral sensitization phenomenon, facilitating chronic neuropathic pain development (34). Immune system participation does not only occur in the nerve endings, where an injury is made, but also in different sites, such as the trigeminal ganglion, where an increase of inflammatory mediators has been observed, for example, interleukin 1 $\beta$  (IL-1 $\beta$ ) after mental nerve transection (28).

Although glial cells do not directly participate in nervous impulses transmission, they could be essential in establishing and maintaining chronic neuropathic pain; the activation of microglial cells and the increase of inflammatory mediators in cells such as astrocytes since the early stages of the injury (35) and a possible neuron-glia communication in the trigeminal ganglion. It has been suggested that this increase in the cross-communication might be due to an increase in connexins expression in glial cells, which correlates with the presence of spontaneous pain (36), in addition to the satellite glial cells, found near neuronal somas in the trigeminal ganglion. This process can increase paracrine signaling and cell

sensitization mediated by the activation of purinergic receptors. Such activation might increase the intracellular calcium levels, facilitating an increase in neural activity (37).

One of the most studied structures in the central nervous system is the trigeminal nucleus caudalis since it is the site where the first synapse occurs in the trigeminal sensory pathway. This nucleus has been shown to suffer changes in both humans and rodents in the context of trigeminal injury and chronic neuropathic orofacial pain. It has been found that wide dynamic range neurons (WDR), which process somatosensory information, have increased evoked and spontaneous responses after lesioning the infraorbital nerve. One possible explanation for this event can be attributed, at least in part, to the decrease in inhibitory transmission mediated by gamma-aminobutyric acid (GABA) (38). Moreover, it has been observed microglia and astroglia activation since the first days after a trigeminal injury (39); an increase in connexin 36 (CX36) expression, favoring neuron-glia communication (40); as well as the increase in functional connectivity between rostroventral medulla (RVM) and the trigeminal nucleus caudalis (41). These data suggest a possible impairment in modulatory systems that reduce pain perception. It has been recently reported that orofacial pain induced by mental nerve injury can facilitate nerve transmission in the trigeminal nucleus caudalis. Such effect is, in part, mediated by TRPV1 receptors (42). Additionally, different supraspinal structures have been associated with the development of sensory, affective, and cognitive alterations due to nerve injuries. Nonetheless, such alterations are beyond the purpose of this review, and they would be worthwhile to be addressed in an additional review.

As has been already mentioned, ectopic innervation of peripheral fibers, crossed excitation of injured and uninjured nerves, expression of cell-membrane and signaling molecules, and neuron-glia interactions can produce changes in

the electrical properties of nervous fibers, altering the balance between excitatory and inhibitory transmission. The augmented excitatory transmission and the diminished inhibitory transmission can be manifested in the characteristic symptoms of chronic pain and the sensory alterations that can co-occur (43). These alterations might be hypersensitivity phenomena, such as allodynia and hyperalgesia (44), spontaneous pain episodes (45), or other sensory alterations reported due to trigeminal injuries, such as paresthesia, dysesthesia, anesthesia, among others (46).

## CONCLUSION

Surgical procedures performed in adults have the highest risk of generating perception impairment, combined with the extension and tissue invasion. The clinical and experimental basis shows that the main somatosensory alterations after trigeminal injury are the development of chronic pain, hypersensitivity, and hypoesthesia. There are plenty of pathophysiologic mechanisms underlying these alterations, and therefore, a prevention strategy is necessary for every surgical intervention.

## AUTHOR CONTRIBUTION STATEMENT

All the authors contributed equally in the conceptualization, design, writing, preparing and editing the draft of this article.

## REFERENCES

1. Baad-Hansen, L., Arima, T., Arendt-Nielsen, L., Neumann-Jensen, B., & Svensson, P. (2010). Quantitative sensory tests before and 1(1/2) years after orthognathic surgery: a cross-sectional study. *J Oral Rehabil*, 37(5), 313-321. doi:10.1111/j.1365-2842.2010.02059.x
2. Montes Angeles, C. D., Andrade Gonzalez, R. D., Hernandez, E. P., García Hernández, A. L., & Pérez Martínez, I. O. (2020). Sensory, Affective, and Cognitive Effects of Trigeminal Injury



- in Mice. *J Oral Maxillofac Surg*, 78 (12), 2169-2181. doi:10.1016/j.joms.2020.07.212
3. Pérez-Martínez, I. O., Acevedo-Roque, C. R., Montes-Angeles, C. D., Martínez, M., & Miranda, F. (2019). Mental nerve injury induces novelty seeking behaviour leading to increasing ethanol intake in Wistar rats. *Arch Oral Biol*, 99, 66-72. doi:10.1016/j.archoral-bio.2019.01.004
  4. Pillai, R. S., Pigg, M., List, T., Karlsson, P., Mladenović, Ž., Vase, L., Baad-Hansen, L. (2020). Assessment of Somatosensory and Psychosocial Function of Patients With Trigeminal Nerve Damage. *Clin J Pain*, 36 (5), 321-335. doi:10.1097/ajp.0000000000000806
  5. Van der Cruyssen, F., Peeters, F., Gill, T., De Laet, A., Jacobs, R., Politis, C., & Renton, T. (2020). Signs and symptoms, quality of life and psychosocial data in 1331 post-traumatic trigeminal neuropathy patients seen in two tertiary referral centres in two countries. *J Oral Rehabil*, 47 (10), 1212-1221. doi:10.1111/joor.13058
  6. Said-Yekta, S., Smeets, R., Esteves-Oliveira, M., Stein, J. M., Riediger, D., & Lampert, F. (2012). Verification of nerve integrity after surgical intervention using quantitative sensory testing. *J Oral Maxillofac Surg*, 70 (2), 263-271. doi:10.1016/j.joms.2011.03.065
  7. Van Sickels, J. E., Hatch, J. P., Dolce, C., Bays, R. A., & Rugh, J. D. (2002). Effects of age, amount of advancement, and genioplasty on neurosensory disturbance after a bilateral sagittal split osteotomy. *J Oral Maxillofac Surg*, 60 (9), 1012-1017. doi:10.1053/joms.2002.34411
  8. Nakagawa, K., Ueki, K., Takatsuka, S., Takazakura, D., & Yamamoto, E. (2001). Somatosensory-evoked potential to evaluate the trigeminal nerve after sagittal split osteotomy. *Oral Surg Oral Med Oral Pathol Oral Radiol Endod*, 91 (2), 146-152. doi:10.1067/moe.2001.112331
  9. Hågensli, N., Stenvik, A., & Espeland, L. (2014). Asymmetric mandibular prognathism: outcome, stability and patient satisfaction after BSSO surgery. A retrospective study. *J Craniomaxillofac Surg*, 42 (8), 1735-1741. doi:10.1016/j.jcms.2014.06.008
  10. Al-Bishri, A., Dahlberg, G., Barghash, Z., Rosenquist, J., & Sunzel, B. (2004). Incidence of neurosensory disturbance after sagittal split osteotomy alone or combined with genioplasty. *Br J Oral Maxillofac Surg*, 42 (2), 105-111. doi:10.1016/j.bjoms.2003.12.002
  11. Baas, E. M., de Lange, J., & Horsthuis, R. B. (2010). Evaluation of alveolar nerve function after surgical lengthening of the mandible by a bilateral sagittal split osteotomy or distraction osteogenesis. *Int J Oral Maxillofac Surg*, 39 (6), 529-533. doi:10.1016/j.ijom.2010.03.003
  12. Thygesen, T. H., Bardow, A., Norholt, S. E., Jensen, J., & Svensson, P. (2009). Surgical risk factors and maxillary nerve function after Le Fort I osteotomy. *J Oral Maxillofac Surg*, 67 (3), 528-536. doi:10.1016/j.joms.2008.07.004
  13. Kim, Y. K., Kim, S. G., & Kim, J. H. (2011). Altered sensation after orthognathic surgery. *J Oral Maxillofac Surg*, 69(3), 893-898. doi:10.1016/j.joms.2010.10.025
  14. Benoliel, R., Birenboim, R., Regev, E., & Eliav, E. (2005). Neurosensory changes in the infraorbital nerve following zygomatic fractures. *Oral Surg Oral Med Oral Pathol Oral Radiol Endod*, 99 (6), 657-665. doi:10.1016/j.tripleo.2004.10.014
  15. Mueller, C. K., Zeiß, F., Mtsariashvili, M., Thorwarth, M., & Schultze-Mosgau, S. (2012). Correlation between clinical findings and CT-measured displacement in patients with

- fractures of the zygomaticomaxillary complex. *J Craniomaxillofac Surg*, 40 (4), e93-98. doi:10.1016/j.jcms.2011.05.009
16. He, J., Chen, X., Yuan, H., Zhang, P., Jiang, H., Wang, K., & Svensson, P. (2021). Quantitative sensory testing of mandibular somatosensory function following orthognathic surgery-A pilot study in Chinese with class III malocclusion. *J Oral Rehabil*. doi:10.1111/joor.13225
  17. Kabasawa, Y., Harada, K., Jinno, S., Satoh, Y., Maruoka, Y., & Omura, K. (2006). A new evaluation method for neurosensory disturbance in the chin of patients undergoing mandibular sagittal split ramus osteotomy: an application of the heat flux technique. *Oral Surg Oral Med Oral Pathol Oral Radiol Endod*, 102 (6), 719-724. doi:10.1016/j.tripleo.2005.11.001
  18. Politis, C., Sun, Y., Lambrechts, I., & Agbaje, J. O. (2013). Self-reported hypoesthesia of the lower lip after sagittal split osteotomy. *Int J Oral Maxillofac Surg*, 42 (7), 823-829. doi:10.1016/j.ijom.2013.03.020
  19. Ueki, K., Hashiba, Y., Marukawa, K., Nakagawa, K., Alam, S., Okabe, K., & Yamamoto, E. (2009). The effects of changing position and angle of the proximal segment after intraoral vertical ramus osteotomy. *Int J Oral Maxillofac Surg*, 38(10), 1041-1047. doi:10.1016/j.ijom.2009.04.021
  20. Thygesen, T. H., Bardow, A., Helleberg, M., Norholt, S. E., Jensen, J., & Svensson, P. (2008). Risk factors affecting somatosensory function after sagittal split osteotomy. *J Oral Maxillofac Surg*, 66 (3), 469-474. doi:10.1016/j.joms.2007.06.666
  21. Matsumoto, K., Morita, K., Jinno, S., & Omura, K. (2014). Sensory changes after tongue reduction for macroglossia. *Oral Surg Oral Med Oral Pathol Oral Radiol*, 117 (1), e1-2. doi:10.1016/j.oooo.2012.02.037
  22. Leizerovitz, M., & Leizerovitz, O. (2013). Reduced complications by modified and grafted coronectomy vs. standard coronectomy-a case series. *Alpha Omegan*, 106(3-4), 81-89.
  23. Yan, Z. Y., Yan, X. Y., Guo, C. B., Xie, Q. F., Yang, G. J., & Cui, N. H. (2020). Somatosensory changes in Chinese patients after coronectomy vs. total extraction of mandibular third molar: a prospective study. *Clin Oral Investig*, 24 (9), 3017-3028. doi:10.1007/s00784-019-03169-4
  24. Poort, L. J., van Neck, J. W., & van der Wal, K. G. (2009). Sensory testing of inferior alveolar nerve injuries: a review of methods used in prospective studies. *J Oral Maxillofac Surg*, 67 (2), 292-300. doi:10.1016/j.joms.2008.06.076
  25. Al-Bishri, A., Rosenquist, J., & Sunzel, B. (2004). On neurosensory disturbance after sagittal split osteotomy. *J Oral Maxillofac Surg*, 62(12), 1472-1476. doi:10.1016/j.joms.2004.04.021
  26. Barron, R. P., Benoliel, R., Zeltser, R., Eliav, E., Nahlieli, O., & Gracely, R. H. (2004). Effect of dexamethasone and dipyrone on lingual and inferior alveolar nerve hypersensitivity following third molar extractions: preliminary report. *J Orofac Pain*, 18 (1), 62-68.
  27. Seo, K., Inada, Y., Terumitsu, M., Nakamura, T., Shigeno, K., Tanaka, Y., Matsuzawa, H. (2013). Protracted delay in taste sensation recovery after surgical lingual nerve repair: a case report. *J Med Case Rep*, 7, 77. doi:10.1186/1752-1947-7-77
  28. Grelik, C., Allard, S., & Ribeiro-da-Silva, A. (2005). Changes in nociceptive sensory innervation in the epidermis of the rat lower lip skin in a model of neuropathic pain. *Neurosci Lett*, 389 (3), 140-145. doi:10.1016/j.neulet.2005.07.056
  29. Barghash, Z., Larsen, J. O., Al-Bishri, A., & Kahnberg, K. E. (2013). Degeneration and

- regeneration of motor and sensory nerves: a stereological study of crush lesions in rat facial and mental nerves. *Int J Oral Maxillofac Surg*, 42 (12), 1566-1574. doi:10.1016/j.ijom.2013.04.017
30. Kim, H. Y., Park, C. K., Cho, I. H., Jung, S. J., Kim, J. S., & Oh, S. B. (2008). Differential Changes in TRPV1 expression after trigeminal sensory nerve injury. *J Pain*, 9 (3), 280-288. doi:10.1016/j.jpain.2007.11.013
  31. Zakir, H. M., Mostafaezur, R. M., Suzuki, A., Hitomi, S., Suzuki, I., Maeda, T., Kitagawa, J. (2012). Expression of TRPV1 channels after nerve injury provides an essential delivery tool for neuropathic pain attenuation. *PLoS One*, 7 (9), e44023. doi:10.1371/journal.pone.0044023
  32. Zuniga, J. R. (1999). Trigeminal ganglion cell response to mental nerve transection and repair in the rat. *J Oral Maxillofac Surg*, 57 (4), 427-437. doi:10.1016/s0278-2391 (99) 90284-7
  33. Nakagawa, K., Takeda, M., Tsuboi, Y., Kondo, M., Kitagawa, J., Matsumoto, S., Iwata, K. (2010). Alteration of primary afferent activity following inferior alveolar nerve transection in rats. *Mol Pain*, 6, 9. doi:10.1186/1744-8069-6-9
  34. Hossain, M. Z., Shinoda, M., Unno, S., Ando, H., Masuda, Y., Iwata, K., & Kitagawa, J. (2017). Involvement of microglia and astroglia in modulation of the orofacial motor functions in rats with neuropathic pain. *Journal of Oral Biosciences*, 59 (1), 17-22. doi:https://doi.org/10.1016/j.job.2016.11.003
  35. Piao, Z. G., Cho, I. H., Park, C. K., Hong, J. P., Choi, S. Y., Lee, S. J., Oh, S. B. (2006). Activation of glia and microglial p38 MAPK in medullary dorsal horn contributes to tactile hypersensitivity following trigeminal sensory nerve injury. *Pain*, 121 (3), 219-231. doi:10.1016/j.pain.2005.12.023
  36. Vit, J. P., Jasmin, L., Bhargava, A., & Ohara, P. T. (2006). Satellite glial cells in the trigeminal ganglion as a determinant of orofacial neuropathic pain. *Neuron Glia Biol*, 2 (4), 247-257. doi:10.1017/s1740925x07000427
  37. Hossain, M. Z., Unno, S., Ando, H., Masuda, Y., & Kitagawa, J. (2017). Neuron-Glia Crosstalk and Neuropathic Pain: Involvement in the Modulation of Motor Activity in the Orofacial Region. *Int J Mol Sci*, 18(10). doi:10.3390/ijms18102051
  38. Martin, Y. B., Malmierca, E., Avendaño, C., & Nuñez, A. (2010). Neuronal disinhibition in the trigeminal nucleus caudalis in a model of chronic neuropathic pain. *Eur J Neurosci*, 32 (3), 399-408. doi:10.1111/j.1460-9568.2010.07302.x
  39. Kiyomoto, M., Shiota, T., Moriya, T., Sato, H., Nakamura, S., & Inoue, T. (2018). Experimental Study on Involvement of the Central Nervous System in Inferior Alveolar Nerve Damage-Associated Hyperalgesia of the Mental Region. *J Oral Maxillofac Surg*, 76 (10), 2089.e2081-2089.e2088. doi:10.1016/j.joms.2018.06.021
  40. Ouachikh, O., Hafidi, A., Boucher, Y., & Dieb, W. (2018). Electrical Synapses are Involved in Orofacial Neuropathic Pain. *Neuroscience*, 382, 69-79. doi:10.1016/j.neuroscience.2018.04.041
  41. Mills, E. P., Di Pietro, F., Alshelh, Z., Peck, C. C., Murray, G. M., Vickers, E. R., & Hender-

- son, L. A. (2018). Brainstem Pain-Control Circuitry Connectivity in Chronic Neuropathic Pain. *J Neurosci*, 38 (2), 465-473. doi:10.1523/jneurosci.1647-17.2017
42. Tamada, M., Ohi, Y., Kodama, D., Miyazawa, K., Goto, S., & Haji, A. (2021). Modulation of excitatory synaptic transmissions by TRPV1 in the spinal trigeminal subnucleus caudalis neurons of neuropathic pain rats. *Eur J Pharmacol*, 913, 174625. doi:10.1016/j.ejphar.2021.174625
43. Colloca, L., Ludman, T., Bouhassira, D., Baron, R., Dickenson, A. H., Yarnitsky, D., Raja, S. N. (2017). Neuropathic pain. *Nat Rev Dis Primers*, 3, 17002. doi:10.1038/nrdp.2017.2
44. Loeser, J. D., & Treede, R. D. (2008). The Kyoto protocol of IASP Basic Pain Terminology. *Pain*, 137 (3), 473-477. doi:10.1016/j.pain.2008.04.025
45. Bennett, G. J. (2012). What is spontaneous pain and who has it? *J Pain*, 13 (10), 921-929. doi:10.1016/j.jpain.2012.05.008
46. Hillerup, S. (2007). Iatrogenic injury to oral branches of the trigeminal nerve: records of 449 cases. *Clin Oral Investig*, 11 (2), 133-142. doi:10.1007/s00784-006-0089-5
47. Hashemi, H. M. (2010). Neurosensory function following mandibular nerve lateralization for placement of implants. *Int J Oral Maxillofac Surg*, 39 (5), 452-456. doi:10.1016/j.ijom.2010.02.003



Attribution (BY-NC) - (BY) You must give appropriate credit, provide a link to the license, and indicate if changes were made. You may do so in any reasonable manner, but not in any way that suggest the licensor endorses you or your use. (NC) You may not use the material for commercial purposes.