

CASE REPORT

DOI: 10.15517/IJDS.2022.52388

Received:
12-V-2022

Foreign Body Granuloma in the Maxillofacial Region:
Report of an Unusual Case

Accepted:
8-VIII-2022

Published Online:
7-IX-2022

Granuloma por cuerpo extraño en la región maxilofacial:
reporte de un caso inusual

Mónica Orozco-Gallardo DDS¹; Evangelina Gutiérrez-Cortés MSc²;
Silverio Jafet Vázquez-Alcaraz MSc³; Andréa Dolores Correia Miranda Valdivia PhD⁴

1. Postgraduate Student, Department of Prosthodontics, Faculty of Dentistry, Autonomous University of Guadalajara, Guadalajara, Jalisco, México. <https://orcid.org/0000-0002-0042-7309>
2. Professor of Oral Pathology, Faculty of Dentistry, Autonomous University of Guadalajara, Jalisco, México. <https://orcid.org/0000-0003-0115-1110>
3. Department of Conservative Dentistry, Faculty of Dentistry, Complutense University, Madrid, Spain. <https://orcid.org/0000-0001-5043-9407>
4. Researcher Professor, Department of Specialised Dentistry Faculty of Dentistry, Autonomous University of Guadalajara, Jalisco, México. <https://orcid.org/0000-0002-9688-6461>

Correspondence to: Andréa Dolores Correia Miranda Valdivia - andrea.correia@edu.uag.mx

ABSTRACT: This paper aimed to present a clinical case presenting an unusual periapical radiolucent lesion, its approach and treatment, and as an element of differential diagnosis in periapical pathology. Foreign body granuloma (FBG) is a tissue reaction that is triggered by the deposit of a foreign material affecting the skin and internal organs that the immune system tries to delimit and, if possible, eliminate. FBG may constitute a complication of a surgical procedure or a new pathology for the patient, which precedes an iatrogenic event causing diagnostic difficulties. This study presented an unusual periapical radiolucent lesion in a male patient with a periapical radiolucent area found in panoramic radiography; the lesion was enucleated, histopathologically confirming an FBG, which was the result of a biomaterial used in surgery for nasal polyps and deviated septum performed years before. This case shows us a very unusual presentation of an FBG within the maxillary bone after surgery for nasal polyps and deviated septum. The appropriate use of the available imaging tools and histopathological study and interpretation is emphasized, to be able to carry out a successful long-term treatment with the lowest chances of recurrence. In addition, an interdisciplinary approach is very important, which leads us to the comprehensive treatment of the patient. The proper use of diagnostic and imaging methods that we currently have, as well as knowledge of differential diagnoses, is essential to successfully diagnose and treat injuries in the maxillofacial area.

KEYWORDS: Granuloma; Foreign bodies; Oral pathology; Oral surgery.

RESUMEN: El objetivo de este artículo es exponer un caso clínico con presentación de una lesión radiolúcida periapical inusual, su abordaje y tratamiento, así como su propuesta de elemento de diagnóstico diferencial en patologías periapicales. El granuloma de cuerpo extraño (GCE) es una reacción tisular desencadenada por el depósito de un material extraño que afecta a la piel y a los órganos internos y que el sistema inmunitario trata de delimitar y, si es posible, eliminar. El FBG puede constituir una complicación de una intervención quirúrgica o una patología nueva para el paciente, que precede a un evento iatrogénico causando dificultades de diagnóstico. En este estudio se presenta una lesión radiolúcida periapical inusual en un paciente varón con un área radiolúcida periapical encontrada en la radiografía panorámica; la lesión fue enucleada, confirmando histopatológicamente un FBG, que era el resultado de un biomaterial utilizado en la cirugía de pólipos nasales y tabique desviado realizada años antes. Este caso nos muestra una presentación muy inusual de un FBG dentro del hueso maxilar tras una cirugía de pólipos nasales y desviación de tabique. Se enfatiza el uso adecuado de las herramientas de imagen disponibles y el estudio e interpretación histopatológica, para poder llevar a cabo un tratamiento exitoso a largo plazo con las menores posibilidades de recurrencia. Además, es muy importante el enfoque interdisciplinario, que nos lleva al tratamiento integral del paciente. El uso adecuado de los métodos diagnósticos y de imagen que tenemos en la actualidad, así como el conocimiento de los diagnósticos diferenciales, es fundamental para diagnosticar y tratar con éxito las lesiones en el área maxilofacial.

PALABRAS CLAVE: Granuloma; Cuerpos extraños; Patología bucal; Cirugía bucal.

INTRODUCTION

Foreign body granuloma (FBG) is a tissue reaction that is triggered by the deposit of a foreign material affecting the skin and internal organs that the immune system tries to delimit and, if possible, eliminate (1). FBG may constitute a complication of a surgical procedure or a new pathology for the patient, which precedes an iatrogenic event causing diagnostic difficulties (2). The classification of FBG is based on the nature of the foreign body: traumatic (inorganic compounds, metals, plastics, plant compounds, and animal compounds) cosmetic, occupational, and postsurgical (3). Surgical gauze or other surgical items

can become retained foreign bodies after surgery and has been reported to be 1:2,000-5:000 in surgical procedures, which can lead to serious complications (4).

FBG reaction is determined by material properties (shape, size, roughness, porosity, and composition), the duration of exposure, and the ability of the body to degrade the foreign body (5). Among the clinical diagnostic keys are the antecedent of inoculation, either by trauma or surgery, papules or nodules with a variable inflammatory component, and occasional extrusion of foreign material (1). Histologically, a granulomatous infiltrate with histiocytes and multinucleated giant cells of the

foreign body type is observed. In some situations, it is possible to identify amorphous structures that correspond to exogenous material (1).

Foreign bodies in the maxillofacial region are generally overlooked (4). Amalgam, suture threads, endodontic sealants, and gutta-percha are some examples of dental materials capable of causing an FBG reaction. However, granulomatous inflammation in the hard and soft structures of the mouth is a very rare event (6).

From a dental approach, radiolucent periapical lesions are one of the most frequent clinical findings in daily dental practice. Most of these are attributed to apical periodontitis, which consists of the establishment of an inflammatory process located in the periapical tissues as a consequence of infection and subsequent devitalization of the tooth. Radicular cysts are the most common inflammatory lesions in the jaws; they are located near and around the apices of the affected teeth and are generally preceded by a periapical granuloma. The latter consists of the formation of granulation tissue with a cellular infiltrate and a capsule of connective tissue (7). Different pathological conditions can be present as periapical radiolucent lesions; however, the poorly defined radiographic features that are seen repeatedly in both granulomas and cysts can present some difficulties in making a specific radiographic diagnosis (8).

The objective of this article is to present a clinical case presenting an unusual periapical radiolucent lesion, its approach and treatment, and as an element of differential diagnosis in periapical pathology.

CASE REPORT

A 62-year-old male patient was presented to the diagnostic department of the clinic of the Faculty of Dentistry of the Universidad Autónoma

de Guadalajara for a dental cleaning during October of 2016.

The informed consent was read and signed, and medical history was performed. We found that the patient was hypertensive and diabetic, for which he was treated with enalapril and metformin and mixed insulin, respectively, and was allergic to penicillin. He also reported that five years earlier, he had undergone surgery with an intraoral approach (Caldwell-Luc approach) for nasal polyps and a deviated septum and presented a panoramic radiograph to complement his dental history.

Radiographic examination revealed a periapical radiolucent area between teeth 24 and 25 (upper left premolars) with an unusual characteristic (Figure 1. A and B). Sensitivity tests were performed using ethyl chloride to determine the pulp condition of teeth 24 and 25. The result was negative for the sensitivity of teeth 24 (upper left first premolar), obtaining the presumptive diagnosis of pulp necrosis and periapical pathology (chronic apical periodontitis). It should be noted that the teeth did not present an evident or radiographic carious lesion.

The root canal treatment of teeth 24 was carried out in a conventional way with the consent of the patient. Biomechanical work with NITI-FLEX Maillefer files (Densply, Co), irrigation with 2.5% sodium hypochlorite, lateral condensation obturation with standardized gutta-percha, and AH PLUS Maillefer sealant cement (Densply, Co) were performed with camera access. On radiographic evaluation, due to its size and shape, it was decided to subject the lesion to enucleation and histopathological assessment, as well as apicoectomy of the teeth 2 months after root canal treatment.

After two months of endodontic treatment, the lesion was continued to be observed radiographically in the same way, without reducing its size

or radiolucency (Figure 1. C). Surgical treatment was carried out during which two cartridges of 1.8 ml of 4%Articaine with 1:100,000 epinephrine (80 mg) (Turbocaine, ZEYCO) using infraorbital technique reinforced with palatal infiltration were used for anesthesia. A Newman-type flap was started from the first molar to the canine with a liberatríz in the latter using a 15c scalpel blade (Ribbel, AMBRI-DERM); the flap was raised, and no vestibular bone wall was observed; however, a fibrous capsule firmly adhered to the vestibular mucosa was found and was dissected with a scalpel (Figure 2. A). The bone window was widened using a low-speed ball bur under a profuse irrigation of distilled water, detaching the capsule from the pathological cavity. An unrecognizable hard material was then found inside the capsule, and it was observed that the lesion had no contact or communication with the dental apex, so only the lesion was enucleated (Figure 2., B and C); no apical recession of the involved tooth was observed. Simple suture using a 3-0 non-absorbable thread (Surgical, Surgical Especialidades Químicas Farmacias) was performed, and antibiotic therapy as well as anti-inflammatory and analgesic medication were indicated. The patient was returned seven days later for suture removal.

The surgical sample was sent for histopathological analysis. A thick fibrous capsule with the presence of internal spaces was observed, some of them showing the presence of exogenous acellular dark brown material (Figure 3. A); another section shows areas with a solid arrangement, and others with a honeycomb pattern, the presence of few multinucleated giant cells, and the absence of inflammatory infiltrate as well as odontogenic epithelium (Figure 3. B and C). Thus, a diagnosis of FOREIGN BODY GRANULOMA was made. No data on malignancy were found. The hard material contained in the capsule was lost during tissue processing, so its histological analysis was not possible.

At the 6-month check-up in the radiographic follow-up, the presence of a radiopaque tissue was observed on the internal walls of the cavity where the enucleated lesion was, mainly in the distal area (Figure 4. B). In the 12-month radiographic evaluation, a considerable increase in bone density is observed in the area where the lesion was previously located (Figure 4. C). Adequate bone healing was observed within 4 years (Figure 4. C and D).

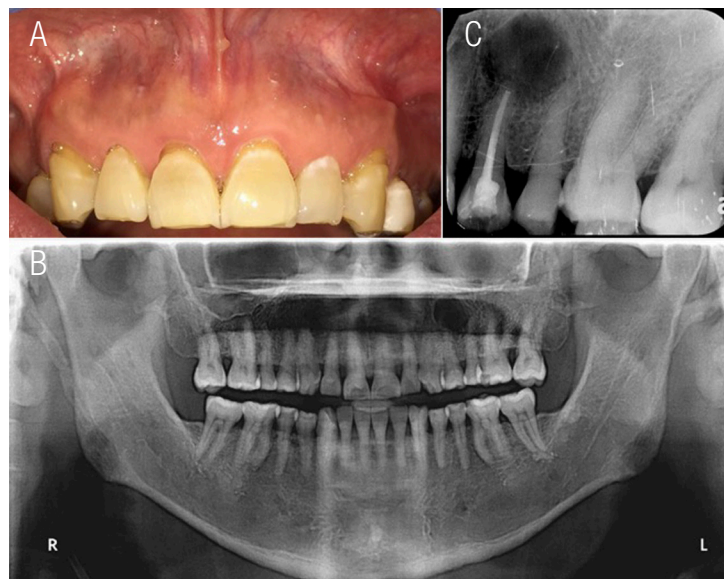


Figure 1. Areas of the lesion. A. View of the upper vestibular alveolar mucosa showing a defect at the level of the left canine. B. Panoramic radiograph showing a radiolucent area with well-defined borders in the periapical area between the upper left premolars. C. Teeth number 24 with completed root canal treatment. Area of the lesion in which zones of mixed density can be observed.

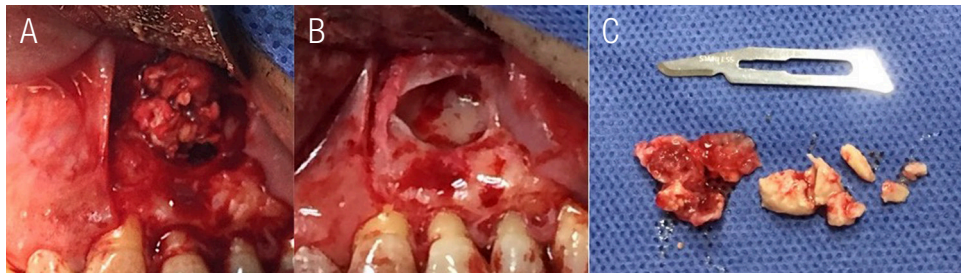


Figure 2. Treatment of the lesion. A. An irregular-looking lesion is observed. B. Remaining cavity when the lesion and surrounding tissue were removed. C. Surgical sample: on the right side is the content, and on the left is the interior of the tissue surrounding it.

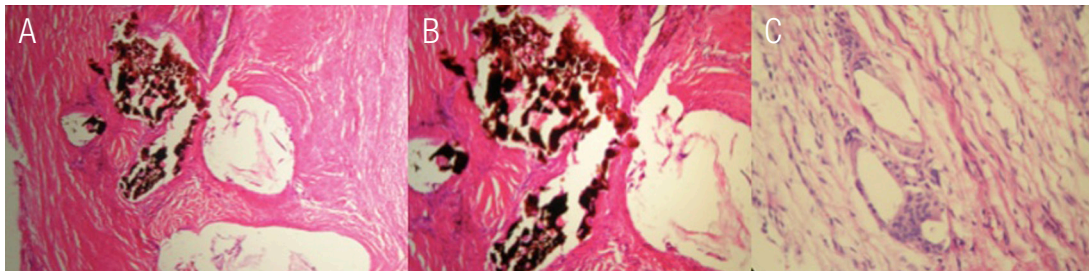


Figure 3. Histological sections. A and B. The thick fibrous capsule is observed with the presence of internal spaces, some of them showing the presence of a dark brown acellular exogenous material. C. Presence of multinucleated giant cells related to exogenous material and absence of odontogenic epithelium.

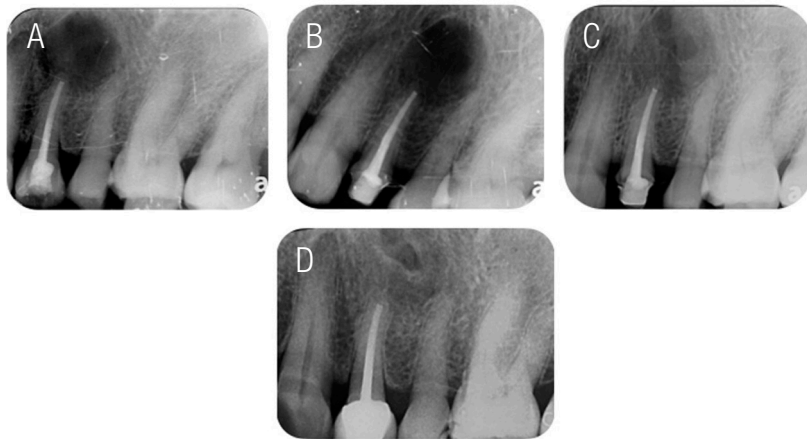


Figure 4. Periapical radiographs of the lesion. A. Lesion before surgery. B. Radiographic control of the lesion area at 6 months. C. Radiographic control of the lesion area at 1year. D. Radiographic control of the lesion at 4 years.

DISCUSSION

An FBG is a diagnostic challenge for dentists, and it requires the association of data collected during the interview, clinical findings, and complementary imaging tests since these provide important particularities for the diagnosis (6). The visualization of foreign bodies is associated with the density and proximity of the tissues, as well as the location in which they are found. Imaging studies of the lesion, in addition to clinical findings and anamnesis, are useful for diagnosis. However, histological examination is decisive for a definitive diagnosis (9).

Foreign body injuries represent 3.8% of all pathologies found in the head and neck region (10). Approximately one-third of all foreign bodies are missed during initial clinical and radiographic examinations, which can lead to significant complications; these can become irritated, causing inflammation, infection, abscesses, pain, swelling, migration of the foreign body, and possible damage to the vessels or nerves. Additionally, inflammatory reactions and granuloma formation can affect wound healing (10). In order to avoid complications, foreign bodies should be detected and removed as soon as possible. The treatment of FBG consists of the surgical removal of the lesion together with the foreign material that is generating the granulomatous reaction. This type of intervention gives a good prognosis without the probability of recurrence (4).

By routine examination using the panoramic radiograph, it is possible to identify multiple types of abnormalities affecting the maxillary and mandibular bones. The potential anomalies to be found are generally limited to the presence of lesions of various kinds in the paranasal sinuses, mainly in the maxillary sinus, and which, depending on their location, extension, and shape, could require other complementary tests, such as cone beam compu-

ted tomography (CBCT), to perform a differential diagnosis (7).

Sometimes surgical materials are left behind at either or both the surgical site and other areas in the patient during various surgical procedures. The incidence of foreign bodies in the maxillofacial region is unclear compared with other surgical procedures. Foreign bodies in the oral and maxillofacial region are usually radiolucent and can be detected as radiographic findings (4). Patients usually consult doctors due to a transitory symptomatology and few for persistent clinical manifestations or secondary complications. In other cases, the foreign body is an incidental finding during a medical procedure (8).

This case presented the approach to an FBG in the maxilla at the level of the root of the upper left first premolar, which, at first glance, appeared to be a common periapical endodontic lesion of bacterial origin. Although the tooth had no signs of carious lesions on clinical inspection, the pulp sensitivity tests resulted in a negative response, so the presumptive diagnosis made was necrotic pulp lesion and chronic apical periodontitis, which was rejected during the surgical approach when the lesion was enucleated, noting that it had no connection with the root apex.

With the results of the histopathological study, the otorhinolaryngologist who treated the nasal polyps and the patient's deviated septum years ago was contacted, requesting to review the surgical file to verify if any regeneration material had been placed in the area that could have remained in the involved upper maxillary area, which could have been the origin of the FBG presented in this clinical case.

For the most part, the radiolucent lesions of the jaw seen on conventional radiographs represent benign lesions that do not require further

examination. However, certain radiological characteristics, such as the increased size of the lesion, the bony scalloping, its relationship with an impacted tooth or the mandibular canal, the resorption of the teeth, as well as the ill-defined edges of the lesion, require additional radiological studies (11).

Conventional periapical radiographs or panoramic radiographs are usually the initial imaging techniques for the detection of a foreign body; however, non-radiopaque objects cannot be detected with these techniques, so computed tomography (CT), CBCT, ultrasonography, and magnetic resonance imaging may be viable alternatives for their diagnosis. Tissue overlap is limited to 2D images; thus CT is the standard model to detect foreign bodies¹⁰. In our case, the tomography of the initial lesion was not requested, and with this, the possibility of observing the shape, position, and location of the lesion in the maxilla in 3D was lost, which probably would have helped suspected a periapical lesion of non-dental origin.

CONCLUSION

This case shows us a very unusual presentation of an FBG within the maxillary bone after surgery for nasal polyps and deviated septum. The appropriate use of the available imaging tools and histopathological study and interpretation is emphasized, to be able to carry out a successful long-term treatment with the lowest chances of recurrence. In addition, an interdisciplinary approach is very important, which leads us to the comprehensive treatment of the patient.

CLINICAL SIGNIFICANCE

The proper use of diagnostic and imaging methods that we currently have, as well as knowledge of differential diagnoses, is essential to successfully diagnose and treat injuries in the maxillofacial area.

INTEREST CONFLICT

The authors do not report any conflict of interest.

AUTHOR CONTRIBUTION STATEMENT

Writing-original draft preparation: M.O-G.

Literature Review: M.O-G.; E.G-C.; S.J V-A. and A.D.C.M.V.

Writing-review & editing: E.G-C.; S.J V-A. and A.D.C.M.V.

ACKNOWLEDGMENT

This publication was supported by grants from the Universidad Autónoma de Guadalajara.

REFERENCES

1. Cardona H.M.Á., Enríquez M.J., Ramos G.A., et al. Fístula cutánea y granuloma a cuerpo extraño por material de sutura. Presentación de un caso. *Rev Cent Dermatol Pascua*. 2016; 25 (2): 53-57.
2. Alfonso O., Alfonso B., Orozco M., Matzalik G. Cuerpos extraños en abdomen: presentación de casos y revisión bibliográfica. *Rev. Colomb. Cir.* 2009 [Internet]. [acceso 29/01/2021]; 24(2): 114-122. Disponible en: http://www.scielo.org.co/scielo.php?script=sci_arttext&pid=S2011-75822009000200007&lng=en.
3. Moreno A., Marcoval J. Granulomas a cuerpo extraño. *Dermatología: Correlación clínico-patológica*. Menarini 62 (2000): 255-258.
4. Tsukamoto M., Hirokawa J., Yokoyama T. Retained Foreign Body in the Nasal Cavity After Oral Maxillofacial Surgery. *Anesth Prog*. 2018; 65 (2): 111-112.
5. López C., Manchola J., Medina S., Moreno S. Reacción Granulomatosa De Tipo Cuerpo Extraño Secundaria a Biomateriales Y Su Respuesta Inmunológica: Revisión Sistemática De La Literatura. *Salutem Scientia Spiri-*

- tus. 2016 [Internet] [acceso 29 enero 2021]; 2 (1): 21-28. Disponible en: <https://revistas.javerianacali.edu.co/index.php/salutem-scientiaspiritus/article/view/1385>.
6. Pereira R.M., Afonso Pereira P.C. de O., Rodrigues V., Braga de Andrade L.F., Morais de Carvalho E., Marangon Júnior H., Foreign Body Granuloma in the Tongue by a Pequi Spine. *Case Reports in Dentistry*, vol. 2020, Article ID 8838250, 5 pages, 2020. <https://doi.org/10.1155/2020/8838250>
 7. Fuentes R., Álvarez G., Arias A., Borie-Echevarría E., Dias F. Periodontitis Apical: Caracterización Histológica y Morfométrica de Quistes Radiculares y Granulomas Periapicales. *Int. J. Morphol.* 2018 [Internet]. [acceso 30/01/ 2021]; 36 (4): 1268-1274. Disponible en: https://scielo.conicyt.cl/scielo.php?script=sci_arttext&pid=S0717-95022018000401268&lng=es. <http://dx.doi.org/10.4067/S0717-95022018000401268>.
 8. Lubinus FG, Rey CA, López LA, Villarreal ED, Vera SN. Cuerpos extraños de presentación atípica: Presentación de casos. *Rev. Colomb. Radiol.* 2019 [Internet]. [acceso 29/01/2021]; (30(3): 5199-5202. Disponible en: https://www.webcir.org/revistavirtual/articulos/2020/5_mayo/col/2_esp_cuerpos_extraños.pdf
 9. Yamamoto K., Nakayama Y., Matsusue Y., Kurihara M., Yagyuu T., Kirita T., "A Foreign Body Granuloma of the Buccal Mucosa Induced by Honeybee Sting", *Case Reports in Dentistry*, vol. 2017, Article ID 7902978, 4 pages, 2017. <https://doi.org/10.1155/2017/7902978>
 10. Abdinian M., Aminian M., Seyyedkhamesi S. Comparison of accuracy between panoramic radiography, cone-beam computed tomography, and ultrasonography in detection of foreign bodies in the maxillofacial region: an in vitro study. *J Korean Assoc Oral Maxillofac Surg.* 2018; 44 (1): 18-24. doi: 10.5125/jkaoms.2018.44.1.18.
 11. Avril L., Lombardi T., Ailianou A., Burkhardt K., Varoquaux A., Scolozzi P., Becker M. Radiolucent lesions of the mandible: a pattern-based approach to diagnosis. *Insights Imaging.* 2014; 5 (1): 85-101. doi: 10.1007/s13244-013-0298-9.

