



CASE REPORT:

Radical Surgical Approach to Chronic Suppurative Osteomyelitis: Case Report Abordaje quirúrgico radical de una osteomielitis crónica supurativa: reporte de caso

Diana Carolina Vargas-Rojas DDS, Esp.¹ <https://orcid.org/0000-0002-4619-3317>
Arturo Rodríguez-Flores DDS, Esp, MSc¹ <https://orcid.org/0000-0003-0528-7314>
David Moreno-Villalobos DDS, Esp, MSc¹ <https://orcid.org/0000-0003-4348-7042>
Victor Chumpitaz-Cerrate DDS, MSc, PhD² <https://orcid.org/0000-0001-7073-8076>
Lesly Chávez-Rimache DDS³ <https://orcid.org/0000-0001-9987-7475>

1. Servicio de Cirugía Bucal y Maxilofacial del Hospital Nacional Hipólito Unanue, Lima, Perú.
2. Grupo de Investigación en Ciencias Básicas Estomatológicas (ICBEST), Universidad Nacional Mayor de San Marcos, Lima, Perú.
3. Universidad San Ignacio de Loyola, Unidad de Investigación para la Generación y síntesis de Evidencias en Salud, Lima, Perú.

Correspondence to: PhD. Victor Chumpitaz-Cerrate - vchumpitazc@unmsm.edu.pe

Received: 12-VII-2023

Accepted: 25-IX-2023

ABSTRACT: Diabetes mellitus is a systemic condition potentially related to an increased risk of progression of various infections such as chronic osteomyelitis by accelerating the inflammatory process with bone tissue necrosis and suppuration. Therefore, if there is no proper management of these infections, they can be life-threatening as they spread to deeper spaces in the head and neck. We describe the case of a 52-year-old male patient with a history of diabetes mellitus and grade III osteoarthritis who was diagnosed with chronic suppurative osteomyelitis of the mandible. He underwent a multidisciplinary surgical intervention in which he underwent a hemimandibulectomy with immediate mandibular reconstruction. The present case highlights the importance of early and radical treatment of patients with chronic suppurative osteomyelitis of the mandible and systemic comorbidities. In addition, this case presents a review of diabetes mellitus and the risk of developing odontogenic infections and complications when invading deeper spaces in the head and neck. Therefore, in this population, careful planning is required for early surgical and pharmacological treatment.

KEYWORDS: Osteomyelitis; Diabetes mellitus; Osteoarthritis; Mandibular reconstruction; Drug therapy; Case report.



RESUMEN: La diabetes mellitus es una condición sistémica potencialmente relacionada con un mayor riesgo de progresión de diversas infecciones como la osteomielitis crónica al acelerar el proceso inflamatorio con necrosis del tejido óseo y supuración. Por lo tanto, si no hay un manejo adecuado de estas infecciones pueden ser potencialmente mortales al llegar a propagarse a espacios más profundos de la cabeza y cuello. Describimos el caso de un paciente varón de 52 años con antecedentes de diabetes mellitus y osteoartritis grado III a quien se le diagnosticó de osteomielitis crónica supurativa mandibular. Se le realizó una intervención quirúrgica multidisciplinaria en la cual se le realizó una hemimandibulectomía con reconstrucción mandibular inmediata. El presente caso destaca la importancia del tratamiento temprano y radical de los pacientes con osteomielitis mandibular crónica supurativa y comorbilidades sistémicas. Además, en este caso se presenta una revisión sobre la diabetes mellitus y el riesgo de desarrollar infecciones odontogénicas y complicaciones al invadir espacios más profundos de la cabeza y cuello. Por lo tanto, en esta población se requiere de una planificación cuidadosa para realizar un tratamiento quirúrgico y farmacológico temprano.

PALABRAS CLAVE: Osteomielitis; Diabetes mellitus; Osteoartritis; Reconstrucción mandibular; Tratamiento farmacológico; Reporte de caso.

INTRODUCTION

Diabetes mellitus is a systemic condition that has been associated with an increased likelihood of developing infections in patients. This is due to its immunosuppressive role, which is exacerbated in patients who do not have adequate control of the disease (1). In dentistry, diabetes has been linked to an increase in morbidity and mortality from odontogenic infections (2). This is because diabetes mellitus affects the healing process, and in turn, hyperglycemia affects coagulation, endothelial function, and fibrinolysis (3, 4). Moreover, hyperglycemia alters chemotaxis, adherence, phagocytosis, and other immune system alterations, decreasing the function of neutrophils and monocytes (5-7). The possibility of infection progression increases in situations of immunosuppression, where oral abscesses can become deep neck infections. This not only increases the complexity and difficulty

of treatment, but also leads to the patient having a higher risk of complications and death (8, 9). This situation has led dentists to postpone dental treatments until the patient reaches "normal" glucose values. Carey *et al.* (10) in a retrospective cohort study found that patients with type 2 diabetes mellitus had a higher mortality rate related to infection [1.92 (95% CI: 1.75 to 2.10)]. Additionally, they reported that 12.4% of deaths caused by infection could be attributed to diabetes. On the other hand, they mention that diabetic patients should receive immediate, adequate, and timely management for any type of infection that has the potential to become complicated.

Chronic suppurative osteomyelitis of the mandible is a complex multifactorial disease (11) whose management represents a challenge for oral and maxillofacial surgeons due to its anatomical location and polymicrobial nature. In addition, its

management requires expensive treatments and prolonged hospital stays (12, 13). Baur *et al.* (14) mentioned that diseases that produce immunosuppression (such as diabetes, malnutrition, and neoplasms) and other diseases that produce bone hypovascularization could predispose to a higher risk of mandibular osteomyelitis. Furthermore, Sood *et al.* (15) found that immunosuppressed patients, such as those with diabetes, face harder challenges in the treatment of osteomyelitis because they may require more radical treatments to reduce the risk of osteomyelitis recurrence. The objective of this study is to describe a case that highlights the importance of early and aggressive treatment of a patient with chronic suppurative osteomyelitis of the mandible and diabetes as a comorbidity.

CASE REPORT

A 52-year-old male patient presented to the Oral and Maxillofacial Surgery Department of the Hipólito Unanue National Hospital. The patient was referred by the Traumatology department after having suffered a fall three months ago, hitting his hip and chin. The patient reported dental mobility, pain in the lower left region, and loss of sensitivity in the lower lip and chin. His medical history indicated grade III osteoarthritis which was diagnosed five years ago and he was taking oral analgesics/anti-inflammatories for pain (diclofenac 50 mg, in cases of severe pain associated with dexamethasone 4 mg). In addition, the patient was diagnosed with type 2 diabetes mellitus by the endocrinology service a month ago and he was medicated with metformin 850 mg orally every 8 hours. The patient did not attend his trauma check-ups and reported that he self-medicated with dexamethasone 4 mg orally every 8 hours for three months due to the intense pain he presented after the fall. In the extraoral evaluation, the patient presented swelling in the left genial and masseteric region

with hypoesthesia of the chin and lower left lip. In the intraoral evaluation, the patient presented severe periodontitis, trismus, bone exposure of the alveolar ridge of the third quadrant, purulent discharge, and absence of teeth 36, 37, 38. In the imaging evaluation, the tomography showed a fracture in the left mandibular ramus with loss of continuity of the vestibular and lingual cortex in the symphysis, body, ramus, and condyle (Figure 1).

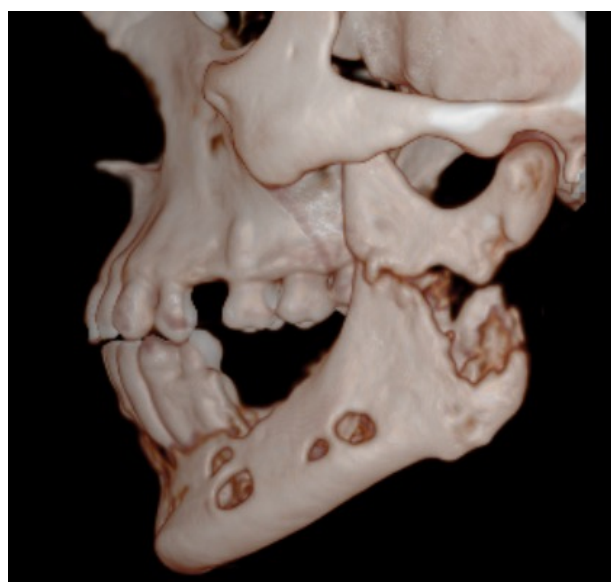


Figure 1. Computed tomography scan of facial mass (3D reconstruction) - Left lateral preoperative view.

The diagnosis was chronic suppurative osteomyelitis of the mandible confirmed by histopathological analysis. The planning of the patient's treatment was carried out in a multidisciplinary way with the participation of three surgical teams: oral and maxillofacial surgery, thoracic and cardiovascular surgery (to obtain the costochondral graft), and traumatology (to obtain the fascia lata of the thigh). The surgical procedure consisted of a hemimandibulectomy performed through a "lip split" extraoral approach, after which the lesion was dissected in layers until the entire lesion was exposed (Figure 2).

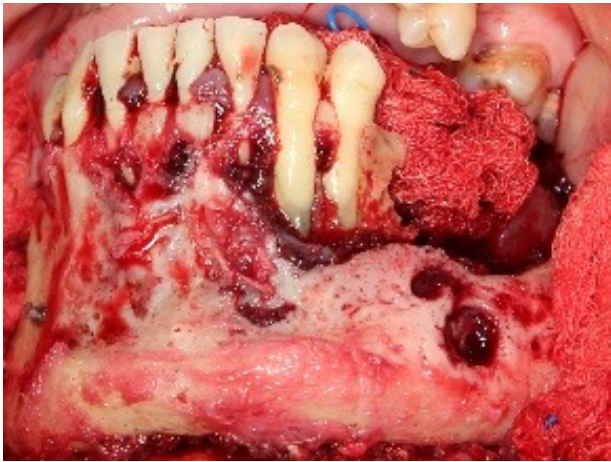


Figure 2. The surgical site shows extensive bone destruction.

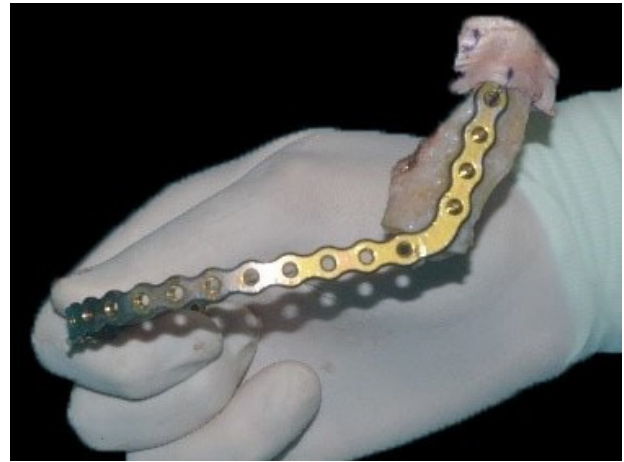

Figure 3. Lateral view of bone graft with reconstruction plate.

Subsequently, the musculature was disinserted and the left hemimandible was resected considering the margin anterior or proximal to piece 44. Once the defect was exposed, the operating field was cleaned with a saline solution and hemostasis was promoted. The mandibular reconstruction was performed using a costochondral graft plus fascia lata to replace the condyle and joint. Maxillomandibular fixation was then performed and the osteosynthesis material was fixed with the reconstruction plate (Figure 3). After that, the flap was repositioned and closed from the facial planes. Pharmacological treatment consisted of intravenous administration of vancomycin 500 mg every 12 h and meropenem 1 g every 8 h for 12 days. After discharge, the patient continued oral treatment with clindamycin 300 mg every 6 h for 14 days and then with ciprofloxacin 500 mg every 12 h for 14 days. Periodic controls were performed every six months with a favourable clinical evolution of the patient. Figure 4 shows the follow-up at 3 years and 7 months after surgery.

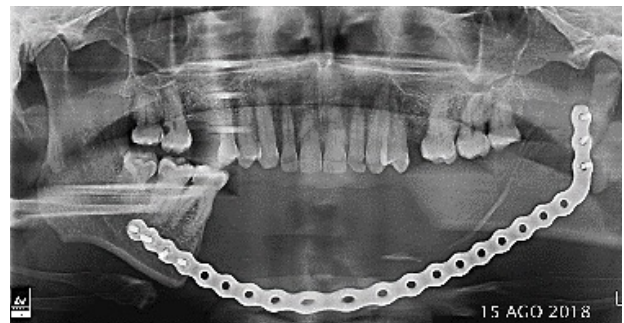


Figure 4. Annual postoperative control orthopantomography.

DISCUSSION

Patients with diabetes mellitus or diseases that compromise the immune system may present mild odontogenic infections that can rapidly progress to deeper spaces in the head and/or neck (16-18). This not only makes treatment difficult but also exposes patients to a higher risk of complications and death (2, 18-20). The present case reports the early and aggressive treatment of a patient with type 2 diabetes mellitus and arthritis, who self-medicated with dexamethasone for three

months (prolonged administration of which produces immunosuppression) and presented a rapid progression to chronic suppurative osteomyelitis of the mandible.

Kasperk *et al.* (21) reported that diabetes mellitus affects bone metabolism and may increase the risk of fractures. This is due to the suppression of bone formation and stimulation of bone resorption. In addition, if we also consider local factors such as severe periodontitis, it could lead to a higher risk of odontogenic infections. Baur *et al.* (14) stated that patients with chronic osteomyelitis of the mandible and comorbidities such as diabetes mellitus exhibit arterial stiffness and microvascular rarefaction due to hypertrophic remodeling of blood vessels. This suggests an association between chronic osteomyelitis of the mandible and microvascular involvement in patients with diabetes. Ko *et al.* (2) found that patients with diabetes mellitus had a higher risk of developing odontogenic infections involving multiple facial spaces (facial cellulitis and deep cervical infections).

In relation to long-term corticosteroid treatment, Giles *et al.* (22) mentioned that corticosteroids cause immunosuppression by decreasing the proliferation and differentiation of a subset of T cells. However, the exact molecular mechanisms by which this effect occurs are still unknown. In addition, Barshes *et al.* (23) mentioned that corticosteroids have two main immunosuppressive effects, the first being the sequestration of T-CD4+ lymphocytes in the reticuloendothelial system (RES) and the second being the inhibition of lymphokines and cytokines, especially IL-1 and IL-6. Additionally, there is a relationship between the use of corticosteroids and hyperglycemia, as

corticosteroids can increase blood glucose levels which can worsen the severity of diabetes (24).

On the other hand, chronic suppurative osteomyelitis of the mandible in adults is potentially refractory if surgical debridement is inadequate, regardless of antibiotic therapy (2). In the present case, we performed aggressive treatment due to the extensive bone destruction and the patient's systemic condition that led to the rapid progression of the disease.

Baur *et al.* (14) reported that 50% of patients with chronic suppurative osteomyelitis of the maxilla who underwent marginal resection had a recurrence, compared to a recurrence rate of 5.5% in patients who underwent segmental resection. They mention that conservative management in patients with chronic osteomyelitis of the mandible results in a longer treatment period, more surgeries, and thus increased resource utilization and costs. So, an initially more aggressive surgical treatment could lead to a higher likelihood of success for the patient's clinical outcome.

CONCLUSIONS

In conclusion, the microvascular involvement and immunosuppression caused by diabetes and corticosteroid use, along with local factors (such as periodontal disease and trauma), contribute to the progression of chronic osteomyelitis of the mandible by exacerbating the clinical picture. In patients with these systemic conditions, timely surgical excision of the affected tissue with appropriate pharmacological treatment is crucial for successful management due to the risk of recurrence and postoperative complications.

FUNDING

This article was self-financed by the authors.

CONFLICT OF INTEREST

The authors declare that they have no conflict of interest.

AUTHOR CONTRIBUTION STATEMENT

Conceptualization and design: D.C.V.R. and A.R.F.

Literature review: L.C.R.

Investigation and data collection: D.C.V.R., A.R.F. and D.M.V.

Data analysis and interpretation: D.C.V.R., A.R.F. and D.M.V.

Writing-original draft preparation: D.C.V.R., V.C.C. and L.C.R.

Writing-review & editing: D.C.V.R., D.M.V., V.C.C. and L.C.R.

Supervision: D.M.V.

ACKNOWLEDGMENTS

We would like to thank the Oral and Maxillo-facial Surgery Department of the Hipólito Unanue National Hospital and the entire team of specialists who performed the surgical procedure on the patient.

REFERENCES

1. Abu-Ashour W., Twells L., Valcour J., Randell A., Donnan J., Howse P., et al. The association between diabetes mellitus and incident infections: a systematic review and meta-analysis of observational studies. *BMJ Open Diabetes Research and Care*. 2017 May 1; 5 (1): e000336.
2. Ko H.H., Chien W.C., Lin Y.H., Chung C.H., Cheng S.J. Examining the correlation between diabetes and odontogenic infection: A nationwide, retrospective, matched-cohort study in Taiwan. *PLoS One*. 2017 Jun 8; 12 (6): e0178941. doi: 10.1371/journal.pone.0178941
3. Carr M.E. Diabetes mellitus: a hypercoagulable state. *J Diabetes Complications*. 2001 Jan-Feb; 15 (1): 44-54. doi: 10.1016/s1056-8727(00)00132-x
4. Ammar R.F. Jr., Gutterman D.D., Brooks L.A., Dellsperger K.C. Free radicals mediate endothelial dysfunction of coronary arterioles in diabetes. *Cardiovasc Res*. 2000 Aug 18; 47 (3): 595-601. doi: 10.1016/s0008-6363(00)00094-8
5. DiGangi C. Neutrophil-lymphocyte ratio: Predicting cardiovascular and renal complications in patients with diabetes. *J Am Assoc Nurse Pract*. 2016 Aug; 28 (8): 410-4. doi: 10.1002/2327-6924.12366
6. Valerius N.H., Eff C., Hansen N.E, Karle H., Nerup J., Søeberg B., Sørensen S.F. Neutrophil and lymphocyte function in patients with diabetes mellitus. *Acta Med Scand*. 1982; 211 (6): 463-7. doi: 10.1111/j.0954-6820.1982.tb01983.x
7. Delamaire M., Maugeudre D., Moreno M., Le Goff M.C., Allannic H., Genetet B. Impaired leucocyte functions in diabetic patients. *Diabet Med*. 1997 Jan; 14 (1): 29-34. doi: 10.1002/(SICI)1096-9136(199701)
8. Huang T.T., Tseng F.Y., Liu T.C., Hsu C.J., Chen Y.S. Deep neck infection in diabetic patients: comparison of clinical picture and outcomes with nondiabetic patients. *Otolaryngol Head Neck Surg*. 2005 Jun; 132 (6): 943-7. doi: 10.1016/j.otohns.2005.01.035
9. Chen M.K., Wen Y.S., Chang C.C., Huang M.T., Hsiao H.C. Predisposing factors of life-threatening deep neck infection: logistic regression analysis of 214 cases. *J Otolaryngol*. 1998 Jun; 27 (3): 141-4.
10. Carey I.M., Critchley J.A., DeWilde S., Harris T., Hosking F.J., Cook D.G. Risk of

- Infection in Type 1 and Type 2 Diabetes Compared With the General Population: A Matched Cohort Study. *Diabetes care*. 2018; 41 (3): 513-21. doi: 10.2337/dc17-2131
11. Fullmer J.M., Scarfe W.C., Kushner G.M., Alpert B., Farman A.G. Cone beam computed tomographic findings in refractory chronic suppurative osteomyelitis of the mandible. *Br J Oral Maxillofac Surg*. 2007 Jul; 45 (5): 364-71. doi: 10.1016/j.bjoms.2006.10.009
 12. Julien Saint Amand M., Sigaux N., Gleizal A., Bouletreau P., Breton P. Chronic osteomyelitis of the mandible: A comparative study of 10 cases with primary chronic osteomyelitis and 12 cases with secondary chronic osteomyelitis. *J Stomatol Oral Maxillofac Surg*. 2017 Dec; 118 (6): 342-348. doi: 10.1016/j.jormas.2017.08.006
 13. Marschall J.S., Flint R.L., Kushner G.M., Alpert B. Management of Mandibular Osteomyelitis With Segmental Resection, Nerve Preservation, and Immediate Reconstruction. *J Oral Maxillofac Surg*. 2019 Jul; 77 (7): 1490-1504. doi: 10.1016/j.joms.2019.01.036
 14. Baur D.A., Altay M.A., Flores-Hidalgo A., Ort Y., Quereshy F.A. Chronic osteomyelitis of the mandible: diagnosis and management-an institution's experience over 7 years. *J Oral Maxillofac Surg*. 2015 Apr; 73 (4): 655-65. doi: 10.1016/j.joms.2014.10.017
 15. Sood R., Gamit M., Shah N., Mansuri Y., Naria G. Maxillofacial Osteomyelitis in Immunocompromised Patients: A Demographic Retrospective Study. *J Maxillofac Oral Surg*. 2020 Jun; 19 (2): 273-282. doi: 10.1007/s12663-019-01201-4
 16. Hannan C.M., Attinger C.E. Special considerations in the management of osteomyelitis defects (diabetes, the ischemic or dysvascular bed, and irradiation). *Semin Plast Surg*. 2009 May; 23 (2): 132-40. doi: 10.1055/s-0029-1214165
 17. Lin H.T., Tsai C.S., Chen Y.L., Liang J.G. Influence of diabetes mellitus on deep neck infection. *J Laryngol Otol*. 2006 Aug; 120 (8): 650-4. doi: 10.1017/S0022215106001149
 18. Cheng N.C., Tai H.C., Chang S.C., Chang C.H., Lai H.S. Necrotizing fasciitis in patients with diabetes mellitus: clinical characteristics and risk factors for mortality. *BMC Infect Dis*. 2015 Oct 13; 15: 417. doi: 10.1186/s12879-015-1144-0
 19. Yadav S., Malik S., Mittal H.C., Puri P. Chronic suppurative osteomyelitis of posterior maxilla: A rare presentation. *J Oral Maxillofac Pathol*. 2014 Sep-Dec; 18 (3): 481. doi: 10.4103/0973-029X.151364
 20. Ueta E., Osaki T., Yoneda K., Yamamoto T. Prevalence of diabetes mellitus in odontogenic infections and oral candidiasis: an analysis of neutrophil suppression. *J Oral Pathol Med*. 1993 Apr; 22 (4): 168-74. doi: 10.1111/j.1600-0714.1993.tb01051.x
 21. Kasperk C., Georgescu C., Nawroth P. Diabetes Mellitus and Bone Metabolism. *Exp Clin Endocrinol Diabetes*. 2017 Apr; 125 (4): 213-217. doi: 10.1055/s-0042-123036
 22. Giles A.J., Hutchinson M.N.D., Sonnemann H.M., Jung J., Fecci P.E., Ratnam N.M., Zhang W., Song H., Bailey R., Davis D., Reid C.M., Park D.M., Gilbert M.R. Dexamethasone-induced immunosuppression: mechanisms and implications for immunotherapy. *J Immunother Cancer*. 2018 Jun 11; 6 (1): 51. doi: 10.1186/s40425-018-0371-5
 23. Barshes N.R., Goodpastor S.E., Goss J.A. Pharmacologic immunosuppression. *Front Biosci*. 2004 Jan 1; 9: 411-20. doi: 10.2741/1249
 24. Perez A., Jansen-Chaparro S., Saigi I., Bernal-Lopez M.R., Miñambres I., Gomez-Huelgas R. Glucocorticoid-induced hyperglycemia. *J Diabetes*. 2014 Jan; 6 (1): 9-20. doi: 10.1111/1753-0407.12090