



CLINICAL RESEARCH:

Salivary Cytokine Profile in Patients with Oral Lichen Planus Perfil de citoquinas salivales en pacientes con liquen plano oral

Janaina Silva Martins Humberto PhD¹ <https://orcid.org/0000-0002-5677-9127>

Rafael Simone Saia PhD² <https://orcid.org/0000-0002-9771-7627>

Luis Henrique Angenendt Costa PhD² <https://orcid.org/0000-0003-3727-0410>

Maria José Alves Rocha PhD³ <https://orcid.org/0000-0002-5102-4550>

Ana Carolina Fragoso Motta PhD⁴ <https://orcid.org/0000-0002-3887-9239>

1. School of Dentistry of Amazonas, Federal University of Amazonas, Manaus, Brazil and School of Dentistry of Ribeirão Preto, University of São Paulo, Ribeirão Preto, Brazil.
2. Ribeirão Preto Medical School, University of São Paulo, Ribeirão Preto, Brazil.
3. School of Dentistry of Ribeirão Preto and Ribeirão Preto Medical School, University of São Paulo, Ribeirão Preto, Brazil.
4. School of Dentistry of Ribeirão Preto, University of São Paulo, Ribeirão Preto, Brazil.

Correspondence to: PhD. Ana Carolina Fragoso Motta - anacfm@usp.br

Received: 4-VII-2023

Accepted: 27-IX-2023

ABSTRACT: This study aimed to determine salivary concentrations of interleukin (IL)-1 β , IL-2, IL-10, IL-23, transforming growth factor (TGF)- β , tumor necrosis factor (TNF)- α , nitrate (a by-product of nitric oxide oxidation), and cortisol in patients with oral lichen planus (OLP). Twenty patients diagnosed with OLP and 20 sex-matched healthy volunteers (HV) were included in this cross-sectional study. Unstimulated whole saliva was collected in the morning. Salivary cytokine and cortisol concentrations were determined by enzyme-linked immunosorbent assays (ELISA). Nitrate was measured in a nitric oxide analyzer. We found higher salivary concentrations of IL-2 ($p < 0.003$), IL-23 ($p < 0.04$), and TGF- β ($p = 0.05$) in patients with OLP compared to HV. No significant differences were found in salivary levels of TNF- α , IL-1 β , or IL-10. Nitrate concentrations were markedly increased in OLP patients ($1,227.0 \pm 738.8 \mu\text{M}/\text{mg}$ total protein) when compared to HV ($261.6 \pm 166.8 \mu\text{M}/\text{mg}$; $p < 0.0001$). Salivary cortisol levels were also higher in OLP patients (2.79 ± 1.39 vs. $1.94 \pm 1.21 \text{ ng}/\text{mg}$; $p < 0.048$). The markedly increased salivary levels of nitric oxide in patients with OLP suggest a relationship of this molecule with the cell death and tissue damage observed in these lesions.



KEYWORDS: Oral lichen planus; Cytokines; Nitric oxide; Cortisol; Interleukin.

RESUMEN: Este estudio tuvo como objetivo determinar las concentraciones salivales de interleucina (IL)-1 β , IL-2, IL-10, IL-23, factor de crecimiento transformante (TGF)- β y factor de necrosis tumoral (TNF)- α , nitrato (subproducto de la oxidación del óxido nítrico) y cortisol en pacientes con liquen plano oral (OLP). En este estudio transversal se incluyeron veinte pacientes diagnosticados con OLP y 20 voluntarios sanos (HV) del mismo sexo. Saliva entera no estimulada Se recolectó por la mañana, se determinaron las concentraciones de citocinas y cortisol en saliva mediante ensayo inmunoabsorbente ligado a enzimas (ELISA), se determinó nitrato mediante un analizador de óxido nítrico, se encontraron concentraciones salivales mayores de IL-2 ($p < 0,003$), IL- 23 ($p < 0,04$) y TGF- β ($p = 0,05$) en pacientes con OLP en comparación con HV. No se encontraron diferencias significativas en los niveles salivales de TNF- α , IL-1 β e IL-10. Las concentraciones de nitrato fueron marcadamente aumentó en pacientes con OLP ($1227,0 \pm 738,8 \mu\text{M/mg}$ de proteína total), en comparación con HV ($261,6 \pm 166,8 \mu\text{M/mg}$; $p < 0,0001$). Los niveles de cortisol salival también fueron más altos en los pacientes con OLP que en los controles ($2,79 \pm 1,39$ vs. $1,94 \pm 1,21$ ng/mg; $p < 0,048$). Los niveles de óxido nítrico en saliva aumentaron notablemente en pacientes con OLP, lo que sugiere una relación de esta molécula con la muerte celular y el daño tisular observado en las lesiones de OLP.

PALABRAS CLAVE: Liquen plano oral; Citoquinas; Óxido nítrico; cortisol; Interleucina.

INTRODUCTION

Lichen planus is a chronic inflammatory mucocutaneous disease that affects the oral and genital mucous membranes, skin, nails, and scalp (1). Oral lesions, called oral lichen planus (OLP), are one of the most common inflammatory diseases of the oral mucosa, which are present in 30-70% of patients diagnosed with lichen planus (2). The global prevalence of OLP is 1.01% and there are marked geographical differences. The disease mainly affects middle-aged women, with a female-to-male ratio of 2:1 (1, 3, 4). Furthermore, Caucasians have a 5.5-fold higher risk of developing the disease than other ethnicities (5). Although the clinical recognition of OLP is relatively easy, its diagnosis and etiopathogenesis have been extensively debated

over the last decades and different aspects of the disease still need to be clarified (1, 5).

Dysregulation of the immune system plays a critical role in the pathogenesis of OLP and involves antigen-specific mechanisms that trigger the excessive production of inflammatory mediators both locally and in peripheral blood (6). The long-term activation of immune cells (T cells, macrophages, and mast cells) and the release of cytokines exert cytotoxic effects and induce cellular oxidative stress, events that are also common in other immune-mediated diseases such as sepsis, allergy, and inflammatory bowel disease. Characterization of the inflammatory profile in OLP is essential for identifying possible diagnostic biomarkers and therapeutic targets and for follow-up of the

lesions. It can also improve diagnostic accuracy when histopathological findings are shared by other oral diseases. Among the potential biomarkers for OLP, nitric oxide (NO), cytokines, and cortisol, which are easily detected in saliva, urine, and blood, have emerged as the best candidates (7).

We have previously demonstrated that the greater severity of OLP and of oral lichenoid lesions is apparently associated with increased levels of anxiety, higher oral health impact profile scores, and decreased quality of life, suggesting that psychological disturbances may be related to the course of these diseases. Based on these findings, we hypothesize that OLP patients will show overexpression of cortisol, inflammatory cytokines, and NO (8, 9). Therefore, the present study aimed to evaluate the salivary inflammatory profile in OLP patients in order to identify factors related to the exacerbation and perpetuation of oral lesions. These factors could be used as potential diagnostic tools and therapeutic targets in OLP.

PATIENTS AND METHODS

PATIENTS

Twenty patients with a clinical and histopathological diagnosis of OLP were recruited. The diagnosis was based on the modified World Health Organization diagnostic criteria proposed by van der Meij and van der Waal (10) and later re-evaluated by the American Academy of Oral and Maxillofacial Pathology (11). Patients diagnosed with any other type of lichenoid lesion were excluded from the study. Moreover, 20 age- and sex-matched healthy volunteers (HV) from the community of our Institution (School of Dentis-

try of Ribeirão Preto, University of São Paulo – FORP-USP, Ribeirão Preto, Brazil) were included as controls. The patients were selected consecutively by convenience sampling over the period from July 2015 to June 2016. None of these HV exhibited periodontal, systemic, or oral inflammatory diseases during clinical examination. Patients with OLP and HV were nonsmokers and none of them was on continuous medication. Table 1 shows the demographic and clinical characteristics of the subjects, including age, sex, ethnicity, and features of the lesion. The Research Ethics Committee of FORP-USP approved the study (CAAE: 33703114.8.0000.5419) and all patients gave informed consent to participate.

Table 1. Demographic characteristics of patients with oral lichen planus and healthy volunteers

	OLP (n = 20)	HV (n = 20)
Age (years), mean \pm SD	52 \pm 14	47 \pm 15
Sex (F/M)	14/6	11/9
Ethnicity (C/A)	18/2	19/1
Clinical form*	n (%)	
Reticular/papular/plaque	20 (100)	-
Erosive/erythematous	8 (27.6)	-
Ulcerative	1 (3.4)	-
Site of lesion*	n (%)	
Buccal mucosa	14 (39.1)	-
Tongue	5 (30.5)	-
Gingiva	8 (26.1)	-
Lip	3 (4.3)	-
Time since disease diagnosis	n (%)	
>1 year	12 (60)	-
<1 year	8 (40)	-

OLP: oral lichen planus; HV: healthy volunteers; F: female; M: male. Age is reported as the mean \pm SD. C: Caucasian; A: African American. *Patients with multiple lesions.

STUDY DESIGN AND SAMPLE COLLECTION

This is an observational, cross-sectional study with two study groups, OLP patients and HV. The study was designed following the Strengthening the Reporting of Observational Studies in Epidemiology (STROBE) statement (12). Unstimulated whole saliva was obtained using a standard technique (13). Samples were collected at the participants' homes 30 minutes after waking up to minimize bias that can result from the circadian cortisol peak. The patients were instructed not to eat or drink and not to brush their teeth prior to saliva collection to minimize the risk of contamination with blood or food particles. One saliva sample was collected from each patient with OLP or HV. The samples were kept on ice, transported to the laboratory, and immediately centrifuged (4500 rpm for 30 min at 4°C). The supernatant was aliquoted and stored at -80°C until further use.

MEASUREMENTS OF CYTOKINES AND CORTISOL

Salivary concentrations of tumor necrosis factor-alpha (TNF- α), interleukins (IL)-1 β , IL-2, IL-10 and IL-23, and transforming growth factor-beta (TGF- β) were determined using enzyme-linked immunosorbent assay (ELISA) kits (eBioscience Incorporation, San Diego, CA, USA and R&D Systems, Minneapolis, MN, USA) according to the manufacturer's instructions. Salivary cortisol was quantified using a commercial ELISA kit (Salimetrics, State College, PA, USA). All results were normalized to total protein concentration, which was measured using the bicinchoninic acid (BCA) assay (Thermo Fisher Scientific, Rockford, IL, USA).

NITRATE QUANTIFICATION

Nitrate was quantified using the purge system of the Sievers Instruments Nitric Oxide Analyzer (NOA model 280i, Boulder, CO, USA). Salivary samples were deproteinized with cold

absolute ethanol (25 μ L of saliva from each sample was mixed with 50 μ L ethanol), kept at -20°C for 24 h, and centrifuged to precipitate the proteins. Next, 5 μ L of the diluted supernatant was mixed with the reaction medium containing a reducing agent (0.8% vanadium chloride in 1 N HCl at 95 °C), which converts nitrate to equimolar amounts of NO. The NO produced was detected by ozone-induced chemiluminescence. Peak NO of the samples was measured using a standard curve constructed with different concentrations of a sodium nitrate solution (5, 10, 25, 50, and 100 μ M). The salivary nitrate levels were also normalized to total protein concentration using the BCA method.

STATISTICAL ANALYSIS

Values are expressed as mean \pm standard deviation (SD). All samples were measured in the same session to avoid interassay variation. The sample volume of some OLP patients was insufficient for all measurements; thus, priority was given to the measurement of cortisol and nitrate. Data were compared using a two-tailed nonparametric Mann-Whitney U test, with confidence intervals of 95%. The GraphPad Prism 5.0 software was employed for statistical analysis. For all tests, statistical significance was set at $p \leq 0.05$.

RESULTS

CHARACTERISTICS OF PATIENTS

The incidence of OLP was 2.33 times higher in women than men (14 female patients among the 20 subjects) (Table 1). The median age was 54 years in OLP patients and 47 years in the HV group. With respect to the clinical form of the disease, all patients had the reticular form (100%) and the atrophic form was the second most frequent lesion (28.6%). Few patients simultaneously had other types of lesions (erosive, plaque, ulcerous, and bullous) in addition to the reticular form. The main site of the lesions was the cheek (39.1%);

however, there was also frequent involvement of the tongue (30.5%) and gingiva (26.1%) (Table 1). Most OLP patients (60%) reported that the disease was first diagnosed more than 1 year prior to sample collection.

SALIVARY CYTOKINE LEVELS IN OLP PATIENTS

Salivary concentrations of two proinflammatory cytokines, IL-2 (36.5 ± 30.3 vs. 13.4 ± 28.5 pg/mg total protein; $p < 0.003$) and IL-23 (289.50 ± 195.0 vs. 160.2 ± 140.4 pg/mg total protein; $p < 0.04$), were significantly higher in patients with OLP compared to HV (Figure 1.A and Figure 1.D). Salivary levels of the anti-inflammatory cytokine TGF- β were also significantly higher in OLP patients (3.22 ± 2.22 vs. 5.95 ± 4.53 ng/mg total protein; $p < 0.05$; Figure 1.F), but no differences were found for TNF- α , IL-1 β , or IL-10 (Figure 1.A,

Figure 1.B, and Figure 1.E). There were no differences in cytokine levels between the subgroups of patients with exclusive reticular OLP and reticular + erosive OLP (data not shown).

SALIVARY LEVELS OF NITRATE AND CORTISOL IN OLP PATIENTS

Salivary concentrations of nitrate, the stable metabolite of NO oxidation, were markedly increased in OLP patients ($1,227.0 \pm 738.8$ μ M/mg total protein) when compared to HV (261.6 ± 166.8 μ M/mg total protein; $p < 0.0001$; Figure 2.A). Salivary cortisol was also increased in patients with OLP (2.79 ± 1.39 vs. 1.94 ± 1.21 ng/mg total protein; $p < 0.048$; Figure 2.B). As observed for the cytokines, no differences in nitrate or cortisol levels were found when subgroups of the clinical forms were compared (data not shown).

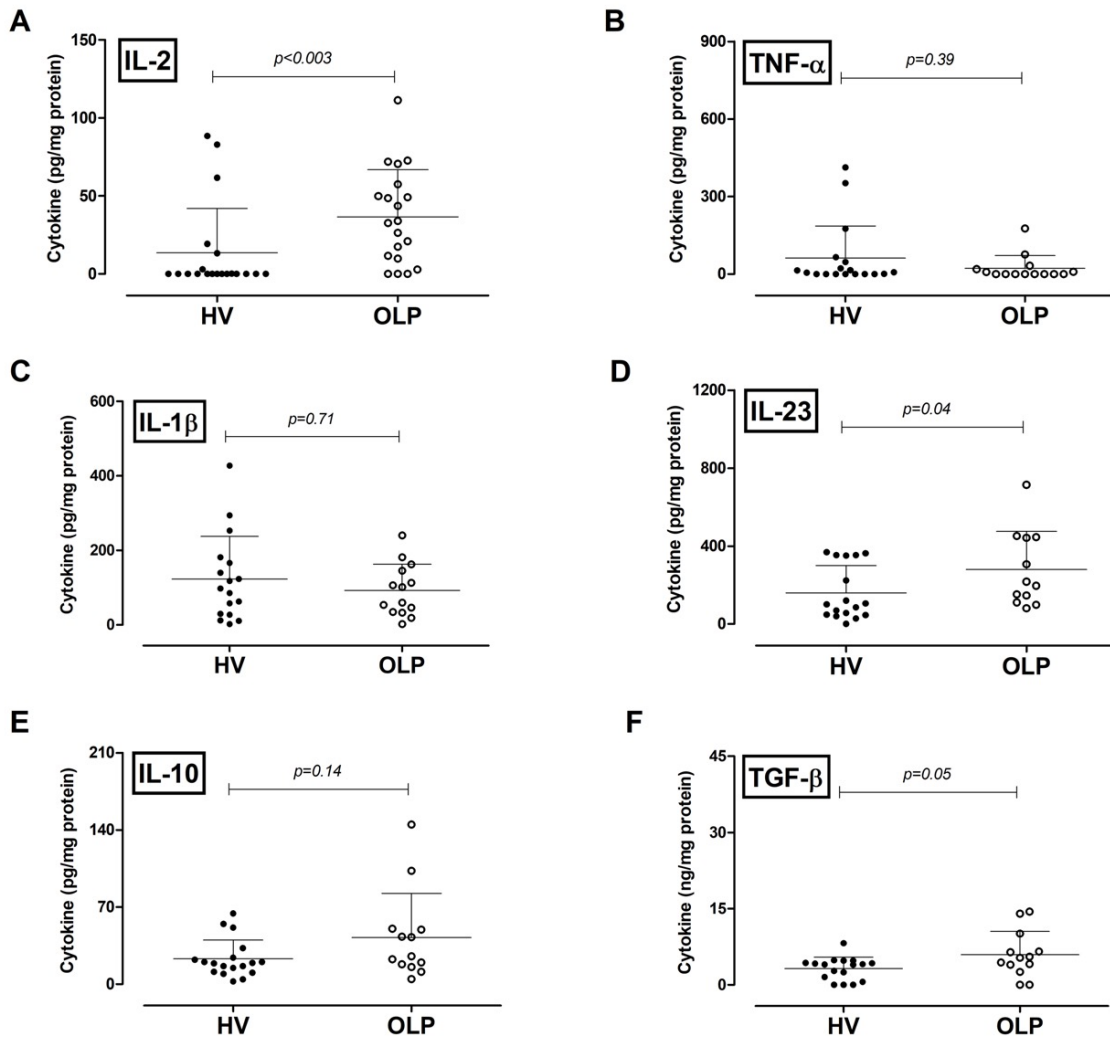


Figure 1. Salivary inflammatory profile in patients with oral lichen planus (OLP) and healthy volunteers (HV): (A) interleukin (IL)-2, (B) tumor necrosis factor (TNF)- α , (C) IL-1 β , (D) IL-23, (E) IL-10, and (F) transforming growth factor (TGF)- β . Data are expressed as mean \pm standard deviation (the horizontal bar represents the mean). Statistical difference between the two groups was assessed by a two-tailed Mann-Whitney U test.

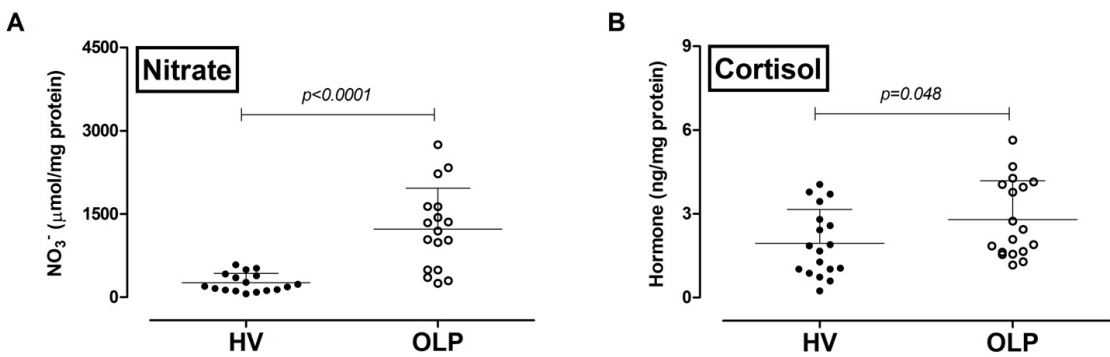


Figure 2. Salivary concentration of nitrate and cortisol in patients with oral lichen planus (OLP) and healthy volunteers (HV): (A) nitrate and (B) cortisol. Data are expressed as mean \pm SD (the horizontal bar represents the mean). Statistical difference between the two groups was assessed by a two-tailed Mann-Whitney U test.

DISCUSSION

Oral lichen planus is one of the most common immune-mediated inflammatory disease of the oral mucosa. The condition is characterized by intense inflammatory cell infiltration and aberrant epithelial keratinization and mainly affects the buccal mucosa, gingiva, and tongue. Regarding the intriguing pathogenesis of OLP, CD8+ T cells were found to be the predominant cells in the subepithelial area (14). Activated CD8+ T cells are of special interest in the disease since they possibly trigger keratinocyte apoptosis (15). Antigens may bind to major histocompatibility complex (MHC) class I molecules on keratinocytes, promoting T-cell activation and clone expansion that result in the release of cytokines, especially IL-2, IFN- γ , and TNF- α , which further perpetuate the activation of these T cells (16). The continuous release of inflammatory mediators then attracts additional immune cells and enhances lymphocyte activity, keeping up the production of cytokines not only by these cells but also by immunocompetent keratinocytes and mast cells. This complex immune network in the oral mucosa is involved in the development of OLP lesions and chronicity (15, 16).

The assessment of the inflammatory profile in OLP patients using noninvasive techniques may serve as a diagnostic tool to monitor disease activity and the response to therapeutic interventions. In the present study, salivary concentrations of six cytokines were investigated, four proinflammatory (TNF- α , IL-1 β , IL-2, IL-23) and two anti-inflammatory (TGF- β and IL-10) cytokines. Both IL-2 and IL-23 levels were increased in OLP patients when compared to HV, but no differences were observed in TNF- α , IL-1 β , or IL-10 levels. These pro- and anti-inflammatory cytokines detected in the saliva of OLP patients may be involved in the clinical progression of the disease. TNF- α and IL-1 β are two important proinflammatory cytokines that are produced by a wide range of cell types. In contrast to our findings, Ghallab and colleagues found

increased salivary levels of TNF- α in a population composed exclusively of patients with the erosive form of OLP (17). Furthermore, studies suggested the local production of cytokines (TNF- α and IL-6) to be positively correlated with the subtype of OLP, the severity of the lesions, and the risk of malignant transformation/dysplasia (18). The heterogeneity of these clinical findings was addressed in a meta-analysis that examined serum and salivary concentrations of TNF- α in OLP patients (19).

Conversely, IL-1 β is a poorly investigated cytokine in OLP. This cytokine is produced by basal keratinocytes and infiltrated mononuclear cells in OLP lesions (20). Elevated IL-1 β concentrations have been reported in unstimulated whole saliva of OLP patients (21). This cytokine may stimulate other cells in the mucosa, such as keratinocytes, to produce more TNF- α and IL-6, as well as granulocyte-macrophage colony-stimulating factor (GM-CSF) (20). Two important factors may explain the divergence between our findings and previous studies. In our study, all patients had the reticular form of OLP. This form is considered a less severe type of the disease and is characterized by lower levels of salivary cytokines compared to other types. Moreover, TNF- α and IL-1 β are produced during acute inflammation, while most of our patients were in the chronic phase of OLP (60% were first diagnosed more than 1 year earlier).

IL-2 is a cytokine produced in response to pathogen infection, especially by T cells, B cells, and natural killer cells. This cytokine stimulates T-cell activation and clonal expansion after antigen recognition and participates in the differentiation of T cells into cytotoxic cells (6). The IL-2/IL-2 receptor system is expressed by infiltrated T cells in OLP lesions and this complex is known to stimulate the synthesis of IL-6 by mononuclear cells *in vitro* (20, 22). However, although IL-2 promotes the expansion of CD8+ T cells and is responsible for maintaining the inflammatory response in the oral mucosa, its role in OLP is still unclear. In peripheral

blood, the results are controversial, with studies showing either increased or reduced IL-2 levels in populations of OLP patients that mainly have the reticular form of OLP (23). So far, only one study has evaluated salivary IL-2 levels in OLP patients and found no difference in IL-2 concentrations between HV and OLP patients (24). In contrast, we detected increased salivary IL-2, which we believe to be related to the Th1-dominant cytokine environment commonly observed in this disease. These are novel findings that may be associated with chronic lymphocytic activation.

IL-23 is a member of the IL-12 family that is secreted by different cell types, including dendritic cells, activated macrophages, and epithelial cells, and is implicated in several autoimmune inflammatory disorders such as colitis, psoriasis, and arthritis (25). IL-23 induces the proliferation of IL-17-secreting CD4+ T cells which, in turn, stimulate the release of IL-1, IL-6, NO, and chemokines involved in inflammation (26). Biopsies of OLP lesions revealed elevated IL-23 mRNA levels and expression of IL-23p19 in the epithelial and subepithelial layers (27). Furthermore, IL-23 is upregulated in both the reticular and erosive forms of OLP and a positive correlation of IL-23 with IL-17 gene expression and IL-17+-cells has been observed in the former (27). In contrast to previous findings (28), our results showed for the first time increased IL-23 production in the saliva of OLP patients. These data are also novel and may be related to the progression of the disease and lesion persistence due to continuous infiltration of T cells into the local mucosa via an IL-17-dependent mechanism.

TGF- β and IL-10 are important immunosuppressive cytokines. TGF- β has anti-inflammatory properties and exerts various effects on many immune and other target cells (6), regulating cell differentiation, proliferation, and apoptosis. This cytokine inhibits the growth and promotes the differentiation and apoptosis of keratinocytes in

vitro, and induces expression of the IL-23/IL-23 receptor (29). Studies suggest that the chronicity of OLP may in part be due to the inefficient action of TGF- β as a result of the insufficient secretion of the cytokine by Th3 lymphocytes, block of its action (due to overproduction of IFN- γ and phosphorylation of Smad3), or diminished expression of TGF- β 1 receptors. TGF- β also induces epithelial-mesenchymal transition and probably plays a role in the malignant transformation of OLP (30).

Biopsies from OLP patients have been used to detect cytokines in tissue sections and cells expressing IL-10 and TGF- β mRNA were found in the subepithelial infiltrate (22). IL-10 is mainly produced by macrophages and Th2 cells and its reported biological activity involves the balance of Th1/Th2 responses by downregulating the Th1 and upregulating the Th2 response. The downregulation of Th1 results in the suppression of proinflammatory cytokines produced by macrophages and regulatory T cells, including IFN- γ , TNF- α , IL-2, IL-3, and IL-4. The upregulation of Th2 leads to elevated antibody production. However, IL-10 is also known to suppress antigen presentation on antigen-presenting cells and to enhance B-cell survival and proliferation (36).

Our results demonstrated a slight increase in salivary TGF- β concentrations but no changes in IL-10 levels. However, the pattern of production of these cytokines is still controversial in the literature. In peripheral blood, augmented levels of IL-10 and TGF- β were observed in a group of patients who predominantly exhibited the erosive type of OLP, suggesting that the plasma levels of these cytokines could be a useful marker for this disease (31). Conversely, reduced IL-10 production was also reported in serum of OLP patients (32). Similar results were found in saliva, with two studies showing increased IL-10 and TGF- β levels in OLP (24, 33). These divergent findings may be due to differences in the clinical form of the disease, sample size, age, sex distribution,

or methods for cytokine measurement among studies. Thus, it has been suggested that IL-10 is not a good marker for OLP (33), and there is a need for further studies to clarify these controversial findings.

Nitric oxide belongs to a class of molecular messengers that control different biological functions. NO is a highly reactive gaseous free radical produced by the enzyme NO synthase (NOS). The two constitutive isoforms of NOS, neuronal (nNOS) and endothelial (eNOS), act as a neurotransmitter and a vasodilator, respectively (34). The inducible isoform (iNOS) may also be expressed constitutively in some cell types, but generally requires exposure to inflammatory stimuli such as lipopolysaccharide, TNF- α , or IFN- γ (35). iNOS is able to synthesize large quantities of NO (almost 1000-fold higher than those produced by the constitutive NOS) and for long periods until its proteolytic degradation (36). The mRNA and protein levels of eNOS and iNOS in mucosa are increased in some pathological conditions, including OLP. The same is observed for nitrate and nitrite, which are the products (and stable metabolites) of NO inactivation and its reaction with oxygen (37). In agreement with the literature, our results showed a 6-fold increase in salivary nitrate concentrations in OLP patients. This finding strongly suggests that the sustained release of iNOS-derived NO, whose expression is upregulated by proinflammatory cytokines such as IL-23, IL-1 β , and TNF- α , may lead to cell death and tissue damage (38). Moreover, NO exerts cytotoxic effects in keratinocytes, fibroblasts, and oral epithelial cells in vitro, suggesting that this free radical may be associated with the severity of the clinical form of OLP and with the development of erosive and/or ulcerative lesions (38).

An interaction between the neural and immune systems may also play a role in the development and persistence of OLP. In patients with this disease, the onset and chronicity of oral

symptoms can cause psychological stress and decreased quality of life due to the chronicity and recurrence of oral lesions (39). Our research group has previously demonstrated a positive association between the severity of OLP lesions and angiogenic behavior (9). Studies reported salivary cortisol and anxiety to be promising parameters in the investigation of OLP (40). Within this context, our results showed that increased salivary cortisol concentrations (suggesting activation of the hypothalamus-pituitary-adrenal axis) and psychological stress were associated with OLP. However, data on salivary cortisol levels in OLP (whether increased or no different from HV) are still controversial (8).

The major strength of the present study was the samples collection schedule, i.e., 30 minutes after waking up to avoid circadian variations of the analytes, especially cortisol. We also did not include patients with periodontal diseases in order to prevent blood contamination from gingival lesions and any interference of periodontal inflammation. The study has some limitations, including the fact that OLP patients were recruited at a single center and the small sample size. Thus, further longitudinal controlled clinical trials with larger populations are needed. Despite these limitations, our study reports important findings regarding the salivary inflammatory profile in OLP, which is characterized by increased levels of IL-2, IL-23, TGF- β , cortisol, and NO. Among the eight potential biomarkers investigated, the largest difference between OLP patients and HV was found for NO levels. This result suggests that NO might participate in the pathogenesis of OLP mainly by causing cell death and tissue damage, but the exact mechanism needs further investigation.

CONCLUSION

Our results suggest that NO is a good marker for the diagnosis and severity of OLP and might be a therapeutic target in the disease. In

addition, considering that NO and stress share similar molecular pathways, a correlation of high levels of NO and cortisol with stress in OLP cannot be ruled out. Based on these results, the evaluation of inflammatory markers in saliva is a valuable non-invasive tool for efficient monitoring of disease activity in OLP patients.

CONFLICT OF INTEREST

The authors have no commercial or proprietary interest in any concept or product described in this article.

FUNDING

This study was supported by the São Paulo Research Foundation-FAPESP (Grants 2013/15214-6, 2014/11883-3, and 2015/22183-5).

ETHICAL APPROVAL

The Ethics Committee of FORP-USP approved the study (CAAE: 33703114.8.0000.5419) and all participants gave informed consent.

AVAILABILITY OF DATA AND MATERIALS

All data generated or analyzed during this study are included in this published article.

AUTHOR CONTRIBUTION STATEMENT

Conception and design: J.S.M.H., A.C.F.M. and M.J.A.R.

Execution of experiments and data analysis, J.S.M.H., R.S.S and L.H.A.C.

Original draft preparation and revision of the manuscript: J.S.M.H., R.S.S., M.J.A.R and A.C.F.M.

Acquisition of funding: A.C.F.M. and R.S.S.

All authors revised and approved the submitted version of the manuscript.

ACKNOWLEDGMENT

The authors would like to thank Dr. José Antunes Rodrigues from the Ribeirão Preto Medical School for granting access to the nitric oxide analyzer. We also thank Dr. Milene Mantovani for technical assistance. We are grateful to all patients who volunteered to participate in the study.

REFERENCES

1. Au J., Patel D., Campbell J.H. Oral lichen planus. *Oral Maxillofac Surg Clin North Am.* 2013; 25 (1): 93-100, vii. DOI: 10.1016/j.coms.2012.11.007
2. Arisawa E.A., Almeida J.D., Carvalho Y.R., Cabral L.A. Clinicopathological analysis of oral mucous autoimmune disease: A 27-year study. *Med Oral Patol Oral Cir Bucal.* 2008; 13 (2): E94-7.
3. Lodi G., Scully C., Carrozzo M., Griffiths M., Sugerman P.B., Thongprasom K. Current controversies in oral lichen planus: report of an international consensus meeting. Part 2. Clinical management and malignant transformation. *Oral Surg Oral Med Oral Pathol Oral Radiol Endod.* 2005; 100 (2): 164-78. DOI: 10.1016/j.tripleo.2004.06.076
4. Gonzalez-Moles M.A., Warnakulasuriya S., Gonzalez-Ruiz I., Gonzalez-Ruiz L., Ayen A., Lenouvel D., et al. Worldwide prevalence of oral lichen planus: A systematic review and meta-analysis. *Oral Dis.* 2021; 27 (4): 813-28. DOI: 10.1111/odi.13323
5. Ingafou M., Leao J.C., Porter S.R., Scully C. Oral lichen planus: a retrospective study of 690 British patients. *Oral Dis.* 2006; 12 (5): 463-8. DOI: 10.1111/j.1601-0825.2005.01221.x
6. Lu R., Zhang J., Sun W., Du G., Zhou G. Inflammation-related cytokines in oral lichen planus: an overview. *J Oral Pathol Med.* 2015; 44 (1): 1-14. DOI: 10.1111/jop.12142

7. Humberto J.S.M., Pavanin J.V., Rocha M., Motta A.C.F. Cytokines, cortisol, and nitric oxide as salivary biomarkers in oral lichen planus: a systematic review. *Braz Oral Res.* 2018; 32: e82. DOI: 10.1590/1807-3107bor-2018.vol32.0082
8. Nadendla L.K., Meduri V., Paramkusam G., Pachava K.R. Association of salivary cortisol and anxiety levels in lichen planus patients. *J Clin Diagn Res.* 2014; 8 (12): ZC01-3. DOI: 10.7860/JCDR/2014/8058.5225
9. Zucoloto M.L., Shibakura M.E.W., Pavanin J.V., Garcia F.T., da Silva Santos P.S., Maciel A.P., et al. Severity of oral lichen planus and oral lichenoid lesions is associated with anxiety. *Clin Oral Investig.* 2019; 23 (12): 4441-8. DOI: 10.1007/s00784-019-02892-2
10. van der Meij E.H., van der Waal I. Lack of clinicopathologic correlation in the diagnosis of oral lichen planus based on the presently available diagnostic criteria and suggestions for modifications. *J Oral Pathol Med.* 2003; 32 (9): 507-12. DOI: 10.1034/j.1600-0714.2003.00125.x
11. Cheng Y.S., Gould A., Kurago Z., Fantasia J., Muller S. Diagnosis of oral lichen planus: a position paper of the American Academy of Oral and Maxillofacial Pathology. *Oral Surg Oral Med Oral Pathol Oral Radiol.* 2016; 122 (3): 332-54. DOI: 10.1016/j.oooo.2016.05.004
12. von Elm E., Altman D.G., Egger M., Pocock S.J., Gotsche P.C., Vandenbroucke J.P., et al. The Strengthening the Reporting of Observational Studies in Epidemiology (STROBE) statement: guidelines for reporting observational studies. *PLoS Med.* 2007; 4 (10):e296. DOI: 10.1371/journal.pmed.0040296
13. Navazesh M. Methods for collecting saliva. *Ann N Y Acad Sci.* 1993; 694: 72-7. DOI: 10.1111/j.1749-6632.1993.tb18343.x
14. Sugarman P.B., Satterwhite K., Bigby M. Autocytotoxic T-cell clones in lichen planus. *Br J Dermatol.* 2000; 142 (3): 449-56. DOI: 10.1046/j.1365-2133.2000.03355.x
15. Scully C., Beyli M., Ferreiro M.C., Ficarra G., Gill Y., Griffiths M., et al. Update on oral lichen planus: etiopathogenesis and management. *Crit Rev Oral Biol Med.* 1998; 9 (1): 86-122. DOI: 10.1177/10454411980090010501
16. Payeras M.R., Cherubini K., Figueiredo M.A., Salum F.G. Oral lichen planus: focus on etiopathogenesis. *Arch Oral Biol.* 2013; 58 (9): 1057-69. DOI: 10.1016/j.archoral-bio.2013.04.004
17. Ghallab N.A., el-Wakeel N., Shaker O.G. Levels of salivary IFN-gamma, TNF-alfa, and TNF receptor-2 as prognostic markers in (erosive) oral lichen planus. *Mediators Inflamm.* 2010; 2010: 847632. DOI: 10.1155/2010/847632
18. Rhodus N.L., Cheng B., Myers S., Miller L., Ho V., Ondrey F. The feasibility of monitoring NF-kappaB associated cytokines: TNF-alpha, IL-1alpha, IL-6, and IL-8 in whole saliva for the malignant transformation of oral lichen planus. *Mol Carcinog.* 2005; 44 (2): 77-82. DOI: 10.1002/mc.20113
19. Mozaffari H.R., Ramezani M., Mahmoudia-hmadabadi M., Omidpanah N., Sadeghi M. Salivary and serum levels of tumor necrosis factor-alpha in oral lichen planus: a systematic review and meta-analysis study. *Oral Surg Oral Med Oral Pathol Oral Radiol.* 2017; 124 (3): e183-e9. DOI: 10.1016/j.oooo.2017.06.117
20. Yamamoto T., Osaki T. Characteristic cytokines generated by keratinocytes and mononuclear infiltrates in oral lichen planus. *J Invest Dermatol.* 1995; 104 (5): 784-8. DOI: 10.1111/1523-1747.ep12606990
21. Zhu Z.D., Ren X.M., Zhou M.M., Chen Q.M., Hua H., Li C.L. Salivary cytokine profile in patients with oral lichen planus. *J Dent Sci.* 2022; 17 (1): 100-5. DOI: 10.1016/j.jds.2021.06.013

22. Simark-Mattsson C., Bergenholtz G., Jontell M., Eklund C., Seymour G.J., Sugerman P.B., et al. Distribution of interleukin-2, -4, -10, tumour necrosis factor-alpha and transforming growth factor-beta mRNAs in oral lichen planus. *Arch Oral Biol.* 1999; 44 (6): 499-507. DOI: 10.1016/s0003-9969(99)00013-8
23. Hu J.Y., Zhang J., Cui J.L., Liang X.Y., Lu R., Du G.F., et al. Increasing CCL5/CCR5 on CD4+ T cells in peripheral blood of oral lichen planus. *Cytokine.* 2013; 62 (1): 141-5. DOI: 10.1016/j.cyto.2013.01.020
24. Wei W., Sun Q., Deng Y., Wang Y., Du G., Song C., et al. Mixed and inhomogeneous expression profile of Th1/Th2 related cytokines detected by cytometric bead array in the saliva of patients with oral lichen planus. *Oral Surg Oral Med Oral Pathol Oral Radiol.* 2018; 126 (2): 142-51. DOI: 10.1016/j.oooo.2018.02.013
25. Han G., Li F., Singh T.P., Wolf P., Wang X.J. The pro-inflammatory role of TGFbeta1: a paradox? *Int J Biol Sci.* 2012; 8 (2): 228-35. DOI: 10.7150/ijbs.8.228
26. Iwakura Y., Ishigame H. The IL-23/IL-17 axis in inflammation. *J Clin Invest.* 2006; 116 (5): 1218-22. DOI: 10.1172/JCI28508
27. Lu R., Zeng X., Han Q., Lin M., Long L., Dan H., et al. Overexpression and selectively regulatory roles of IL-23/IL-17 axis in the lesions of oral lichen planus. *Mediators of inflammation.* 2014; 2014: 701094. DOI: 10.1155/2014/701094
28. Wang H., Luo Z., Lei L., Sun Z., Zhou M., Dan H., et al. Interaction between oral lichen planus and chronic periodontitis with Th17-associated cytokines in serum. *Inflammation.* 2013; 36 (3): 696-704. DOI: 10.1007/s10753-013-9594-2
29. Morishima N., Mizoguchi I., Takeda K., Mizuguchi J., Yoshimoto T. TGF-beta is necessary for induction of IL-23R and Th17 differentiation by IL-6 and IL-23. *Biochem Biophys Res Commun.* 2009; 386 (1): 105-10. DOI: 10.1016/j.bbrc.2009.05.140
30. Akhurst R.J., Hata A. Targeting the TGFbeta signalling pathway in disease. *Nat Rev Drug Discov.* 2012; 11 (10): 790-811. DOI: 10.1038/nrd3810
31. Pekiner F.N., Demirel G.Y., Borahan M.O., Ozbayrak S. Cytokine profiles in serum of patients with oral lichen planus. *Cytokine.* 2012; 60 (3): 701-6. DOI: 10.1016/j.cyto.2012.08.007
32. Zhou G., Zhang J., Ren X.W., Hu J.Y., Du G.F., Xu X.Y. Increased B7-H1 expression on peripheral blood T cells in oral lichen planus correlated with disease severity. *J Clin Immunol.* 2012; 32 (4): 794-801. DOI: 10.1007/s10875-012-9683-2
33. Abdelwhab A., Kandeel M.M., Yassin H.H., Abdelmonem W., Shaker O.G. Evaluation of serum and salivary transforming growth factor beta, vascular endothelial growth factor and tumor necrosis factor alpha in oral lichen planus. *J Oral Res.* 2020; 9 (2): 86-92. DOI: <https://doi.org/10.17126/joralres.2020.012>

34. Daff S. NO synthase: structures and mechanisms. *Nitric Oxide*. 2010; 23 (1): 1-11. DOI: 10.1016/j.niox.2010.03.001
35. Pacher P., Beckman J.S., Liaudet L. Nitric oxide and peroxynitrite in health and disease. *Physiol Rev*. 2007; 87 (1): 315-424. DOI: 10.1152/physrev.00029.2006
36. Pautz A., Art J., Hahn S., Nowag S., Voss C., Kleinert H. Regulation of the expression of inducible nitric oxide synthase. *Nitric Oxide*. 2010; 23 (2): 75-93. DOI: 10.1016/j.niox.2010.04.007
37. Tvarijonaviciute A., Aznar-Cayuela C., Rubio C.P., Ceron J.J., Lopez-Jornet P. Evaluation of salivary oxidate stress biomarkers, nitric oxide and C-reactive protein in patients with oral lichen planus and burning mouth syndrome. *J Oral Pathol Med*. 2017; 46 (5): 387-92. DOI: 10.1111/jop.12522
38. Ohashi M., Iwase M., Nagumo M. Elevated production of salivary nitric oxide in oral mucosal diseases. *J Oral Pathol Med*. 1999; 28 (8): 355-9. DOI: 10.1111/j.1600-0714.1999.tb02053.x
39. Koray M., Dulger O., Ak G., Horasanli S., Uçok A., Tanyeri H., et al. The evaluation of anxiety and salivary cortisol levels in patients with oral lichen planus. *Oral Dis*. 2003; 9 (6): 298-301. DOI: 10.1034/j.1601-0825.2003.00960.x
40. Shah B., Ashok L., Sujatha G.P. Evaluation of salivary cortisol and psychological factors in patients with oral lichen planus. *Indian J Dent Res*. 2009; 20 (3): 288-92. DOI: 10.4103/0970-9290.57361