



CLINICAL RESEARCH:

Comparative Analysis of the Discrepancy in Conventional Cephalometric Tracing and Digital Cephalometric Tracing with Planmeca Romexis® Software

Análisis comparativo de la discrepancia en trazado cefalométrico convencional y trazado cefalométrico digital con el software Planmeca Romexis®

Pamela Chinchilla Torres DDS¹ <https://orcid.org/0009-0006-1562-1506>

María José Rodríguez Pacheco DDS, MSc² <https://orcid.org/0000-0003-2176-4432>

Ramón Chinchilla Herrera DDS, MSc² <https://orcid.org/0009-0004-2703-4806>

¹General dentist. San José, Costa Rica.

²Dentist specialized in Orthodontics. San José, Costa Rica.

Correspondence to: Dr. Pamela Chinchilla Torres – pamelachinchillatorres@outlook.com

Received: 8-VII-2023

Accepted: 29-XI-2023

ABSTRACT: The objective of this study was to compare the discrepancy in conventional cephalometric tracing and digital cephalometric tracing in lateral skull radiographs, with 3 angular and 3 linear measurements. We used 24 digital lateral skull radiographs of patients from the Universidad Latina de Costa Rica, taken with the Kodak 8000C Digital Panoramic and Cephalometric System, for the computerized tracing the radiographs were passed directly to the Planmeca Romexis® software, and the same radiographs were printed for the manual tracing. A comparison between the manual tracing and the Planmeca Romexis® software measurements showed statistically significant differences ($p < 0,05$) of 4 measurements between the two systems. It is evident that the cephalometric tracing with the Planmeca Romexis® software is more reliable than the manual tracing due to the data obtained in this research.

KEYWORDS: Digital radiography; Cephalometry; Anatomic landmarks; Digital technology; Software; Diagnostic errors.



RESUMEN: El objetivo de este estudio fue comparar la discrepancia en trazado cefalométrico convencional y trazado cefalométrico digital en radiografías laterales de cráneo, con 3 mediciones angulares y 3 lineales. Se utilizaron 24 radiografías digitales de lateral de cráneo de pacientes de la Universidad Latina de Costa Rica, tomadas con el aparato Kodak 8000C Digital Panoramic and Cephalometric System, para el trazado computarizado se pasó directamente la radiografía al software Planmeca Romexis®, las mismas radiografías fueron impresas para el trazado manual. A la comparación entre el trazado realizado manualmente y las medidas del programa Planmeza Romexis® se encontraron diferencias estadísticamente significativas ($p < 0,05$) de 4 mediciones entre los dos sistemas. Se evidencia que el trazado cefalométrico con el software Planmeca Romexis® es más confiable que el trazado manual por los datos arrojados en esta investigación.

PALABRAS CLAVE: Radiografía digital; Cefalometría; Puntos anatómicos de referencia; Tecnología digital; Software; Errores diagnósticos.

INTRODUCTION

Cephalometry arises from anthropometry and craniometry.

The term Cephalometry, which comes from the Greek words "Kephale", meaning head and "metron", which means measure, is a set of procedures for measuring the head, and describing and quantifying the structures involved in malocclusion, such as bones, teeth and soft tissues (1).

The principle of cephalometric analysis is to compare the patient with a normal reference group in order to detect any differences between the patient's dentofacial relationships and those that would be expected in his or her ethnic or racial group (2).

In this way, the horizontal and vertical relationships of the five functional components of the face are studied: the skull, the cranial base, maxilla, mandible, dentition and the upper and lower alveolar processes, to obtain a description

of the relationships. In addition, it also studies craniofacial growth patterns, assesses dentofacial proportions, deciphers anatomical bases of malocclusion and predicts the changes that the patient will experience (3).

On November 8, 1895, Professor Wilhelm Conrad Roentgen accidentally discovered X-rays. This discovery initiated the development of orthodontic measurement methods: cephalometric radiography. A great advantage of this study is that it allowed the craniometric measurement of living individuals, so that their growth and development could be studied. It was also possible to observe the bony structures through the soft tissues that cover them so that their relationship could be studied (4).

Holly Broadbent in 1931 introduced the technique of cephalometric radiography, with the purpose of obtaining angular and linear measurements. These measurements have been studied in order to obtain figures that serve as a parameter of normality for the diagnosis of dento-maxillary anomalies.

From these discoveries, different cephalometric analyses began to be developed, each time more complete and nowadays essential. Steiner, Ricketts, Downs, are a few of these (4).

Cephalometric radiographs are two-dimensional images that represent a three-dimensional structure. They are used to evaluate the relationship of the teeth to the jaws, and of the jaws to the rest of the facial skeleton (5). Several components such as an X-ray source, an adjustable cephalostat, a radiographic film holder with intensifying screens and a holder for the holder are essential to obtain it (5).

Rino *et al.* (6) point out that some factors that may impair the image are radiographic distortion, radiographic magnification, and errors in the delimitation of points and cephalometric measurements.

Cephalometric tracing is performed manually, with acetate paper, which is placed on the lateral skull radiograph. The cephalometric points are marked and the cephalometric planes and angles are traced (7).

This method can be very time consuming and still subject to errors. According to Prakash, these are some of the errors:

Incorrect identification of anatomical landmarks due to human error or fatigue factor.

Errors arising from performing several analyses on the same acetate sheet, which may overlap landmarks and planes.

Inexperience of the dentist in locating a point.

Govindrao (8) writes that X-ray exposure can cause the image to have less than ideal contrast or density, making it impossible to visualize the dots correctly.

Erkan *et al.* indicate that the technical errors in measurement using ruler and protractor, when measuring distance or obtaining angles, is so small that it demands great millimeter precision.

The points are marked and traced with a pencil, whose tip thickness may interfere with the exact measurement (9).

The constant technological advances in the computer area have allowed the development of computer programs designed to perform cephalometric tracings and measurements. Digital tracing has slowly replaced manual tracing (10).

Erkan *et al.* emphasize that the objective of using the digital system is to reduce the margin of error of measurements in cephalometric analysis, especially when evaluating its reproducibility and with the aim of considerably reducing the working time.

Computer-assisted cephalometric tracing requires the acquisition of a lateral digital radiographic image of the skull; the image is then transferred to a software.

There are 2 ways of digital tracing. In the first one, the clinician marks the cephalometric points, while in the second one, the anatomical points are placed by the algorithm of the digital system.

The literature mentions that in program-assisted cephalometric tracing, angles and distances are automatically calculated to eliminate errors in the drawing of lines between reference points and in measurements with a protractor (9).

Prakash points out that before performing a digital cephalometric analysis, the calibration of the radiograph should be performed, since these, which are shown on the screen, do not provide the image in real size. Hence, this is the first step in a digital cephalometric analysis. This step can be done in two ways, the first one is done by matching

the image with the actual measurements of the distance between two points, i.e., the scale of the 20mm ruler appears on the screen as 14mm, with the calibration, the scale of the 14mm ruler will alter the ruler to 20mm. The second way is using the dots per inch (DPI) value of the image; in this method, the image size is calibrated by distributing DPI to the original image size.

Digitizing a cephalogram without calibration would introduce significant measurement errors (7).

Additionally, when the analog radiograph is scanned for a digital cephalometric tracing, it may introduce additional magnification or reduction errors of the scan. This cephalogram must be calibrated for both magnification, one of deflecting the X-ray beam, and the scanning process.

It should be scanned with a visible 100mm scale ruler; calibration is performed by plotting two points of known length on the ruler (7).

The Planmeca Romexis® software platform includes modules and tools for a wide range of dental specialties.

The Planmeca Romexis® Cephalometric Analysis software module is the tool for performing cephalometric analysis, surgical planning and 2D treatment follow-ups. The software offers advantages such as automatic cephalometric tracing in seconds, versatile overlays for treatment follow-ups, and precision surgical simulation (18).

Retrieved from: <https://www.planmeca.com/>

MATERIALS AND METHODS

A sample of 24 lateral skull radiographs obtained by the Kodak 8000C Digital Panoramic and Cephalometric System from patients of the Universidad Latina de Costa Rica was used. These were subjected to Steiner and Ricketts cephalo-

metric tracing manually on a negatoscope and with Grafix Cephalometric Tracing acetate, using a 0.5mm lead pencil marking only the necessary anatomical points (Figure 1). Subsequently, the same radiographs were subjected to the Steiner and Ricketts cephalometric tracing in a computerized manner, using Planmeca Romexis® 6.0.1.812 software (Figure 2).

The calibration of both the digital image and the hard copy was based on the measurement of a known distance between two points.

Once the results of both cephalometric tracings were obtained, the differences of the linear and angular measurements were taken. Six measurements were calculated: cephalometric angle SN-Mandibular Plane, ANB, 1-SN and the linear distance of 1-NB, NB-Pog, L.i/Pn-Dt.

The results were obtained by quantitative observation based on a table and analyzed with the t-student statistical test.

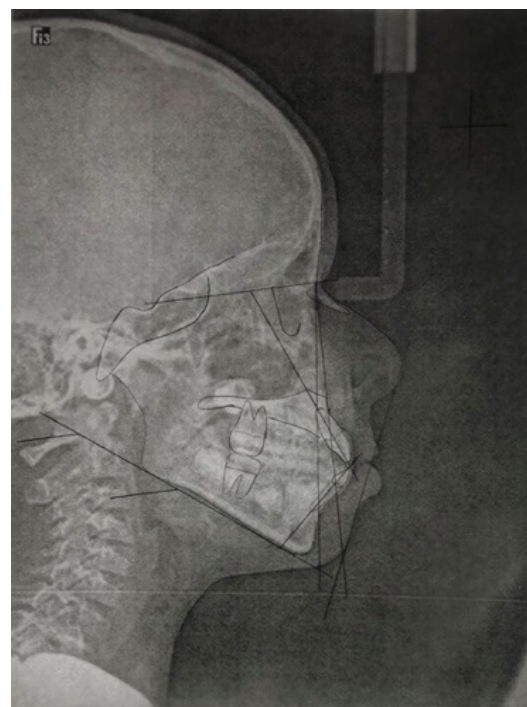


Figure 1. Manual cephalometric tracing.

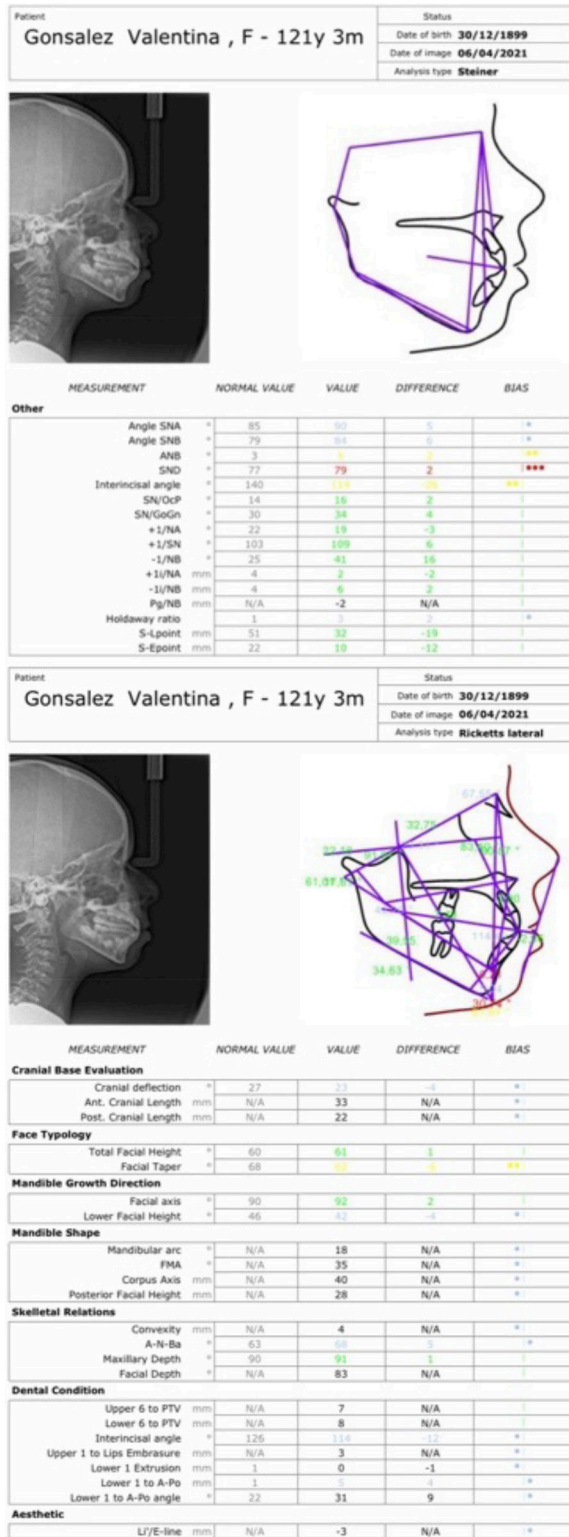


Figure 2. Steiner and Ricketts cephalometric tracing in a computerized manner.

RESULTS

The averages of each of the variables measured with the digital and manual techniques were the following, respectively: SN-PI Mandibular angle 33.96° (SD=4.14°) and 35.83° (SD=3.99°), ANB angle 4.38° (SD=2.28°) and 3.92° (SD=1.99°), 1-SN angle 100.83° (SD=7.12°) and 102.88° (SD=6.75°). On the other hand, the distances measured with the digital technique and the manual technique were the following, respectively: Distance 1-NB 2.92 mm (SD=1.41 mm) and 4.63 mm (SD=2.66 mm), distance NB-Pog -0.25 mm (SD: 0.98 mm) and 0.50 mm (SD: 1.18 mm), distance Li/ Pn-Dt -0.88 mm (SD: 1.87 mm) and 1.75 (SD: 3.19 mm).

In all the measures found, there is a significance of less than 0.05, except for the ANB and 1-SN angles (Table I).

Table 1. Results table.

	Digital Average	Manual Average	Significance t (Student): p
SN-PI Mandibular Angle	33.96 (SD:4.144)	35.83 (SD: 3.996)	0.020
ANB Angle	4.38 (SD: 2.281)	3.92 (SD: 1.998)	0.229
1-SN Angle	100.83 (SD:7.112)	102.88 (SD: 6.752)	0.062
Distance 1-NB	2.92 (SD: 1.412)	4.63 (SD: 2.667)	0.000
Distance NB-Pog	-0.25 (SD: 0.989)	0.5 (SD: 1.180)	0.033
Distance Li/Pn-Dt	-0.88 (SD: 1.872)	1.75 (SD: 3.193)	0.017

DISCUSSION

In this study, in the 6 measures found, there is a significant difference; $p < 0.05$, with the exception of the ANB and 1-SN angles.

Collins *et al.* (11) found that the angular measurements they studied were not significantly different, but the linear measurements were.

Albarakati *et al.* (12) observed significant differences between the two methods in most angular and linear measurements, except for ANB angle ($p=0.5$), convexity angle ($p=0.09$), anterior skull base ($p=0.3$) and lower anterior facial height ($p=0.6$). Contrary to us, they found significant differences in 1-SN.

Other authors such as Esteva S. *et al.* (13) in 2014 did not find significant differences in their measurements. We agree on the non-significance with them as well as Farooq and collaborators (14) in ANB and what is similar to what was observed by (12) Albarakati *et al.*

Farooq *et al.*, in their study to evaluate and compare the accuracy and reliability of cephalometric measurements between both systems, digital and conventional, found statistically significant differences in the U1-NA angle and the interincisal angle, where the values are higher in the manual tracking compared to digital (14).

Polat-Ozsoy *et al.* (15) found significant differences between the two methods for SNB, Wits, Cd-A, Cd-Gn, FMA, SN-PP, U1-NA (mm), U1-FH and congruent to our investigation: L1- NB (mm), and Li - esthetic plane.

In 2009, Naoumova and Lindman (16), found that most of the landmarks that tended to be less reliable corresponded to soft tissue landmarks,

which is proven in this study by a statistical difference in the Li/Pn-Dt measure.

In Pellicer's research (17) in 2014, several types of software were used, and he concluded that cephalometric measurements have different significant results depending on the cephalometric points that conform them. He evaluated that those employing points located on the lower incisors and chin had the highest number of significant results in the study. Specifically, the cephalometric points "incisal edge and apex of the lower incisor" with the Ortomed program and the cephalometric point "chin" with the Dolphin program had the highest incidence.

CONCLUSIONS

It is evident that cephalometric tracing with Planmeca Romexis® software is more reliable than manual tracing according to the data obtained in this research. It should be noted that digital cephalometry has advantages such as storage capacity, better clarity to visualize anatomical structures, greater speed and several cephalograms quickly among others, while conventional cephalometry has as its main disadvantage measurement errors by the operator. It is also important to mention that the cost of acquiring the software is a high investment; for this research, Planmeca Romexis® provided a demo for a limited time for study, but some versions of digital cephalometry can also be found free of charge or as low-cost applications.

Nowadays, digitalization is becoming increasingly important in our practice as dentists because it facilitates processes, allows innovation and precision in treatments and diagnoses.

The authors of this study declare that they have no conflict of interest and that this study was financed with their own funds.

AUTHOR CONTRIBUTION STATEMENT

Conceptualization and design: M.J.R.P.

Literature review: M.J.R.P. and P.C.T.

Methodology and validation: R.C.H.

Formal analysis: P.C.T. and M.J.R.P.

Investigation and data collection: P.C.T. and R.C.H.

Resources: P.C.T.

Data analysis and interpretation: M.J.R.P., P.C.T. and R.C.H.

Writing-original draft preparation: P.C.T.

Writing-review & editing: P.C.T. and M.J.R.P.

Supervision: P.C.T.

Project administration: P.C.T.

Financing acquisition: P.C.T.

REFERENCES

- Balaguer J., Balaguer V., Izquierdo V., Balaguer I. Historia de la Cefalometría. *Gaceta Dental*. 2009; (201): 104-110.
- Proffit W., Fields H., Sarver D. *Ortodoncia Contemporánea*. 4ta Edición. España: Editorial ELSEVIER MOSBY; 2008.
- Barahona J., Benavides J. Principales análisis cefalométricos utilizados para el diagnóstico ortodóntico. *Revista Científica Odontológica*. 2006; 2 (1): 11-27.
- Companiononi A., Rodríguez M., Villegas V., Otaño R. Bosquejo histórico de la cefalometría radiográfica. *Revista Cubana Estomatología*. 2008; 45 (2): 1561-297x.
- Nevárez V. Análisis de la radiografía cefálica lateral para el diagnóstico ortodóntico [PhD Thesis]. Ecuador: Universidad Laica Eloy Alfaro de Manabí; 2018.
- Rino J., Batista de Paiva J., Vilanova G., Ferragut M., Miasiro H. Evaluation of radiographic magnification in lateral cephalograms obtained with different X-ray devices: Experimental study in human dry skull. *Dental Press Journal of Orthodontics*. 2013; 18 (2): 17.e1-7.
- Prakash O. *Orthodontics: Diagnosis and Management of Malocclusion and Dentofacial Deformities*. 3rd ed. India: ELSEVIER; 2019.
- Govindrao A., Anil S. *Textbook of Oral Radiology*. 2nd ed. India: ELSEVIER; 2008.
- Erkan M., Gurel H., Nur M., Demirel B. Reliability of four different computerized cephalometric analysis programs. *European Journal of Orthodontics*. 2012; (34): 318-321. Doi: 10.1093/ejo/cjr008
- Toledo D., Lima M., Bravo M. Estudio comparativo de confiabilidad y precisión entre el método de Trazado Cefalométrico manual con el digital usando el programa Dolphin Imaging con radiografías cefálicas laterales. *Revista Latinoamericana de Ortodoncia y Ortopedia*. 2014; 2 (28): art-7. Available from <https://www.ortodoncia.ws/publicaciones/2014/art-7/>
- Collins J., Shah A., McCarthy C., Sandler J. Comparison of measurements from photographed lateral cephalograms and scanned cephalograms. *Am J Orthod Dentofacial Orthop*. 2007; 132 (6): 830-33.
- AlBarakati S., Kula K., Ghoneima A. The reliability and reproducibility of cephalometric measurements: a comparison of conventional and digital methods. *Dentomaxillofacial Radiology*. 2012; 41 (1): 11-17.

13. Esteva F., Sánchez A., Meléndez A. Estudio comparativo entre la cefalometría digital y manual con radiografías digitales. *Revista Mexicana de Ortodoncia*. 2014; 2 (2): 95-98.
14. Farooq M., Khan M., Imran S., Sameera A., Qureshi A., Ahmed A., Kumar S., Rahman A. Assessing the Reliability of Digitalized Cephalometric Analysis in Comparison with Manual Cephalometric Analysis. *Journal of Clinical and Diagnostic Research*. 2016; 10 (10): ZC20-ZC23. Doi: 10.7860/JCDR/2016/17735.8636
15. Polat-Ozsoy O., Gokcelik A., Toygar U. Differences in cephalometric measurements: A comparison of digital versus hand-tracing methods. *European Journal of Orthodontics*. 2009; 31 (3): 254-259. Doi: 10.1093/ejo/cjn121
16. Naumova J., Lindman R. A comparison of manual traced images and corresponding scanned radiographs digitally traced. *European Journal of Orthodontics*. 2009; 31 (3): 247-253. Doi: 10.1093/ejo/cjn110
17. Pellicer Castillo L. Estudio cefalométrico comparativo entre trazados manuales y digitales con programas informáticos [PhD Thesis]. Salamanca, España: Universidad de Salamanca; 2014.
18. Planmeca. Módulos de Software de Romexis®. Finlandia. Recuperado de: <https://www.planmeca.com/>