



## LITERATURE REVIEW:

### Conservative Approaches to Managing Medication-Related Osteonecrosis of the Jaw (MRONJ): A Narrative Review

Enfoques conservadores para el manejo de la osteonecrosis de los maxilares relacionada con medicamentos (MRONJ): una revisión narrativa

Amany Hany Mohamed Kamel<sup>1,2</sup> <https://orcid.org/0000-0002-3562-1099>

Fatma AlKindi<sup>1</sup> <https://orcid.org/0009-0006-4993-5802>

Rawan Alharrasi<sup>1</sup> <https://orcid.org/0000-0002-9739-0425>

Nadiya AlKindi<sup>1</sup> <https://orcid.org/0009-0001-9499-2703>

<sup>1</sup>Dental Unit, Medical Specialities Department, Sultan Qaboos Cancer Care and Research Center, University Medical City, Muscat, Oman.

<sup>2</sup>Assistant Professor, Faculty of Dentistry, Cairo University, Cairo, Egypt.

Correspondence to: Amany Hany Mohamed Kamel - [amany.hany@dentistry.cu.edu.eg](mailto:amany.hany@dentistry.cu.edu.eg)

Received: 9-IV-2025

Accepted: 22-VII-2025

**ABSTRACT:** Medication-Related Osteonecrosis of the Jaw (MRONJ) is a severe complication associated with the use of bone-modifying agents, such as Zoledronic Acid and Denosumab, in cancer patients. It poses significant challenges in prevention, diagnosis, and treatment, highlighting the urgent need for effective and evidence-based management strategies to optimize patient outcomes. Conservative approaches have gained attention as viable alternatives to surgical intervention, particularly in early-stage MRONJ. These strategies include antimicrobial therapy, pain management, local wound care, and adjunctive therapies such as low-level laser therapy and photodynamic therapy. Hyperbaric oxygen therapy has also been investigated; however, current literature doesn't provide strong evidence to support its routine use. Additionally, several inflammatory and bone turnover markers, including CTX, P1NP and RANKL in addition to regulatory cytokines like OPG have been studied for their potential to reflect disease progression and treatment response. While non-surgical management has shown promising results in symptom control and healing, the lack of standardized treatment protocols remains a limitation. Further research is needed to refine conservative treatment guidelines to explore reliable biomarkers and innovative therapeutic strategies to improve clinical outcomes and quality of life for affected patients.

**KEYWORDS:** Osteonecrosis; Zoledronic acid; Denosumab; Cancer patients; Conservative treatment; Patient care; Bone turnover.

**RESUMEN:** La osteonecrosis de los maxilares relacionada con medicamentos (MRONJ) es una complicación grave asociada con el uso de agentes modificadores óseos, como el ácido zoledrónico y el denosumab, en pacientes con cáncer. Representa desafíos significativos en la prevención, diagnóstico y tratamiento, lo que requiere estrategias de manejo efectivas para mejorar los resultados en los pacientes. Los enfoques conservadores han ganado atención como alternativas viables a la intervención quirúrgica, particularmente en las etapas tempranas de la MRONJ. Estas estrategias incluyen terapia antimicrobiana, manejo del dolor, cuidado local de heridas y terapias adyuvantes como la terapia con láser de bajo nivel, la terapia fotodinámica y la terapia con oxígeno hiperbárico. Además, la evidencia emergente sugiere que los marcadores inflamatorios y de recambio óseo, incluidos CTX, P1NP, RANKL y OPG, podrían proporcionar información sobre la progresión de la enfermedad y la respuesta al tratamiento. Aunque el manejo no quirúrgico ha mostrado resultados prometedores en el control de los síntomas y la cicatrización, la falta de protocolos de tratamiento estandarizados sigue siendo una limitación. Se necesita más investigación para perfeccionar las directrices de tratamiento conservador y explorar nuevas opciones terapéuticas para mejorar el cuidado del paciente y los resultados clínicos.

**PALABRAS CLAVE:** Osteonecrosis; Ácido zoledrónico; Denosumab; Pacientes con cáncer; Tratamiento conservador; Cuidado del paciente; Recambio óseo.

## INTRODUCTION

Medication-Related Osteonecrosis of the Jaw (MRONJ) is a rare but significant complication associated with the use of antiresorptive agents, such as bisphosphonates and denosumab, as well as antiangiogenic medications commonly prescribed for bone metastases and related conditions. This condition significantly impacts patients' quality of life and can lead to substantial morbidity (1). Initially described by Marx in the early 2000s in patients undergoing bisphosphonate therapy, it was initially termed bisphosphonate-related osteonecrosis of the jaw (BRONJ) (2). However, the American Association of Oral and Maxillofacial Surgeons (AAOMS) later expanded the definition of MRONJ to encompass all medication-related causes, including denosumab and antiangiogenic agents, leading to the broader term MRONJ (3).

The incidence of MRONJ varies widely and is significantly higher in patients receiving antiresorptive drugs for cancer treatment, ranging from 0.7% to 6.6%, with even higher rates reported in

those treated with sequential antiresorptive therapies (up to 19%). In contrast, the incidence among osteoporosis patients on oral bisphosphonates is much lower, ranging from 0.001% to 0.2% across different countries, reflecting the substantially increased risk associated with intravenous formulations (4).

Diagnosis of MRONJ is established based on three key criteria: 1. current or prior exposure to antiresorptive or antiangiogenic agents, 2. the presence of exposed or non-healing bone in the maxillofacial region for more than eight weeks, and 3. the absence of head and neck radiation therapy or metastatic disease in the jaw (3). To aid in diagnosis and management, the AAOMS developed a staging system that classifies MRONJ into four stages. Stage 0 includes patients with nonspecific symptoms such as pain but no visible necrosis. Stage 1 involves exposed bone without infection or pain, whereas Stage 2 presents with exposed bone and clinical signs of infection. Stage 3 is the most severe, often characterized by extensive necrosis, infection, or pathological fractures (3).

While surgical intervention remains the mainstay for advanced MRONJ cases, conservative management approaches have gained recognition for their ability to preserve bone integrity, control symptoms, and potentially slow disease progression in early-stage cases (5, 6). This review focuses on conservative strategies for MRONJ management, emphasizing their clinical relevance and efficacy in preventing disease progression.

## PATHOPHYSIOLOGY OF MRONJ

Despite two decades of research, the pathophysiology of MRONJ remains incompletely understood and is considered multifactorial. Several hypotheses have been proposed, including excessive suppression of bone turnover, impaired vascular supply, microtrauma, and the role of infection or inflammation (6). MRONJ is primarily associated with antiresorptive medications, such as bisphosphonates and denosumab, which are widely used for osteoclastic bone diseases. While these agents improve bone density and quality in osteoporosis and metastatic bone cancer, they also significantly increase the risk of osteonecrosis, particularly in the jaw, due to its high bone turnover rate and exposure to local risk factors (5, 7). Furthermore, antiangiogenic therapies, which inhibit vascular endothelial growth factor (VEGF), can further exacerbate MRONJ by reducing blood supply and inducing ischemia (Figure 1) (7).

A key factor in MRONJ development is the profound inhibition of bone resorption and remodeling, especially in cancer patients receiving high doses of these medications (8). The jawbone, with its higher turnover rate compared to other skeletal sites, is particularly susceptible (9). Dental extractions and other procedures affecting alveolar bone are major triggers, whereas soft tissue damage alone rarely leads to necrosis (10).

## ROLE OF OSTEOCLAST INHIBITORS

Bisphosphonates, a well-established class of antiresorptive drugs, inhibit osteoclast activity, reducing bone resorption and improving bone density. However, their long half-life in bone tissue increases the risk of BRONJ, even after discontinuation (6). Denosumab, a more recent antiresorptive agent, acts by inhibiting osteoclast formation and survival through its anti-RANKL antibody mechanism. Unlike bisphosphonates, denosumab has a shorter half-life, with its effects diminishing within six months after discontinuation, affecting the timing of MRONJ onset (11, 12).

## IMPACT OF ANTIANGIOGENIC AGENTS

MRONJ may also represent a form of avascular necrosis, particularly in patients receiving antiangiogenic agents. These medications, such as bevacizumab and some tyrosine kinase inhibitors (TKIs), inhibit VEGF receptors, which are essential for angiogenesis. Reduced blood supply may contribute to bone ischemia, predisposing patients to MRONJ (7, 13). Interestingly, zoledronic acid, a potent bisphosphonate, also exhibits antiangiogenic properties. Cancer patients treated with zoledronic acid have been shown to have reduced circulating VEGF levels (14, 15). However, histological studies of MRONJ lesions frequently reveal patent blood vessels, suggesting that while angiogenesis inhibition plays a role, it is not the sole causative factor (15).

## INFECTION AND BIOFILM FORMATION

Infection plays a pivotal role in MRONJ pathogenesis. Histopathological analyses frequently reveal necrotic bone associated with microbial biofilms containing organisms such as *Actinomyces*, fungi, and viruses (13, 16-18). However, it remains

unclear whether infection initiates MRONJ or merely exacerbates the condition. While *Actinomyces* is often detected in MRONJ lesions, its exact role—whether as a causative factor or an opportunistic colonizer—remains debated. Nonetheless, antimicrobial therapy remains a cornerstone of MRONJ management, primarily aimed at controlling secondary infections and alleviating symptoms (17, 18).

#### MONOCYTE AND MACROPHAGE INVOLVEMENT

A growing body of evidence suggests that immune system dysfunction, particularly involving monocytes and macrophages, plays a crucial role in MRONJ pathogenesis. Osteoclast inhibitors such as bisphosphonates and denosumab may impair macrophage function, weaken the local immune response and promote bone necrosis (19-21).

#### LOCAL AND SYSTEMIC RISK FACTORS

Several systemic and local risk factors contribute to MRONJ development. Systemic factors include diabetes, which negatively affects bone metabolism and oral health. Chronic hyperglycemia impairs both bone and mucosal microarchitecture, delaying wound healing and increasing MRONJ risk (22, 23). Smoking is another significant risk factor, as it alters the oral microbiota, impairs immune responses, and accelerates periodontal disease progression. However, smoking cessation has been shown to significantly reduce disease incidence and improve recovery (Figure 1) (24).

Patients should also be informed about the dose- and duration-dependent relationship between antiresorptive therapy and MRONJ risk, with prolonged treatment and higher doses increasing susceptibility (4, 25). Cancer patients,

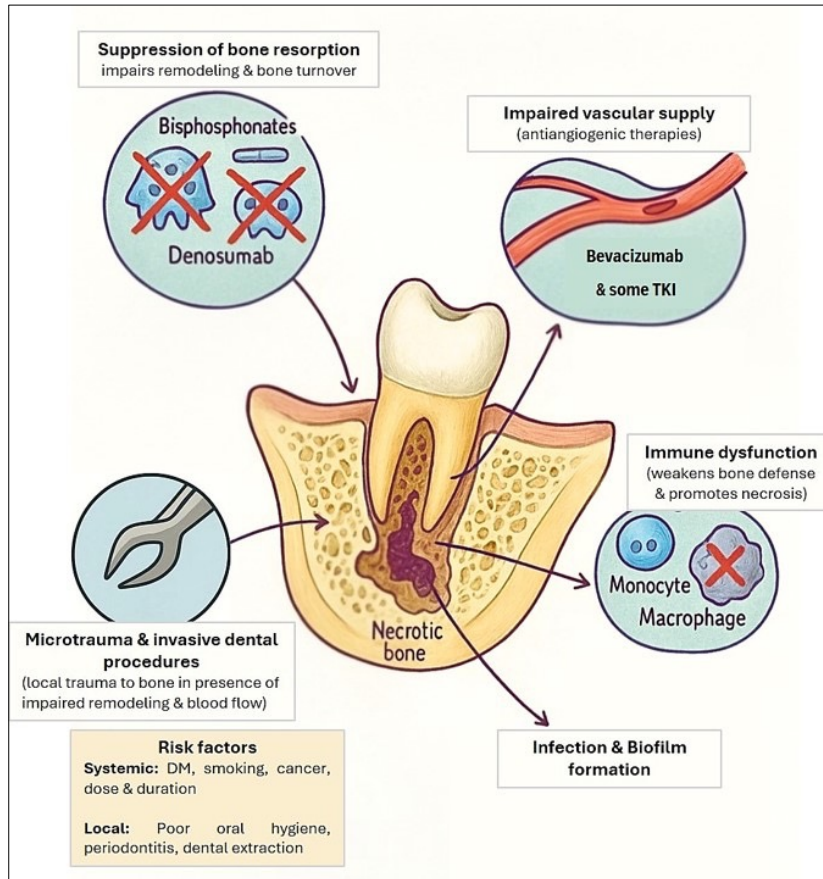
particularly those with multiple myeloma, breast, prostate, or renal cancer, face an elevated risk due to the combined effects of bisphosphonates and antiangiogenic treatments (26).

Local risk factors such as poor oral hygiene, periodontal disease, and dental extractions play a critical role in MRONJ onset, with 52-61% of cases occurring post-extraction (25-27). Addressing these factors before initiating antiresorptive therapy is essential to mitigate MRONJ risk (Figure 1) (7, 28).

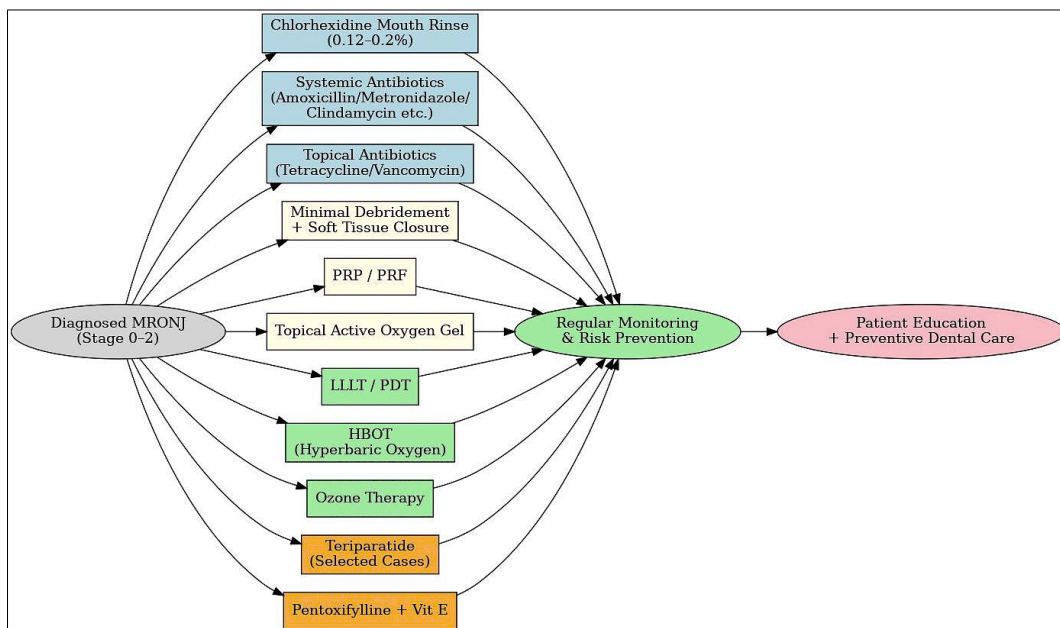
#### CONSERVATIVE MANAGEMENT STRATEGIES

The primary goals of conservative management for MRONJ are to alleviate pain, control infection, and prevent disease progression while maintaining oral function and avoiding aggressive surgery. This approach is particularly suitable for early-stage MRONJ (Stages 0-2), as it minimizes unnecessary trauma to the jaw and reduces the risk of exacerbating necrosis (6). Conservative strategies focus on stabilizing the condition through symptom control rather than extensive surgical resection (3, 29, 30).

Initial measures typically include antimicrobial mouth rinses, systemic antibiotics when clinically indicated, strict oral hygiene maintenance, and conservative surgical interventions, such as the removal of loose bone sequestra. If conservative strategies fail to relieve symptoms or restore function, more aggressive surgical interventions may be necessary. However, before proceeding with invasive procedures, the multidisciplinary care team must thoroughly discuss the associated risks and benefits with the patient (Figure 2, Table 1) (3, 6, 31).



**Figure 1.** A diagram illustrating the multifactorial pathophysiology of MRONJ, highlighting the role of osteoclast inhibition, impaired angiogenesis, local trauma, infection with biofilm formation, immune dysfunction & contributing risk factors.



**Figure 2.** A flowchart illustrating conservative management of MRONJ (stage 0-2).

**Table 1.** Summary of key studies and evidence supporting conservative management approaches for MRONJ.

Study / Author(s)	Type of Study / Source	Conservative approach	Patient Group	Key Findings	Notes / Limitations
Bagan <i>et al.</i> (45)	Clinical recommendation	0.12% chlorhexidine rinses + irrigation	MRONJ patients, Stages 0-3	Reduced microbial load, promoted healing	Empirical protocol, no control group
SECOM Guidelines (Spain) (39)	Clinical guideline	Amoxicillin-clavulanate ± clindamycin/levofloxacin	Stage 2,3 MRONJ	Symptom relief with adjuncts (e.g., pentoxifylline, Vit E)	Emphasizes short antibiotic use (7-21 days)
Heifetz <i>et al.</i> , (40)	Systematic review	Combined antibiotics + pentoxifylline + Vit E + CHX	Stage 3 MRONJ	Notable symptom reduction and stabilization	Limited sample, no controls
Mozzati <i>et al.</i> , (57)	Randomized controlled trial	PRGF + antibiotics vs. control	176 extraction patients on antiresorptives	0% MRONJ in PRGF group vs. 6% in control	Possible selection bias; very low-quality evidence
Melichercik <i>et al.</i> (2014) (68)	Clinical case series	Topical vancomycin	Osteomyelitis (MRONJ-extrapolated)	Promoted healing	Not MRONJ-specific
Shakeri <i>et al.</i> ; Tabrizi <i>et al.</i> ; Shaw <i>et al.</i> ; Er <i>et al.</i> , (62-65)	Clinical, animal, <i>in vitro</i>	Topical phenytoin	Osteopetrosis / necrotic wounds	Accelerated tissue healing via multiple mechanisms	Evidence indirect for MRONJ
Atalay <i>et al.</i> ; Altay <i>et al.</i> ; Weber <i>et al.</i> , (69-71)	Retrospective clinical studies & systematic review	Low-level laser therapy / photodynamic therapy	MRONJ patients, mixed stages	Improved healing, reduced pain	Usually used adjunctively; small sample sizes
Freiberger <i>et al.</i> , (74)	Case series (n=16)	Hyperbaric oxygen therapy	Mixed-stage MRONJ	87.5% improved; 62.5% remission/stable	Small sample; non-randomized; outcomes worse if BPs continued
Ripamonti <i>et al.</i> ; Agrillo <i>et al.</i> , (76,77)	Case series	Topical ozone	Mixed-stage MRONJ	Symptom reduction, improved healing	Small sample, no long-term data
Sim <i>et al.</i> ; Morishita <i>et al.</i> ; dos Santos Ferreira <i>et al.</i> , (78-80)	RCT, retrospective, meta-analysis	Short course teriparatide	MRONJ with bisphosphonate history	Reduced lesion size, improved healing	Mixed patient types: cancer patients underrepresented
Colapinto <i>et al.</i> , (84)	Prospective randomized cohort	Oral pentoxifylline + Vit E ± surgery	202 Stage I MRONJ patients	100% healing at 1 month in treatment group	Advanced-stage response unclear
Deliberador <i>et al.</i> , (86)	Case study	Topical active oxygen gel (blue@m)	Stage 2 MRONJ patient	Full epithelialization & no bone exposure during 2 years follow up	Single case; promising for failed conventional therapy
Radiomics / CBCT studies (87-90)	Imaging research	Cone Beam CT, radiomic texture analysis	All MRONJ stages	Early detection, precise staging, guided planning	Requires technology, expertise
MSC studies (91-93)	Experimental / preclinical	Stem cell therapy (MSCs)	Advanced MRONJ (experimental)	Enhanced healing via bone & immune modulation	Not yet in routine clinical use
Multiple sources (94-102)	Guidelines + clinical reports	Preventive dental care, de-crowning, risk-based extraction	Patients before or during antiresorptive therapy	Reduced MRONJ incidence, maintained bone integrity	Based on expert consensus and observational data

CHX=Chlorhexidine; PRGF=Plasma Rich in Growth Factors; Vit E=Vitamin E; HBOT=Hyperbaric Oxygen Therapy; PDT=Photodynamic Therapy; LLLT=Low-Level Laser Therapy; MSC=Mesenchymal Stem Cell; RCT=Randomized Controlled Trial; NS=Not Significant; MRONJ=Medication-Related Osteonecrosis of the Jaw.

## PHARMACOLOGICAL INTERVENTIONS

### ANTIBIOTIC THERAPY

Long-term systemic antibiotics are a key component of MRONJ management, aimed at controlling infection and reducing inflammation. The choice and duration of antibiotic therapy depend on the disease stage, the presence of secondary infections, and the patient's overall health status. Commonly prescribed antibiotics include penicillin derivatives such as amoxicillin, amoxicillin/clavulanate, and metronidazole, which effectively target infections associated with necrotic bone exposure (32). For penicillin-allergic patients, alternatives like clindamycin or levofloxacin are recommended due to their strong tissue penetration and effectiveness against Gram-positive bacteria (33).

Antibiotic therapy has been shown to extend remission periods, reduce inflammation, and prevent complications from infections. While both intermittent and continuous antibiotic cycles are used, an optimal regimen remains undefined (34, 35). The combination of amoxicillin/clavulanic acid with metronidazole has demonstrated favorable outcomes, particularly when used alongside oral antiseptic solutions such as 0.2% chlorhexidine rinses (36). In cases where antibiotic susceptibility testing is unavailable, broad-spectrum antibiotics targeting key bacteria associated with MRONJ—such as *Actinomyces*, *Fusobacterium*, *Eikenella*, *Staphylococcus*, and *Streptococcus* are recommended. Although *Actinomyces* is frequently detected in MRONJ lesions, its exact role in pathogenesis remains debated due to isolation challenges (37). In cases where fungal involvement is suspected, antifungal agents like nystatin or fluconazole may be indicated (38).

The Spanish Society of Oral and Maxillofacial Surgery (SECOM) guidelines recommend an antibiotic regimen of amoxicillin 875 mg/125 mg, with clindamycin or levofloxacin as alternatives for

penicillin-allergic patients (39). Clinical improvements have been observed in cases treated according to the SECOM protocol, where amoxicillin-clavulanic acid was administered for 15 days, with extensions as needed. For Stage 3 MRONJ patients, conservative treatment strategies that combine systemic antibiotics with pentoxifylline, vitamin E, and chlorhexidine rinses have demonstrated significant symptom relief (40). The duration of antibiotic therapy typically ranges from one week to several weeks or until complete healing is achieved (41). While some experts advocate for long-term antibiotic use until clinical remission of MRONJ symptoms (42), Spanish Society of Oral and Maxillofacial Surgery (SECOM) and Spanish Society of Oral Medicine (SICMF-SIPMO) guidelines recommend restricting antibiotics to cases of acute infection or recurrent exacerbations, with treatment duration limited to 7-21 days to minimize the risk of antibiotic resistance (36).

Emerging strategies include antibiotic-impregnated membranes for localized drug delivery, reducing systemic antibiotic exposure (43). For instance, gentamicin-impregnated collagen matrices have demonstrated efficacy in reducing post-treatment infections in MRONJ patients (44).

### ANTIMICROBIAL MOUTH RINSES

Chlorhexidine gluconate remains the most widely used antimicrobial mouth rinse due to its broad-spectrum antimicrobial activity and prolonged substantivity, which enhances biofilm control. Chlorhexidine is recommended in all MRONJ stages (Stages 0-3) to prevent infection and promote oral health (33,45). Bagan *et al.* (45) suggest a regimen of 0.12% chlorhexidine rinses twice daily, supplemented with irrigation of necrotic sites every 72 hours for four weeks. If improvement is observed, the rinses are continued for an additional month to sustain infection control and wound healing. This approach has been shown to reduce microbial contamination and prevent disease progression

while minimizing the need for surgical intervention (33).

#### ANTI-RESORPTIVE DRUG HOLIDAYS

Temporarily discontinuing bisphosphonate or Denosumab therapy, commonly referred to as a “drug holiday,” remains a controversial strategy in MRONJ management. Some evidence suggests that pausing anti-resorptive medications for 1-6 months may promote bone healing and slow disease progression. However, this decision must be individualized, balancing MRONJ stabilization with the patient's underlying cancer treatment needs (46-48). While discontinuation may alleviate MRONJ symptoms and stabilize lesions, it can also increase the risk of skeletal-related events in oncology patients receiving anti-resorptive or antiangiogenic agents (11, 49, 50). Guidelines on drug holidays vary; the European Myeloma Network recommends pausing bisphosphonates until MRONJ lesions heal, whereas Canadian guidelines emphasize patient education on continued therapy (51, 52). Moreover, the 2022 position paper from the American Association of Oral and Maxillofacial Surgeons (AAOMS) advises against routine discontinuation of anti-resorptive agents in oncology patients, even if they are at risk for MRONJ (48). Although some retrospective studies suggest improved healing with drug holidays, their findings remain inconclusive due to a lack of prospective data (47).

#### LOCAL MANAGEMENT TECHNIQUES

##### TARGETED DEBRIDEMENT AND SOFT TISSUE COVERAGE

Minimal and targeted debridement represent a conservative approach in managing MRONJ, aimed at selectively removing necrotic bone while preserving healthy tissue. This technique focuses on reducing bacterial load and biofilm formation—key factors in MRONJ progression—while minimi-

zing further necrosis and the need for more invasive procedures. When performed in the early stages (Stage 1 or 2), it can help stabilize lesions, alleviate pain, and preserve oral function without compromising the structural integrity of the jaw (53).

The procedure utilizes tools like curettes, piezoelectric devices, and lasers, with piezoelectric surgery offering the advantage of precise necrotic bone removal while minimizing damage to adjacent healthy tissue. Soft tissue closure following debridement is essential to enhance healing, prevent infection, and restore function, often achieved through primary wound closure to ensure optimal blood supply and tissue regeneration (54).

This conservative technique is typically combined with adjunctive therapies, such as antimicrobial treatments or regenerative options like platelet-rich fibrin (PRF) or low-level laser therapy (LLLT), to improve outcomes. Studies suggest that, while not curative, minimal debridement can significantly reduce the progression of MRONJ and preserve oral health, avoiding the complications associated with more aggressive surgical resections (55, 56).

##### PLATELET-RICH PLASMA (PRP) OR PLATELET-RICH FIBRIN (PRF) THERAPY

Platelet-rich plasma (PRP) and platelet-rich fibrin (PRF) are autologous blood-derived products that enhance wound healing by delivering a concentrated dose of growth factors. These bioactive molecules accelerate tissue regeneration and have gained attention in dental applications, particularly in surgical wound healing. A randomized clinical trial evaluated the efficacy of platelet-rich growth factors (PRGF) in preventing MRONJ following dental extractions in patients receiving antiresorptive therapy. In the study, all participants received a six-day antibiotic regimen before extractions; however, none of the 91 patients treated with PRGF developed MRONJ, whereas

five cases occurred among the 85 patients in the control group (57). Despite these promising results, the study has been criticized for potential selection bias and limitations in outcome assessment, leading to a classification of the evidence as very low quality (58). Although PRP and PRF may serve as conservative strategies to prevent MRONJ, their effectiveness remains unproven, necessitating further high-quality research to establish standardized protocols and confirm clinical benefits.

#### TOPICAL TREATMENTS FOR SYMPTOMATIC RELIEF

Topical antibiotics and anti-inflammatory agents can directly target localized infections and inflammation in MRONJ patients, offering a non-invasive approach to symptom management. Topical tetracyclines and metronidazole have been used to reduce bacterial load in necrotic lesions (59-61).

Clinical, animal, and *in vitro* studies suggest that phenytoin enhances wound healing through multiple mechanisms (62). Topical phenytoin was used in osteopetrosis patients to enhance bone and soft tissue healing in the mandible (63). Phenytoin promotes healing by inducing fibroblast proliferation, stimulating granulation tissue formation, reducing collagenase activity, increasing collagen deposition, preventing bacterial contamination, and decreasing wound exudate (64, 65). Topical antibacterial agents, with their high local therapeutic concentrations, can improve healing in MRONJ lesions (66). Topical tetracycline, with its broad-spectrum antibiotic activity, may be particularly beneficial in managing this type of lesion. Moreover, Melicherck *et al.*, 2014 found that topical vancomycin was effective in treating osteomyelitis. Topical antibiotics are thus recommended for the conservative treatment of MRONJ (68).

#### ADJUNCTIVE THERAPEUTIC APPROACHES

##### LOW-LEVEL LASER THERAPY (LLLT) AND PHOTODYNAMIC THERAPY (PDT)

Both Low-Level Laser Therapy (LLLT) and Photodynamic Therapy (PDT) have shown potential in enhancing soft tissue healing and alleviating pain in patients with Medication-Related Osteonecrosis of the Jaw (MRONJ). LLLT works by utilizing specific wavelengths of light to stimulate cellular regeneration and improve local blood circulation, while PDT offers antimicrobial effects, reducing infection and inflammation. Evidence suggests that LLLT and PDT, when used alongside pharmacological treatments, can enhance clinical outcomes by promoting tissue healing and reducing inflammation (69, 70). LLLT has demonstrated efficacy in reducing pain and inflammation, and promoting tissue healing in MRONJ cases. However, most studies are small retrospective series, and involve LLLT combined with other treatments, complicating the assessment of its independent efficacy. Despite the promising results, further research is necessary to confirm its effectiveness as a standalone therapy (71, 72).

##### HYPERBARIC OXYGEN THERAPY (HBOT)

Hyperbaric oxygen therapy has been explored as an adjunctive treatment for MRONJ, primarily aimed at enhancing tissue oxygenation and promoting angiogenesis. This therapy involves inhaling 100% oxygen at elevated pressures, which can stimulate tissue repair and improve oxygen delivery to affected areas. While HBOT has shown promise in case reports and small studies, especially when combined with antibiotics, its efficacy remains debated (73, 74). Therefore, HBOT may be considered for select patients with

advanced MRONJ, but further research is needed to confirm its broader efficacy (75).

#### OZONE THERAPY

Ozone therapy has emerged as a potential adjunctive treatment for Medication-Related Osteonecrosis of the Jaw (MRONJ) due to its antimicrobial and anti-inflammatory properties. It can be applied topically or systemically, helping to reduce bacterial colonization and promote soft tissue healing. Ozone's ability to reduce oxidative stress and inflammation makes it a promising option for managing early-stage MRONJ, particularly in reducing bacterial colonization and promoting healing. Small case studies have reported encouraging results; one series involving 10 consecutive patients with bisphosphonate-related MRONJ demonstrated symptom reduction and improved healing following topical ozone application (76, 77). While these findings are promising, they come from limited studies, and further research is needed to validate ozone therapy's broader efficacy and safety in MRONJ management.

#### EMERGING NON-SURGICAL TREATMENTS

##### TERIPARATIDE

Teriparatide, a recombinant form of parathyroid hormone, has emerged as a promising therapeutic option for patients with MRONJ, particularly those with a history of bisphosphonate use. This medication stimulates bone formation and enhances bone turnover, which may facilitate healing in necrotic areas of the jaw. Research suggests that teriparatide may reduce necrotic lesion size and improve clinical outcomes, particularly in patients with bisphosphonate-related MRONJ. One small trial highlighted the potential benefits of an eight-week course of teriparatide (78), and similar

results were observed in a retrospective study (79). The meta-analysis by 80 also indicated that teriparatide therapy significantly improved healing in patients with advanced MRONJ, especially when combined with adjunctive therapies like antibiotics or surgery. However, while teriparatide shows promise, further research, including longer follow-up and larger cohorts, is needed to confirm its safety and efficacy before widespread use. A short course of teriparatide may be considered for patients with prolonged, nonhealing MRONJ before resorting to more invasive surgical interventions. The decision to administer this therapy should involve an individual risk assessment conducted by the treating clinician in collaboration with the patient, carefully weighing the potential short-term benefits against any possible, though likely minimal, safety concerns (80, 81).

##### PENTOXIFYLLINE AND VITAMIN E

Pentoxifylline and vitamin E have been investigated as a combination therapy for the management of MRONJ. Pentoxifylline, a methylxanthine derivative, enhances blood flow and tissue oxygenation, while vitamin E serves as an antioxidant. Clinical studies indicate that this combination can lead to reduced pain, improved healing, and decreased reliance on surgical interventions in patients with MRONJ (82, 83). A prospective randomized trial of 202 stage I MRONJ patients compared pentoxifylline (600 mg twice daily) and vitamin E (800 I.U. daily) for two months before sequestrectomy, followed by six months of treatment, to sequestrectomy alone. Remarkably, all patients in the treatment group exhibited healed mucosa at one month, while only 17% of the control group achieved similar healing. After six months, all patients in the control group received pentoxifylline and vitamin E, with all responding positively. However, it remains unclear how patients with cancer, who

often present with more advanced stages of osteonecrosis and receive higher doses of therapy, may respond to this treatment regimen (84).

#### TOPICAL ACTIVE OXYGEN THERAPY

Topical active oxygen therapy enhances MRONJ healing by delivering oxygen, promoting angiogenesis, reducing bacterial load, and supporting tissue regeneration while preserving the oral microbiome. A systematic review and meta-analysis demonstrated the safety and effectiveness of topical oxygen therapy for chronic wound treatment, indicating its potential for accelerating healing and controlling bacterial infection. This therapy has been shown to inhibit the growth of *P. gingivalis* *in vitro*, exhibiting similar efficacy to chlorhexidine while selectively eradicating anaerobic bacteria responsible for oral infections. In a case study of a patient with stage 2 MRONJ, unresponsive to initial therapies of surgical debridement and antibiotics, significant epithelialization and healing were observed, with the complete resolution of symptoms and no further bone exposure during a two-year follow-up, following a 15-day regimen of topical blue® oral gel application. The positive outcomes observed in this case emphasize the potential of topical oxygen gel as a viable adjunct for MRONJ treatment, particularly in cases where conventional methods fail (85, 86).

#### ADVANCEMENTS IN IMAGING AND DIAGNOSTICS

Recent advancements in imaging technologies, particularly Cone Beam Computed Tomography (CBCT) and radiomic analysis, have greatly enhanced the ability to diagnose and precisely stage Medication-Related Osteonecrosis of the Jaw (MRONJ). CBCT provides high-resolution 3D imaging that allows clinicians to assess both cortical and cancellous bone, detect early signs of osteonecrosis, and accurately measure the extent of bone damage. This is crucial for detecting

osteolytic and mixed lesions typical of MRONJ, enabling more accurate staging and treatment planning (87, 88).

Radiomic analysis further improves diagnostic precision by extracting quantitative features from CBCT images, such as texture and bone density, which help identify early-stage changes that may be missed by traditional radiographs. This analysis allows for the prediction of disease progression, helping clinicians plan more effective, personalized treatments (Parekh & Jacobs, 2016). Moreover, the integration of these advanced imaging techniques supports minimally invasive procedures, enabling targeted interventions with reduced risk and improved outcomes. By accurately identifying affected areas and monitoring treatment response, these technologies help guide early-stage management, potentially reducing the need for extensive surgeries (88). Hence, CBCT and radiomics represent a significant advancement in MRONJ diagnosis and treatment, offering precise staging and more effective, minimally invasive intervention strategies that can lead to better patient outcomes (90).

#### INNOVATIVE APPROACHES: STEM CELL THERAPY

Mesenchymal stem cells (MSCs) are increasingly considered in MRONJ treatment due to their ability to differentiate into osteoblasts and their immunomodulatory properties (91). MSCs can enhance healing by increasing TGF- $\beta$ 1, IL-10, and regulatory T cells while reducing proinflammatory markers like IL-6 and IL-17 (92). However, the primary mechanism of MSCs, whether due to bone regeneration or immunomodulation, is still under investigation. While MSC therapy has limitations, including the need for additional equipment and complex procedures, it holds promise as an adjunctive method, particularly when combined with teriparatide for its regenerative potential. Research in 2024 has focused on adipose-derived

stem cells, showing promising results in enhancing jawbone regeneration (93).

#### PATIENT EDUCATION, PREVENTIVE STRATEGIES AND REGULAR MONITORING

The treatment of MRONJ is generally difficult, and the optimal therapy strategy is still to be established. For this reason, prevention is even more important. Effective patient education is fundamental in managing MRONJ, particularly for individuals receiving bisphosphonates or denosumab. Patients must understand the critical role of maintaining excellent oral hygiene and the importance of preventive dental care prior to starting these therapies (27).

International guidelines from organizations such as MASCC, ISOO, ASCO, and AAOMS strongly recommend comprehensive dental evaluations before starting osteoclast inhibitor therapy. These assessments should include detailed oral and periodontal examinations, radiographic imaging, and the removal of non-salvageable teeth to minimize potential complications (52, 54, 94). Furthermore, a waiting period of at least 2-3 weeks is advised following dental extractions or invasive procedures before initiating bisphosphonate or denosumab therapy. This allows for proper healing of the soft tissues and bone, reducing the risk of MRONJ development (95).

Patients should be instructed on establishing a structured oral care routine throughout their treatment. In cases requiring urgent intervention, regular follow-ups every to be conducted to monitor changes in oral health (96). Studies suggest that preventive dental check-ups and early interventions can substantially lower the incidence of MRONJ (97). Regular dental appointments facilitate the timely identification and management of potential oral health issues. While guidelines advise against invasive procedures, such as extractions, during treatment due to the increa-

sed MRONJ risk, non-invasive interventions are encouraged to maintain oral health (96). A collaborative approach between oncologists and dental professionals, with a strong emphasis on patient education, can significantly mitigate MRONJ risks and improve long-term patient outcomes.

If dental extractions become unavoidable during treatment with bisphosphonates or denosumab, careful planning of the timing and technique is essential. Extractions should ideally be performed under controlled conditions with a risk-reduction protocol, which typically includes: mucoperiosteal flap elevation, atraumatic tooth extraction, alveolectomy with smoothing of bone edges and tension-free soft tissue closure. Additionally, perioperative systemic antibiotics may also be administered to reduce the risk of MRONJ development (36, 98). These precautions are particularly important for patients who are on long-term therapy, as they present an increased risk for MRONJ due to prolonged exposure to bisphosphonates or denosumab. Gentle surgical techniques should be employed to minimize trauma to the bone and soft tissues. Post-operative care-including antimicrobial mouth rinses and meticulous oral hygiene-plays a critical role in reducing complications (95, 99, 100).

In cases where extractions pose a high risk, de-crowning (removing the tooth's crown while preserving the root) may be considered to maintain bone volume and prevent resorption. Although specific studies on de-crowning in MRONJ patients are limited, the principle of preserving the tooth root to maintain bone integrity is well-supported in dental literature. Research suggests that root canal therapy may delay or eliminate the need for extractions in patients on bisphosphonates, thereby reducing the risk of MRONJ (101). Additionally, the American Association of Endodontists (AAE) notes that non-restorable teeth can be managed by removing the crown, performing endodontic treatment on the remaining roots, and restoring

them for overdenture support (102,103). While further research is needed, de-crowning could be a viable alternative for at-risk patients, with treatment decisions tailored to each individual's overall health, tooth condition, and risk-benefit analysis (101).

## CONCLUSION

The management of MRONJ remains a multifaceted clinical challenge that necessitates a multidisciplinary approach. While conventional surgical and pharmacological treatments continue to be the foundation of MRONJ management, adjunctive therapies such as low-level laser therapy (LLLT), photodynamic therapy (PDT), hyperbaric oxygen therapy (HBOT), and ozone therapy have demonstrated promising effects in promoting healing and reducing inflammation. Emerging non-surgical treatments, including teriparatide, pentoxifylline with vitamin E, and topical active oxygen therapy, present novel therapeutic options, particularly for patients with refractory or advanced MRONJ. Advances in imaging techniques, such as cone beam computed tomography (CBCT) and radiomic analysis, have enhanced early diagnosis and disease staging, facilitating more precise treatment planning. Additionally, innovative therapies like mesenchymal stem cell therapy show promise for bone regeneration, although further research is needed to assess their clinical effectiveness.

Despite these advancements, prevention remains the most effective strategy in reducing MRONJ incidence. Comprehensive patient education, diligent oral hygiene, and regular dental monitoring are essential, particularly for individuals receiving bisphosphonates or denosumab. International guidelines highlight the importance

of pre-treatment dental evaluations and cautious management of invasive dental procedures to mitigate the risk of MRONJ. Future research should aim to refine treatment protocols, conduct large-scale clinical trials to validate emerging therapies, and explore personalized approaches to optimize patient outcomes. By integrating preventive measures with evolving therapeutic innovations, clinicians can significantly improve MRONJ management and the quality of life for affected patients.

ABBREVIATION LIST: MRONJ: Medication-Related Osteonecrosis of the Jaw; BMA: Bone-Modifying Agent; ZA: Zoledronic Acid; CTX: C-Terminal Telopeptide of Type I Collagen; P1NP: Procollagen Type I N-Terminal Propeptide; BALP: Bone Alkaline Phosphatase; TRAP: Tartrate-Resistant Acid Phosphatase; IL-1: Interleukin-1; IL-6: Interleukin-6; IL-8: Interleukin-8; TNF- $\alpha$ : Tumor Necrosis Factor Alpha; TKI: Tyrosine kinase inhibitor; RANKL: Receptor Activator of Nuclear Factor Kappa-B Ligand; OPG: Osteoprotegerin; CRP: C-Reactive Protein; LLLT: Low-Level Laser Therapy; PDT: Photodynamic Therapy; HBOT: Hyperbaric Oxygen Therapy; CBCT: Cone Beam Computed Tomography.

CONFLICTS OF INTEREST: The authors declare no competing interests.

ETHICAL APPROVAL: As this is a review article, ethical approval was not required.

CONSENT TO PUBLICATION: Not applicable.

AVAILABILITY OF DATA AND MATERIALS: The data supporting this review article are publicly available through the cited references.

FUNDING: No funding was received for this review.

AUTHOR CONTRIBUTION STATEMENT: Conceptualization, Methodology, Literature review, Data curation, Formal analysis, Writing-original draft: A.H.M.K.; Literature review, Data collection, Analysis, Writing-Review & editing: F.A., R.A. and N.A.; All authors participated in writing, editing, and finalizing the manuscript.

## REFERENCES

1. Di Fede, O. et al. The dental management of patients at risk of medication-related osteonecrosis of the jaw: New paradigm of primary prevention. *BioMed Research International* vol. 2018 Preprint at <https://doi.org/10.1155/2018/2684924> (2018).
2. Akashi, M. et al. A literature review of perioperative antibiotic administration in surgery for medication-related osteonecrosis of the jaw. *Oral and Maxillofacial Surgery* vol. 22: 369-378 Preprint at <https://doi.org/10.1007/s10006-018-0732-8> (2018).
3. Ruggiero, S. L. et al. American association of oral and maxillofacial surgeons position paper on medication-related osteonecrosis of the jaw - 2014 update. *Journal of Oral and Maxillofacial Surgery* vol. 72: 1938-1956 Preprint at <https://doi.org/10.1016/j.joms.2014.04.031> (2014).
4. AlRowis R., Aldawood A., AlOtaibi M., Alnasser E., AlSaif I., Aljaber A., Natto Z. Medication-Related Osteonecrosis of the Jaw (MRONJ): A Review of Pathophysiology, Risk Factors, Preventive Measures and Treatment Strategies. *Saudi Dent J.* 34 (3): 202-210. doi: 10.1016/j.sdentj.2022.01.003 (2022).
5. Lerman, M. A. et al. Conservative management of bisphosphonate-related osteonecrosis of the jaws: Staging and treatment outcomes. *Oral Oncol* 49: 977-983 (2013).
6. AlDhalaan, N. A., BaQais, A. & Al-Omar, A. Medication-related Osteonecrosis of the Jaw: A Review. *Cureus* (2020) doi:10.7759/cureus.6944
7. On, S. W., Cho, S. W., Byun, S. H. & Yang, B. E. Various therapeutic methods for the treatment of medication-related osteonecrosis of the jaw (Mronj) and their limitations: A narrative review on new molecular and cellular therapeutic approaches. *Antioxidants* vol. 10 Preprint at <https://doi.org/10.3390/antiox10050680> (2021).
8. Katsarelis, H., Shah, N. P., Dhariwal, D. K. & Pazianas, M. Infection and medication-related osteonecrosis of the jaw. *Journal of Dental Research* vol. 94: 534-539 Preprint at <https://doi.org/10.1177/0022034515572021> (2015).
9. Ristow, O. et al. Is bone turnover of jawbone and its possible over suppression by bisphosphonates of etiologic importance in pathogenesis of bisphosphonate-related osteonecrosis? *Journal of Oral and Maxillofacial Surgery* 72: 903-910 (2014).
10. Zandi, M., Dehghan, A., Janbaz, P., Malekzadeh, H. & Amini, P. The starting point for bisphosphonate-related osteonecrosis of the jaw: Alveolar bone or oral mucosa? A randomized, controlled experimental study. *Journal of Cranio-Maxillofacial Surgery* 45: 157-161 (2017).
11. Khan, A. A. et al. Case-Based Review of Osteonecrosis of the Jaw (ONJ) and Application of the International Recommendations for Management From the International Task Force on ONJ. *Journal of Clinical Densitometry* vol. 20: 8-24 Preprint at <https://doi.org/10.1016/j.jocd.2016.09.005> (2017).
12. McGowan, K., McGowan, T. & Ivanovski, S. Risk factors for medication-related osteone-

- crisis of the jaws: A systematic review. *Oral Diseases* vol. 24: 527-536 Preprint at <https://doi.org/10.1111/odi.12708> (2018).
13. Hansen, T., Kunkel, M., Weber, A. & Kirkpatrick, J. Osteonecrosis of the jaws in patients treated with bisphosphonates-histomorphologic analysis in comparison with infected osteoradionecrosis. *J Oral Pathol Med* 35: 155-160 (2006).
  14. Wood, J. et al. Novel antiangiogenic effects of the bisphosphonate compound zoledronic acid. *Journal of Pharmacology and Experimental Therapeutics* 302: 1055-1061 (2002).
  15. Allen, M. R. & Burr, D. B. Mandible Matrix Necrosis in Beagle Dogs After 3 Years of Daily Oral Bisphosphonate Treatment. *Journal of Oral and Maxillofacial Surgery* 66: 987-994 (2008).
  16. Estilo, C. L. et al. Osteonecrosis of the Maxilla and Mandible in Patients with Advanced Cancer Treated with Bisphosphonate Therapy. *Oncologist* 13: 911-920 (2008).
  17. Naik, N. H. & Russo, T. A. Bisphosphonate-related osteonecrosis of the jaw: The role of actinomyces. *Clinical Infectious Diseases* 49: 1729-1732 (2009).
  18. Sedghizadeh, P. P. et al. Identification of Microbial Biofilms in Osteonecrosis of the Jaws Secondary to Bisphosphonate Therapy. *Journal of Oral and Maxillofacial Surgery* 66: 767-775 (2008).
  19. Katsarelis, H., Shah, N. P., Dhariwal, D. K. & Pazianas, M. Infection and medication-related osteonecrosis of the jaw. *Journal of Dental Research* vol. 94: 534-539 Preprint at <https://doi.org/10.1177/0022034515572021> (2015).
  20. Geissmann, F. et al. Development of monocytes, macrophages, and dendritic cells. *Science* vol. 327: 656-661 Preprint at <https://doi.org/10.1126/science.1178331> (2010).
  21. Roelofs, A. J. et al. Fluorescent risedronate analogues reveal bisphosphonate uptake by bone marrow monocytes and localization around osteocytes in vivo. *Journal of Bone and Mineral Research* 25: 606-616 (2010).
  22. Murray, C. E. & Coleman, C. M. Impact of diabetes mellitus on bone health. *International Journal of Molecular Sciences* vol. 20 Preprint at <https://doi.org/10.3390/ijms20194873> (2019).
  23. Rahimi-Nedjat, R. K., Sagheb, K., Pabst, A., Olk, L. & Walter, C. Diabetes mellitus and its association to the occurrence of medication-related osteonecrosis of the jaw. *Dent J (Basel)* 4, (2016).
  24. Leite, F. R. M., Nascimento, G. G., Scheutz, F. & López, R. Effect of Smoking on Periodontitis: A Systematic Review and Meta-regression. *American Journal of Preventive Medicine* vol. 54: 831-841 Preprint at <https://doi.org/10.1016/j.amepre.2018.02.014> (2018).
  25. McGowan, K., McGowan, T. & Ivanovski, S. Risk factors for medication-related osteonecrosis of the jaws: A systematic review. *Oral Diseases* vol. 24: 527-536 Preprint at <https://doi.org/10.1111/odi.12708> (2018).
  26. Kuroshima, S., Sasaki, M., Murata, H. & Sawase, T. Medication-related osteonecrosis of the jaw-like lesions in rodents: A comprehensive systematic review and meta-analysis. *Gerodontology* vol. 36: 313-324 Preprint at <https://doi.org/10.1111/ger.12416> (2019).
  27. Kuroshima, S., Sasaki, M. & Sawase, T. Medication-related osteonecrosis of the jaw: A literature review. *Journal of Oral Biosciences* vol. 61: 99-104 Preprint at <https://doi.org/10.1016/j.job.2019.03.005> (2019).
  28. Hoefert, S., Schmitz, I., Tannapfel, A. & Eufinger, H. Importance of microcracks in etiology of bisphosphonate-related osteone-

- crosis of the jaw: A possible pathogenetic model of symptomatic and non-symptomatic osteonecrosis of the jaw based on scanning electron microscopy findings. *Clin Oral Investig* 14: 271-284 (2010).
29. Yarom, N. et al. Medication-Related Osteonecrosis of the Jaw: MASCC/ISOO/ASCO Clinical Practice Guideline. *J Clin Oncol* 37: (2019).
  30. Voss, P. J., Poxleitner, P., Schmelzeisen, R., Stricker, A. & Semper-Hogg, W. Update MRONJ and perspectives of its treatment. *Journal of Stomatology, Oral and Maxillofacial Surgery* vol. 118: 232-235 Preprint at <https://doi.org/10.1016/j.jormas.2017.06.012> (2017).
  31. Rosella, D. et al. Medication-related osteonecrosis of the jaw: Clinical and practical guidelines. *Journal of International Society of Preventive and Community Dentistry* vol. 6: 97-104 Preprint at <https://doi.org/10.4103/2231-0762.178742> (2016).
  32. Bermúdez-Bejarano, E. B. et al. Prophylaxis and antibiotic therapy in management protocols of patients treated with oral and intravenous bisphosphonates. *J Clin Exp Dent* 9: e141-e149 (2017).
  33. Pardo-Zamora, G., Martínez, Y., Moreno, J. A. & Ortiz-Ruiz, A. J. Treatment of stage 2 medication-induced osteonecrosis of the jaw: A case series. *Int J Environ Res Public Health* 18: 1-18 (2021).
  34. Marx, R. E., Sawatari, Y., Fortin, M. & Broumand, V. Bisphosphonate-induced exposed bone (osteonecrosis/osteopetrosis) of the jaws: Risk factors, recognition, prevention, and treatment. *Journal of Oral and Maxillofacial Surgery* 63: 1567-1575 (2005).
  35. Barrientos Lezcano, F. J. et al. Osteonecrosis de Los Maxilares Inducida Por Bifosfonatos: Prevención y Actitud Terapéutica Bisphosphonate Induced Osteonecrosis of the Jaws: Prevention and Therapeutic Approach. (2007).
  36. Campisi, G., Bedogni, A. & Fusco, V. Giuseppina Campisi. Medication-Related Osteonecrosis of Jaws (MRONJ) Prevention and Diagnosis: Italian Consensus Update 2020 *International Journal of Environmental Research and Public Health* (2020) doi:<https://doi.org/10.3390/ijerph17165998>
  37. Hinson, A. M., Smith, C. W., Siegel, E. R. & Stack, B. C. Is bisphosphonate-related osteonecrosis of the jaw an infection? A histological and microbiological ten-year summary. *International Journal of Dentistry* vol. 2014 Preprint at <https://doi.org/10.1155/2014/452737> (2014).
  38. Alons, K., Kuijpers, S. C. C., Jong, E. de & van Merkesteyn, J. P. R. Treating low- and medium-potency bisphosphonate-related osteonecrosis of the jaws with a protocol for the treatment of chronic suppurative osteomyelitis: report of 7 cases. *Oral Surgery, Oral Medicine, Oral Pathology, Oral Radiology and Endodontology* 107, (2009).
  39. Junquera, L. M. & Martín-Granizo, R. Diagnóstico, Prevención y Tratamiento de La Osteonecrosis de Los Maxilares Por Bisfosfonatos. Recomendaciones de La Sociedad Española de Cirugía Oral y Maxilofacial (SECOM) \* Diagnosis, Prevention, and Treatment of Bisphosphonate-Associated Osteonecrosis of the Jaw. Recommendations of the Spanish Society of Oral and Maxillofacial Surgery (SECOM). *Rev Esp Cir Oral y Maxilofac* vol. 30 (2008).
  40. Heifetz-Li, J. J. et al. Systematic review of the use of pentoxifylline and tocopherol for the treatment of medication-related osteonecrosis of the jaw. *Oral Surgery, Oral Medicine, Oral Pathology and Oral Radiology* vol. 128: 491-497.e2 Preprint at <https://doi.org/10.1016/j.oooo.2019.08.004> (2019).
  41. Ferlito, S., Puzzo, S., Palermo, F. & Verzi, P. Treatment of bisphosphonate-related osteonecrosis of the jaws: Presentation of a protocol and an observational longitudinal study of an Italian series of cases. *British Journal of Oral and Maxillofacial Surgery* 50: 425-429 (2012).
  42. Bermúdez-Bejarano, E. B. et al. Prophylaxis and antibiotic therapy in management proto-

- cols of patients treated with oral and intravenous bisphosphonates. *J Clin Exp Dent* 9: e141-e149 (2017).
43. Fleiter, N. et al. Clinical use and safety of a novel gentamicin-releasing resorbable bone graft substitute in the treatment of osteomyelitis/osteitis. *Bone Joint Res* 3: 223-229 (2014).
  44. Chia, C. L. K., Shelat, V. G., Low, W., George, S. & Rao, J. The use of Collatamp G, local gentamicin-collagen sponge, in reducing wound infection. *Int Surg* 99: 565-570 (2014).
  45. Bagán, J. et al. Hospital (4) Head of the Medical Oncology Service in the Pontevedra 'Montecelo' Hospital (5) Hematology Registrar. Hematology Service, Salamanca University Hospital (2007).
  46. Wutzl, A. et al. Factors influencing surgical treatment of bisphosphonate-related osteonecrosis of the jaws. *Head Neck* 34: 194-200 (2012).
  47. Hinson, A. M., Siegel, E. R. & Stack, B. C. Temporal correlation between bisphosphonate termination and symptom resolution in osteonecrosis of the jaw: A pooled case report analysis. *Journal of Oral and Maxillofacial Surgery* 73: 53-62 (2015).
  48. Ruggiero SL, D. T. A. T. C. E. W. B. K. D. American Association of Oral and Maxillofacial Surgeons' Position Paper on Medication-Related Osteonecrosis of the Jaws-2022 Update. *J Oral Maxillofac Surg.* 80: 920-940 (2022).
  49. Aboalela, A. A. et al. The Effect of Antiresorptive Drug Holidays on Medication-Related Osteonecrosis of the Jaw: A Systematic Review and Meta-Analysis. *Cureus* (2022) doi:10.7759/cureus.30485
  50. Lorenzo-pouso, A. I. et al. Medication-related osteonecrosis of the jaw: A critical narrative review. *Journal of Clinical Medicine* vol. 10 Preprint at <https://doi.org/10.3390/jcm10194367> (2021).
  51. Terpos, E. et al. The use of bisphosphonates in multiple myeloma: Recommendations of an expert panel on behalf of the European Myeloma Network. *Annals of Oncology* vol. 20: 1303-1317 Preprint at <https://doi.org/10.1093/annonc/mdn796> (2009).
  52. Khan, A. A. et al. Canadian Consensus Practice Guidelines for Bisphosphonate Associated Osteonecrosis of the Jaw. (2008).
  53. D'Amato, S. et al. Resective surgery versus debridement in stage 2 medication-related osteonecrosis of the jaw. *Applied Sciences (Switzerland)* 11: (2021).
  54. Cicco, D. et al. Citation: Medication-Related Osteonecrosis of the Jaws: A Comparison of SICMF-SIPMO and AAOMS Guidelines. (2023) doi:10.3390/diagnostics
  55. Varoni, E. M. et al. Conservative management of medication-related osteonecrosis of the jaws (Mronj): A retrospective cohort study. *Antibiotics* 10: 1-16 (2021).
  56. Nicolatou-Galitis, O. et al. Medication-related osteonecrosis of the jaw: definition and best practice for prevention, diagnosis, and treatment. *Oral Surgery, Oral Medicine, Oral Pathology and Oral Radiology* vol. 127: 117-135 Preprint at <https://doi.org/10.1016/j.oooo.2018.09.008> (2019)
  57. Mozzati, M., Arata, V. & Gallesio, G. Tooth extraction in patients on zoledronic acid therapy. *Oral Oncol* 48: 817-821 (2012).
  58. Beth-Tasdogan, N. H., Mayer, B., Hussein, H. & Zolk, O. Interventions for managing medication-related osteonecrosis of the jaw. *Cochrane Database of Systematic Reviews* vol. 2017 Preprint at <https://doi.org/10.1002/14651858.CD012432.pub2> (2017).
  59. Hadad, H. et al. Beta tricalcium phosphate, either alone or in combination with antimicrobial photodynamic therapy or doxycycline, prevents medication-related osteonecrosis of the jaw. *Sci Rep* 12, (2022).
  60. Udagawa, N., Koide, M., Nakamura, M. & Takahashi, N. Minocycline to be used a potential anti-bone resorption agents due to the suppression of osteoclastic bone resorp-

- tion. in *Journal of Oral Biosciences* vol. 55: 16-22 (Japanese Association for Oral Biology, 2013).
61. Sacco R., Sartoretto S.C., de Brito Resende R.F., de Albuquerque Calasans-Maia J., Rossi A.M., de Souza Lima V.H., de Almeida Barros Mourão C.F., Granjeiro J.M., Yates J., Calasans-Maia M.D. The Use of Hydroxyapatite Loaded with Doxycycline (HADOX) in Dentoalveolar Surgery as a Risk-Reduction Therapeutic Protocol in Subjects Treated with Different Bisphosphonate Dosages. *Medicina (Kaunas)*. 2022 Dec 27; 59 (1): 46. doi: 10.3390/medicina59010046
  62. Shakeri, F., Tebyanian, H., Karami, A., Babavalian, H. & Tahmasbi, M. H. Effect of topical phenytoin on wound healing. *Trauma Mon* 22: (2017).
  63. Tabrizi, R., Arabi, A. M., Arabion, H. R. & Gholami, M. Jaw osteomyelitis as a complication in osteopetrosis. *Journal of Craniofacial Surgery* 21: 136-141 (2010).
  64. Shaw, J., Hughes, C. M., Lagan, K. M. & Bell, P. M. The clinical effect of topical phenytoin on wound healing: A systematic review. *British Journal of Dermatology* vol. 157: 997-1004 Preprint at <https://doi.org/10.1111/j.1365-2133.2007.08160.x> (2007).
  65. Er, N., Kasaboğlu, O. ğuzcan, Atabek, A., Öktemer, K. & Akkocaoğlu, M. Topical Phenytoin Treatment in Bimaxillary Osteomyelitis Secondary to Infantile Osteopetrosis: Report of a Case. *Journal of Oral and Maxillofacial Surgery* 64: 1160-1164 (2006).
  66. Karasneh, J. A., Al-Eryani, K., Clark, G. T. & Sedghizadeh, P. P. Modified protocol including topical minocycline in orabase to manage medication-related osteonecrosis of the jaw cases. *Journal of Oral Pathology and Medicine* 45: 718-720 (2016).
  67. Melicherik, P. et al. The effect of Vancomycin degradation products in the topical treatment of osteomyelitis. *Bratislava Medical Journal* 115: 796-799 (2014).
  68. Svejda, B. et al. Positionspapier zur medikamentenassoziierten Osteonekrose des Kiefers (MRONJ). *Stomatologie* 112: 241-246 (2015).
  69. Atalay, B. et al. Bisphosphonate-related osteonecrosis: Laser-assisted surgical treatment or conventional surgery? *Lasers Med Sci* 26: 815-823 (2011).
  70. Altay, M. A., Tasar, F., Tosun, E. & Kan, B. Low-level laser therapy supported surgical treatment of bisphosphonate related osteonecrosis of jaws: A retrospective analysis of 11 cases. *Photomed Laser Surg* 32: 468-475 (2014).
  71. Weber, J. B. B., Camilotti, R. S. & Ponte, M. E. Efficacy of laser therapy in the management of bisphosphonate-related osteonecrosis of the jaw (BRONJ): a systematic review. *Lasers in Medical Science* vol. 31: 1261-1272 Preprint at <https://doi.org/10.1007/s10103-016-1929-4> (2016).
  72. Latifyan, S., Genot, M. T. & Klustersky, J. Bisphosphonate-related osteonecrosis of the jaw: a review of the potential efficacy of low-level laser therapy. *Supportive Care in Cancer* 24: 3687-3693 (2016).
  73. Woo, S.-B., Hellstein, J. W. & Kalmar, J. R. Systematic Review: Bisphosphonates and Osteonecrosis of the Jaws. [www.annals.org](http://www.annals.org) (2006).
  74. Freiburger, J. J. et al. Hyperbaric Oxygen Treatment and Bisphosphonate-Induced Osteonecrosis of the Jaw: A Case Series. *Journal of Oral and Maxillofacial Surgery* 65: 1321-1327 (2007).
  75. Rollason, V. et al. Interventions for treating bisphosphonate-related osteonecrosis of the jaw (BRONJ). *Cochrane Database of Systematic Reviews* vol. 2016 Preprint at <https://doi.org/10.1002/14651858.CD008455.pub2> (2016).
  76. Ripamonti, C. I., Cislighi, E., Mariani, L. & Maniezzo, M. Efficacy and safety of medical ozone (O<sub>3</sub>) delivered in oil suspension appli-

- cations for the treatment of osteonecrosis of the jaw in patients with bone metastases treated with bisphosphonates: Preliminary results of a phase I-II study. *Oral Oncol* 47: 185-190 (2011).
77. Agrillo, A. et al. Ozone Therapy in the Treatment of Avascular Bisphosphonate-Related Jaw Osteonecrosis. (2007) DOI:10.1097/scs.0b013e31857261f
  78. Sim, I.-W. et al. Teriparatide Promotes Bone Healing in Medication-Related Osteonecrosis of the Jaw: A Placebo-Controlled, Randomized Trial. *J Clin Oncol* vol. 38 <https://doi.org/10.1097/jco.2020.03.0000000000000000> (2020).
  79. Morishita, K. et al. Treatment outcomes of adjunctive teriparatide therapy for medication-related osteonecrosis of the jaw (MRONJ): A multicenter retrospective analysis in Japan. *Journal of Orthopaedic Science* 25: 1079-1083 (2020).
  80. dos Santos Ferreira, L. et al. Is teriparatide therapy effective for medication-related osteonecrosis of the jaw? A systematic review and meta-analysis. *Osteoporosis International* vol. 32: 2449-2459 Preprint at <https://doi.org/10.1007/s00198-021-06078-z> (2021).
  81. Cheung, A. & Seeman, E. Teriparatide Therapy for Alendronate-Associated Osteonecrosis of the Jaw. *New England Journal of Medicine* 363: 2473-2474 (2010).
  82. Epstein, M. S., Wicknick, F. W., Epstein, J. B., Berenson, J. R. & Gorsky, M. Management of bisphosphonate-associated osteonecrosis: Pentoxifylline and tocopherol in addition to antimicrobial therapy. An initial case series. *Oral Surgery, Oral Medicine, Oral Pathology, Oral Radiology and Endodontology* 110: 593-596 (2010).
  83. Cavalcante, R. C. & Tomasetti, G. Pentoxifylline and tocopherol protocol to treat medication-related osteonecrosis of the jaw: A systematic literature review. *Journal of Cranio-Maxillofacial Surgery* vol. 48: 1080-1086 Preprint at <https://doi.org/10.1016/j.jcms.2020.09.008> (2020).
  84. Colapinto, G. et al. Outcomes of a Pharmacological Protocol with Pentoxifylline and Tocopherol for the Management of Medication-Related Osteonecrosis of the Jaws (MRONJ): A Randomized Study on 202 Osteoporosis Patients. *J Clin Med* 12, (2023).
  85. Sun, X. K., Li, R., Yang, X. L. & Yuan, L. Efficacy and safety of topical oxygen therapy for diabetic foot ulcers: An updated systematic review and meta-analysis. *Int Wound J* 19: 2200-2209 (2022).
  86. Deliberador, T. M., Stutz, C., Sartori, E., Kluppel, L. & de Freitas, R. M. Treatment of Medication-Related Osteonecrosis of the Jaws (MRONJ) with Topical Therapy Using Active Oxygen Gel. *Clin Cosmet Investig Dent* 16: 249-254 (2024).
  87. Baumhoer, D. Bone-Related Lesions of the Jaws. *Surgical Pathology Clinics* vol. 10: 693-704 Preprint at <https://doi.org/10.1016/j.path.2017.04.007> (2017).
  88. Santos, G. N. M. et al. Radiomics in bone pathology of the jaws. *Dentomaxillofacial Radiology* vol. 52 Preprint at <https://doi.org/10.1259/dmfr.20220225> (2023).
  89. Parekh, V. & Jacobs, M. A. Radiomics: a new application from established techniques. *Expert Review of Precision Medicine and Drug Development* vol. 1: 207-226 Preprint at <https://doi.org/10.1080/23808993.2016.1164013> (2016).
  90. Park, J. E. et al. Quality of science and reporting of radiomics in oncologic studies: room for improvement according to radiomics quality score and TRIPOD statement. *Eur Radiol* 30: 523-536 (2020).
  91. Di Ianni, M. et al. Mesenchymal cells recruit and regulate T regulatory cells. *Exp Hematol* 36: 309-318 (2008).

92. Kikuri, T. et al. Cell-based immunotherapy with mesenchymal stem cells cures bisphosphonate-related osteonecrosis of the jaw-like disease in mice. *Journal of Bone and Mineral Research* 25: 1668-1679 (2010).
93. Bouland, C. L. et al. Treatment of medication-related osteonecrosis of the jaw with cell therapy. *Front Cell Dev Biol* 12, (2024).
94. Anderson, K. et al. JOURNAL OF CLINICAL ONCOLOGY Role of Bone-Modifying Agents in Multiple Myeloma: American Society of Clinical Oncology Clinical Practice Guideline Update. *J Clin Oncol* 36: 812-818 (2018).
95. Bertoldo, F. et al. Medication related osteonecrosis (MRONJ) in the management of CTIBL in breast and prostate cancer patients. Joint report by SIPMO AND SIOMMMS. *J Bone Oncol* 50, (2025).
96. Cicco, D. et al. Citation: Medication-Related Osteonecrosis of the Jaws: A Comparison of SICMF-SIPMO and AAOMS Guidelines. (2023) doi:10.3390/diagnostics.
97. Mücke, T. et al. Prevention of bisphosphonate-related osteonecrosis of the jaws in patients with prostate cancer treated with zoledronic acid – A prospective study over 6 years. *Journal of Cranio-Maxillofacial Surgery* 44: 1689-1693 (2016).
98. Bedogni, A. et al. Italian position paper (SIPMO-SICMF) on medication-related osteonecrosis of the jaw (MRONJ). *Oral Diseases* vol. 30: 3679-3709 Preprint at <https://doi.org/10.1111/odi.14887> (2024).
99. Ristow, O. et al. Wound closure and alveoplasty after preventive tooth extractions in patients with antiresorptive intake-A randomized pilot trial. *Oral Dis* 27: 532-546 (2021).
100. Liu, C. et al. Management of Tooth Extraction in Patients Taking Antiresorptive Drugs: An Evidence Mapping Review and Meta-Analysis. *Journal of Clinical Medicine* vol. 12 Preprint at <https://doi.org/10.3390/jcm12010239> (2023).
101. Kyrgidis, A., Arora, A., Lyroudia, K. & Antoniadis, K. Root canal therapy for the prevention of osteonecrosis of the jaws: An evidence-based clinical update. *Australian Endodontic Journal* 36: 130-133 (2010).
102. AAE Position Statement. <https://www.aae.org/specialty/wp-content/uploads/sites/2/2017/07/bisphosonatesstatement.pdf> (2010).
103. Colleagues for Excellence ENDODONTICS. [www.aae.org/colleagues](http://www.aae.org/colleagues) (2012)