



CASE REPORT:

Management of Post-Extraction Orthodontic Relapse Using Miniplate Anchorage: A Case Report

Manejo de la recidiva ortodóntica post-extracción mediante anclaje con miniplaca:
un reporte de caso

A. T. Prakash B.D.S., M.D.S., M.Orth.RCSEd.¹ <https://orcid.org/0000-0001-5013-0370>

Nikunj Maniyar B.D.S., M.D.S.² <https://orcid.org/0000-0002-3801-7313>

Amarnath P. Upasi B.D.S., M.D.S.³ <https://orcid.org/0000-0003-2095-7347>

¹Professor & Head, Department of Orthodontics and Dentofacial Orthopedics, College of Dental Sciences, Davangere, Karnataka, India.

²Assistant Professor, Department of Orthodontics and Dentofacial Orthopedics, Ahmedabad Dental College and Hospital, Bhadaj, Ahmedabad, Gujarat, India.

³Professor, Department of Oral & Maxillofacial Surgery, Bapuji Dental College and Hospital, Davangere, Karnataka, India.

Correspondence to: Nikunj Maniyar - maniar09@gmail.com

Received: 26-VIII-2025

Accepted: 29-I-2026

ABSTRACT: Orthodontic relapse, particularly after extraction-based treatment and compromised anchorage control situation, remains a clinical as well as esthetic challenge. This case report presents the successful re-treatment of a 24-year-old female patient with a relapsed malocclusion, proclined incisors, molar crossbites, and lip protrusion, following prior fixed orthodontic therapy with extraction of four premolars. Miniplate-assisted maxillary arch distalization was employed to accomplish en-masse retraction, correct molar relationship, and improve facial profile. The use of temporary skeletal anchorage device such as miniplates imparted steady, compliance-free mechanics, ensuing enhanced dental occlusion and soft tissue harmony. Here we highlight the effectiveness of miniplate-based mechanics in complex retreatment circumstances where traditional anchorage generally proves to be inefficient.

KEYWORDS: Distalization; Orthodontic re-treatment; Miniplates; Relapse; Temporary anchorage device.

RESUMEN: La recidiva ortodóntica, particularmente después de tratamientos basados en extracciones y en situaciones de control de anclaje comprometido, continúa representando un desafío tanto clínico como estético. Este reporte de caso presenta el retratamiento exitoso de una paciente femenina de 24 años con maloclusión recurrente, incisivos proclinados, mordidas cruzadas molares y protrusión labial, tras haber recibido previamente terapia ortodóntica fija con extracción de cuatro premolares. Se empleó distalización del arco maxilar asistida por miniplacas para lograr la retracción en masa, corregir la



relación molar y mejorar el perfil facial. El uso de dispositivos de anclaje esquelético temporal, como las miniplacas, proporcionó una mecánica estable y libre de dependencia de la cooperación del paciente, lo que permitió obtener una mejor oclusión dental y una adecuada armonía de los tejidos blandos. En este reporte se destaca la efectividad de la mecánica basada en miniplacas en situaciones complejas de retratamiento, en las cuales el anclaje tradicional suele resultar ineficiente.

PALABRAS CLAVE: Distalización; Retratamiento ortodóntico; Miniplacas; Recaída; Dispositivo de anclaje temporal.

INTRODUCTION

Recent years have seen a considerable surge in the adult patients seeking for orthodontic treatment; many of which reports to have undergone orthodontic treatment previously during their childhood or adolescence. Few of the many reasons that motivates the patient to undertake retreatment may be to address reopening of extraction spaces or relapse of lower anterior crowding owing to poor retention compliance. Additionally, retreatment may be necessary to ameliorate ineffectually addressed dental as well as facial aesthetics during previous orthodontic treatment (1). Owing to their former orthodontic experience, such patients seeking retreatment may have demanding standards in terms of treatment time, outcomes, and aesthetics of the chosen appliance (2). This increased cognizance tends to make them more judicious in treatment plan selection and appliance options. Most of the literature available on adult orthodontics focuses on first-time treatment, with very limited studies or case reports dedicated on managing complex retreatment cases — often in scenarios where former fiascos intensify caution and reduce risk tolerance for both patient and clinician (1). Additionally, the complexity increases when the case has been previously treated with extraction of all first premolars and further removal of teeth cannot be warranted. Total arch distalization of maxillary dentition is one of the viable choices to correct such orthodontic relapse with numerous appliances been developed to achieve this, yielding positive clinical outcomes.

Temporary skeletal anchorage device (TSAD) has revolutionized maxillary arch distalization by curtailing patient compliance and unsolicited reciprocal effects. Although miniscrews are frequently used, they are associated with few drawbacks that include fracture during placement, high failure rates, root impingement and subsequent need for repositioning. On the contrary, miniplates furnish better stability, improved precision, reduced treatment time, enhanced aesthetics, and trivial interference with root structures due to their tactical location. These key attributes compel miniplate-assisted distalization especially effective for complex tooth movements. However, literature on their clinical applications particularly in orthodontic retreatment remains limited (3). The present case report highlights use of miniplates for en-masse maxillary distalization in a patient opting for orthodontic retreatment, emphasizing their potential in management of such challenging cases.

CASE REPORT

DIAGNOSIS AND ETIOLOGY

A 24-year-old female patient walks into our private clinic with the chief complaint of protrusive upper front teeth and exhibited a desire to get them corrected. Upon questioning her medical history was non-contributory; however, she reported of having undergone orthodontic treatment around one year ago. During further interrogation she described that her previous

orthodontic treatment spanned over 27 months and involved extraction of all four first pre-molars for the anticipated correction. Unfortunately, she was unable to provide any previous treatment records or radiographs. On extra-oral examination, patient presented with a mesofacial form, convex profile, average growth pattern, potentially incompetent lips, acute nasolabial angle and deep mentolabial fold. The visual treatment objective (VTO) assessment of her profile was positive. Intra-oral evaluation suggested that her oral hygiene status was satisfactory with an adequate width of attached gingiva. All the first premolars were absent, which was consistent with her history of extraction-based orthodontic treatment. End-on molar and canine relationships were noted bilaterally with all first molars in

crossbite. Incisor relation was Class II Division 1 with overjet of 6 mm and deep overbite of 5 mm. A midline diastema was observed in the maxillary arch. Arch length discrepancies measured were 0.8 mm in the upper arch and 2.8 mm in the lower arch (Figure 1). Panoramic radiograph confirmed absence of all the third molars and demonstrated that her periodontal condition was healthy. Lateral cephalometric radiograph analysis (Table 1) revealed a mild skeletal Class II relation with ANB of 5° and average Frankfort mandibular plane angle of 26° . Maxillary and mandibular incisors were proclined and anteriorly positioned, with values of 31° and 10mm for the maxillary incisors and 34° and 6mm for the mandibular incisors. The upper and lower lips were protrusive by 4 mm and 3 mm, respectively (Figure 2).

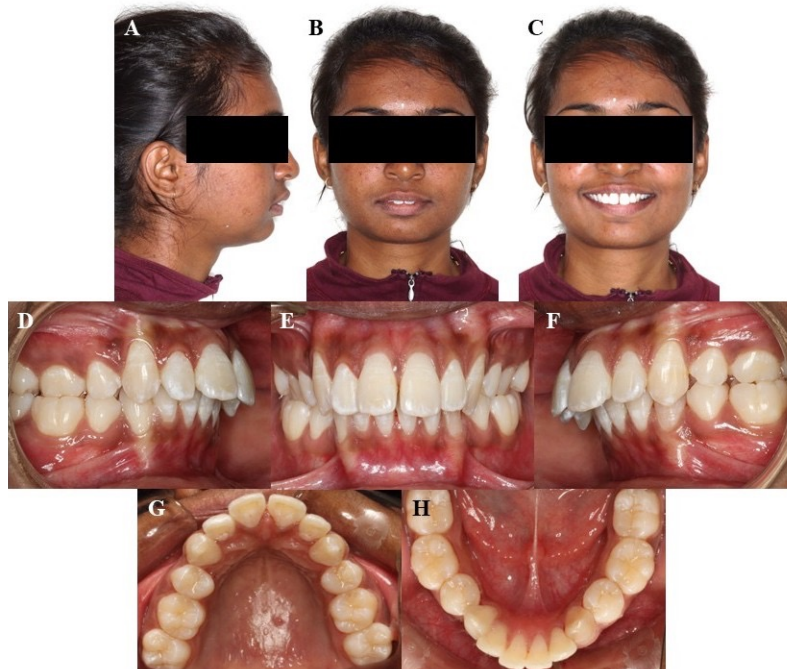
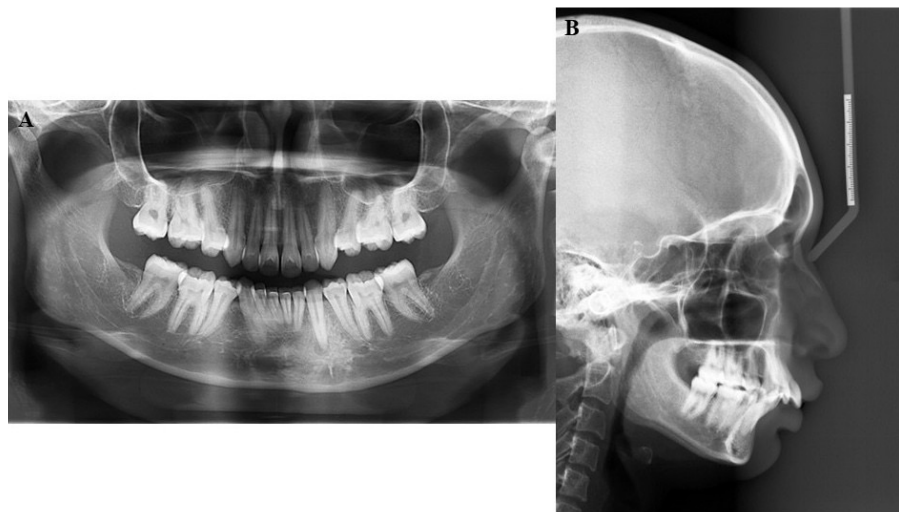


Figure 1. Pre-treatment photographs (A-C) Extra-oral (D-H) Intra-oral.

Table 1. Cephalometric changes between Pre- and Post-treatment records.

Variables	Norm	Pre-treatment	Post-treatment
SNA (°)	82°	81°	81°
SNB (°)	80°	76°	76°
ANB (°)	2°	5°	5°
GoGn – SN (°)	32°	26°	28°
LAFH (mm)	-	65mm	67mm
Facial axis (°)	0°	+2°	+3°
U1 – NA (°)	22°	31°	22°
U1 – NA (mm)	4mm	10mm	5mm
U1 – SN (°)	102°	117°	111°
L1 – NB (°)	25°	34°	31°
L1 – NB (mm)	4mm	6mm	5mm
IMPA (°)	90°	112°	109°
S line – UL (mm)	-2mm	4mm	1mm
S line – LL (mm)	0mm	3mm	2mm

**Figure 2.** Pre-treatment radiographs (A) Panoramic radiograph, (B) Lateral cephalogram.

TREATMENT OBJECTIVES

Objectives of orthodontic re-treatment for this patient were: (1) To level and align both the dental arches with retraction of upper and lower incisors to achieve optimum overjet and overbite, (2) To achieve bilateral Class I canine and molar relationships and correct the molar crossbites, (3) To improve the facial profile by retracting upper

and lower lips and, (4) To attain balanced and aesthetically pleasing soft tissue harmony.

TREATMENT ALTERNATIVES

Based on the planned treatment objectives, several treatment options were considered for managing the patient's relapsed malocclusion, particularly proclined incisors and molar crossbi-

tes. A conventional fixed appliance therapy along with the use of intraoral elastics or anchorage-reinforced mechanics such as transpalatal arch and Nance button was contemplated; however, these approaches carry the risk of anchorage loss, especially in cases with compromised extraction space closure. Patient's unwillingness to undergo invasive surgical procedures ruled out the option of orthognathic surgery. Considering the need for significant en-masse retraction, crossbite correction, and profile enhancement without relying on patient compliance, temporary skeletal anchorage using miniplates in maxilla for total arch distalization was selected as the final treatment modality. Use of other temporary anchorage devices such as miniscrews could also have been explored in this case, but concerns regarding their stability, potential root interference, and the need for repositioning as the treatment progresses limited their predictability here. On the contrary, miniplate-assisted distalization offered more stable anchorage, efficient force application, and minimal reciprocal effects, aligning well with the patient's clinical needs and aesthetic expectations.

TREATMENT PROGRESS

Treatment was initiated with bonding of all the teeth with 0.022" X 0.028" passive self-ligating brackets. Succeeding the initial phase of arch levelling and aligning, full thickness mucoperiosteal flaps were elevated and 'Y'-shaped miniplates were affixed within the zygomatic buttress region of the maxilla bilaterally using three monocortical screws, each of 2.0 mm in diameter and 6.0 mm in length (Figure 3). The surgical flap was reoriented and sutured with resorbable sutures exposing only the head portion of the mini-plates in the oral cavity. A 0.017" X 0.025" stainless steel archwire was engaged with the wire ends tightly cinched and distalizing forces were applied to the upper arch using e-chain stretched from the mini-plate hooks (Figure 4). The force on

each side was measured to be 200 gm. Hence, a total force of 400 gm was applied for whole arch distalization of maxillary dentition. Force reactivation was done once in every 6 weeks and the miniplate sites were examined intermittently for stability and soft tissue proliferation.

Distalization continued for six months at the end of which Class I molar and canine relationships were achieved bilaterally with optimum overjet and overbite. Miniplates were later removed and appliances debonded after an active treatment duration of 20 months. Retention phase included use of full-time wear of removable clear retainers for the first 6 months followed by only night-time wear to warrant the continuing preservation of treatment outcomes achieved.

TREATMENT RESULTS

End of the orthodontic re-treatment marked with a significant improvement in patient's profile, reducing the midfacial convexity and enhancing lip competency successive to reduction in dental protrusion. We achieved Class I canine and molar relationship bilaterally with optimum overjet and overbite of 3mm. The upper and lower dental midlines were coincident with good interdigitations. Precise incisor and canine guidance in protrusive and lateral excursions were established without any occlusal interferences (Figure 5 & Figure 6).

Pre- and post-treatment lateral cephalometric superimposition revealed dentoalveolar changes wherein the maxillary incisors were uprighted from 117° to 111° and retracted by 5mm whereas, the mandibular incisors were minimally uprighted from 111° to 109° (Table 1). Opening of the facial axis consequent to increase in mandibular plane by was also noted. Maxillary first molars were distalized by a total of 4.8 mm. Upper and lower lip to S-line distance reduced by 3 mm and 1 mm, respectively.

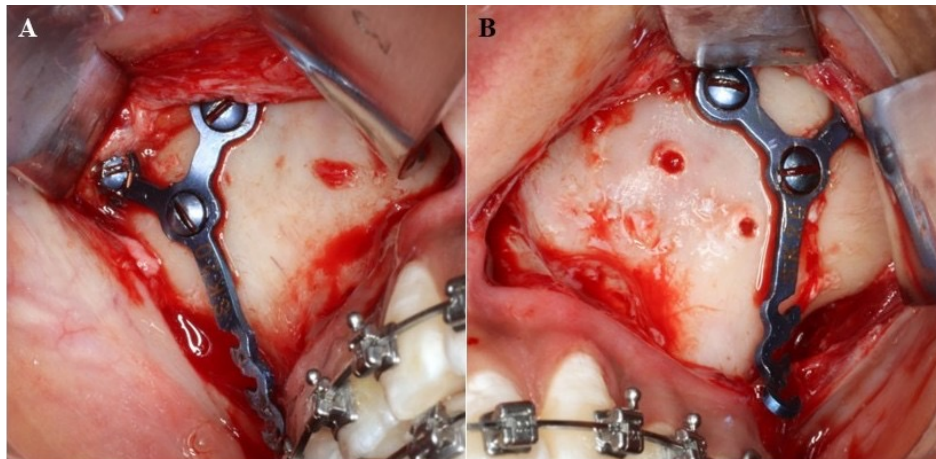


Figure 3. 'Y'-shaped mini-plates placed in the zygomatic buttress region of the maxilla (A) Right side, (B) Left side.

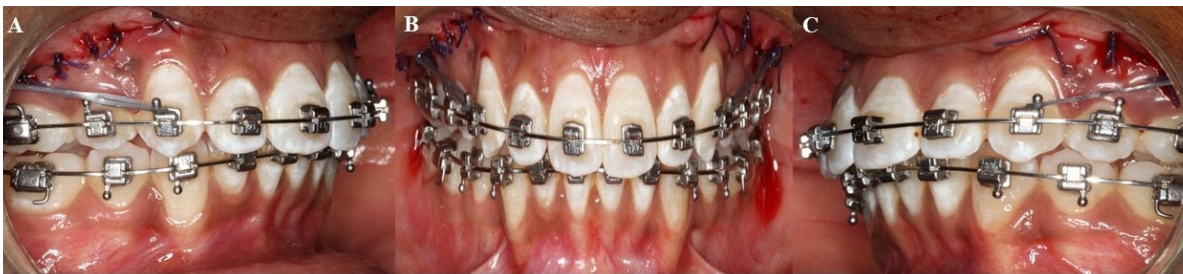

Figure 4. (A-C) 0.017" X 0.025" stainless steel archwire with distalizing forces using e-chain stretched from the miniplate to canine bracket hook bilaterally.

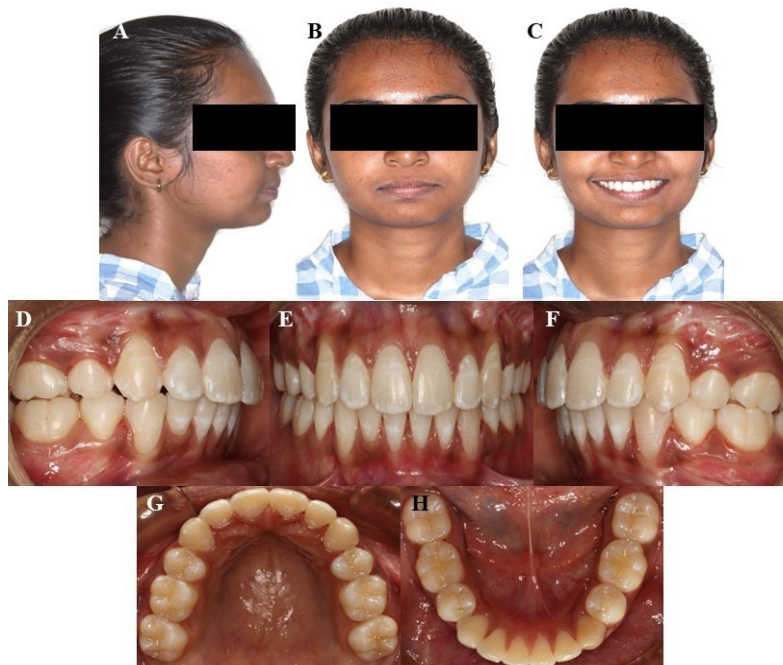


Figure 5. Post-treatment photographs (A-C) Extra-oral (D-H) Intra-oral.

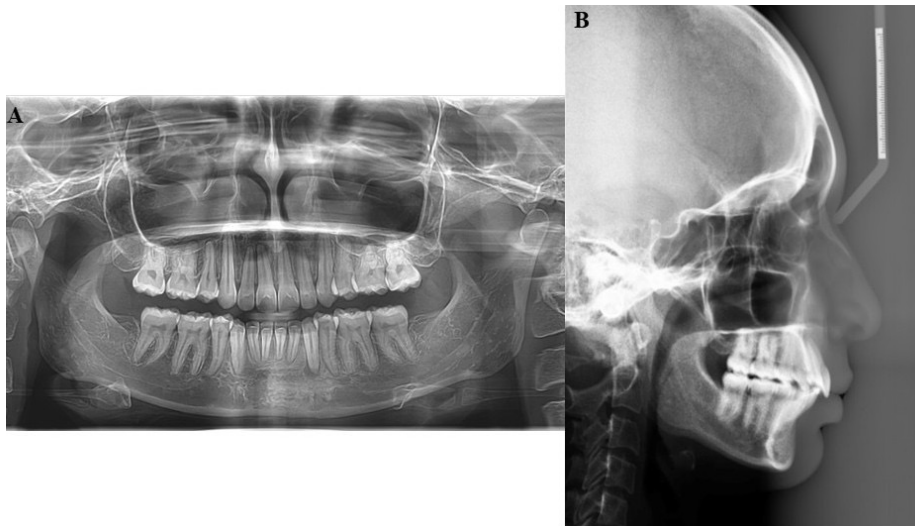


Figure 6. Post-treatment radiographs (A) Panoramic radiograph, (B) Lateral cephalogram.

DISCUSSION

Recent years have seen a considerable surge in reports of orthodontic re-treatments with approximately 29.6% to 50.7% of patients who have previously undergone orthodontic treatment seek treatment again (4). Choices for retreatment may be associated to the verity that the outcomes of the previous orthodontic treatment were not ideal or satisfactory (5). This, however, can be attributed to a wide variety of reasons including unfavourable skeletal growth pattern during or after treatment completion, non-compliance during the treatment and mid-course treatment discontinuation (5, 6). Relapse after orthodontic treatment in extraction cases represents unique biomechanical and psychological challenges, frequently ascribed to incomplete space closure, unstable anchorage, and inadequate retention protocols (7). In the present case, recurrence of incisor proclination and end-on molar relation within a span of a year post treatment can be attributed to either anchorage loss or unstable occlusal and soft tissue relationships.

Conventional intraoral anchorage techniques may not prove to be adequate in resisting the

reactive forces during anterior retraction, particularly in cases requiring maximum anchorage (8). Miniscrew devices, though easy to place, presents with certain limitations. On the contrary, miniplates offer a robust extra-alveolar skeletal anchorage alternative with greater stability and load-bearing capacity, predominantly suited for complex distalization cases. Owing to their extra-alveolar locations like infrazygomatic crest or mandibular buccal shelf, miniplates permit application of high-magnitude, continuous force vectors facilitating significant distalization and intrusive tooth movements without any risk to adjacent roots or periodontal structures (9).

Reports, though very few, exists in the literature highlighting the utility of miniplates in en-masse distalization of maxillary arch (3, 9). However, its potential advantage in cases of re-treatment is less explored. In the present case, we report bilateral infrazygomatic miniplates aided active maxillary arch distalization, resolving posterior teeth disparities along with retraction of maxillary anterior segment in a young adult patient seeking for orthodontic re-treatment. At the end of the treatment, in addition to a stable occlusal inter-

cuspatation, we achieved marked soft tissue enhancement, remarkably with the retraction of protrusive lips and harmonization of the facial profile. Our results support the growing body of evidence favouring miniplate-based mechanics as a consistent modality for anchorage-intensive retreatment cases. Stability of the treatment outcome is a crucial consideration in orthodontic cases. In this instance, we followed miniplate-assisted distalization with comprehensive orthodontic finishing and detailing to fine-tune the patient's bite and make any necessary adjustments. Patients' comfort and compliance are vital aspects in orthodontic treatment and their importance is even more significant for those who undergo treatment again. Use of miniplates lessens the dependence on patients to maintain compliance and eliminates the need for cumbersome extraoral appliances like headgear (10). Patient in this case testified minimal discomfort and inconvenience during the entire treatment, making this approach more appealing to those who may be averse to traditional orthodontic methods.

It is imperative to heed that miniplate-assisted distalization may not be universally applicable to all re-treatment cases requiring distalization and that effective results depend on apposite case selection, explicit surgical placement, and thorough clinical expertise. Besides, the surgical nature of miniplate insertion involves risks such as pain, swelling, infection, and the need for a second procedure for removal following accomplishment of its purpose. One must carefully consider all these factors against the estimated treatment benefits (11).

CONCLUSION

Miniplate-assisted maxillary arch distalization substantiated to be an efficacious retreatment strategy in handling post-extraction relapse of

Class II malocclusion with molar crossbite and incisor proclination. This method purveyed definitive skeletal anchorage, aiding controlled tooth movement and momentous profile enhancement without reckoning on patient compliance. Vigilant case selection and surgical planning continues to be critical for superior clinical outcomes and to curtail complications.

FUNDING: This article was self-financed by the authors.

CONFLICT OF INTERESTS: The authors declare that there are no conflicting interests.

INFORMED CONSENT: Informed consent was provided by the patient for the publication of this case report.

AUTHOR CONTRIBUTION STATEMENT: Conceptualization and design, A.T.P. and N.M.; Literature review, N.M.; Investigation and data collection, A.T.P. and A.P.U.; Data analysis and interpretation, A.T.P., N.M. and A.P.U.; Writing-original draft preparation, A.T.P. and N.M.; Writing-review & editing, A.T.P., N.M. and A.P.U.; Supervision: A.T.P.

REFERENCES

1. Chow L., Goonewardene M.S., Cook R., Firth M.J. Adult orthodontic retreatment: A survey of patient profiles and original treatment failings. *Am J Orthod Dentofacial Orthop.* 2020; 158 (3): 371-82.
2. Santiago R.C., da Silva Campos M.J., Vitral R.W.F., Vieira R.A., Nojima L.I., Sant'Anna E.F. Characteristics of patients seeking orthodontic retreatment. *J World Fed Orthod.* 2022; 11 (1): 36-40.
3. Maniyar N., Prakash A., Kumar K. Optimizing correction of class II malocclusion with miniplate-assisted en-masse maxillary arch distalization: A Case Report. *J Oral Res.* 2025; 14 (1): 69-80.

4. Ranasinghe A. and Babu H. Incidence of patients seeking retreatment of malocclusion reporting to the institution over 1 year period. *J Res Med Dent Sci.* 2022; 10 (11): 148-52.
5. Berg R. Post retention analysis of treatment problems and failures in 264 consecutively treated cases. *Eur J Orthod.* 1979; 1 (1): 55-68.
6. Karşlı N., Ocak I., Gülnar B., Tüzüner T., Littlewood S.J. Patient perceptions and attitudes regarding post-orthodontic treatment changes. *Angle Orthod.* 2023; 93 (4): 440-6.
7. Little R.M., Riedel R.A., Artun J. An evaluation of changes in mandibular anterior alignment from 10 to 20 years postretention. *Am J Orthod Dentofacial Orthop.* 1988; 93 (5): 423-8.
8. Proffit W.R., Fields H.W., Sarver D.M. *Contemporary Orthodontics.* 6th ed. St. Louis: Mosby; 2019.
9. Sugawara J., Kanzaki R., Takahashi I., Nagasaka H., Nanda R. Distal movement of mandibular molars in adult patients with skeletal anchorage system. *Am J Orthod Dentofacial Orthop.* 2006; 129 (6): 723-33.
10. Kim S., Herring S., Wang I., et al. A comparison of miniplates and teeth for orthodontic anchorage. *Am J Orthod Dentofacial Orthop.* 2008; 133 (2): 189.e1-9.
11. Tsui W.K., Chua H.D., Cheung L.K. Bone anchor systems for orthodontic application: a systematic review. *Int J Oral Maxillofac Surg.* 2012; 41 (11): 1427-38.