



CLINICAL RESEARCH:

Relationship Between the Maturation of the Midpalatal Suture and the Mineralization of the Mandibular Second and Third Molars

Relación entre la maduración de la sutura palatina media y la mineralización de los segundos y terceros molares mandibulares

Luis Angel García-Gonzales DDS, MSc, PhD(c)¹ <https://orcid.org/0000-0003-0658-5145>

Roman Mendoza Lupuche DDS, MSc, PhD² <https://orcid.org/0000-0003-2089-8965>

¹PhD Candidate in Dentistry. Universidad Nacional Federico Villarreal, Lima, Perú. Specialist in Orthodontics and Maxillary Orthopedics, Specialist in Oral and Maxillofacial Radiology, Master in Stomatology, Lima, Perú.

²Specialist in Periodontics and Implantology, Master in Teaching and Research, Lima, Perú. PhD in Dentistry. Universidad Nacional Federico Villarreal, Lima, Perú.

Correspondence to: Luis Angel García-Gonzales - luchetedent@gmail.com

Received: 3-IX-2025

Accepted: 13-XI-2025

ABSTRACT: To assess the relationship between the maturation of the midpalatal suture (MPS) and the mineralization stages of the mandibular second molar (M2) and third molar (M3) using cone-beam computed tomography (CBCT). A descriptive, cross-sectional, retrospective, and correlational study was conducted. Of 456 available CBCT scans, 121 that met the selection criteria were evaluated. Patients' ages ranged from 5 to 30 years and were distributed into five previously established age groups. A non-stratified sampling method was used to include all eligible cases and avoid data loss. Tomographic images were analyzed to determine the maturation stage of the MPS according to Angelieri's method, and the mineralization stages of M2 and M3 were assessed using Demirjian's classification. The correlation between MPS maturation and M2 mineralization showed a coefficient of 0.574, while the correlation between MPS maturation and M3 mineralization was 0.548; both indicated a moderate positive correlation. Statistical analysis was performed using Spearman's correlation coefficient ($p \leq 0.05$). A significant relationship was found between midpalatal suture maturation and the mineralization of the mandibular second and third molars, enabling a more precise assessment of craniofacial development. Both sutural maturation and molar mineralization showed progressive advancement with chronological age, supporting their usefulness as biological growth indicators.

KEYWORDS: Cone beam computed tomography; Diagnostic imaging; Cranial sutures; Palate bone; Molar teeth; Third molar (MeSH).



RESUMEN: Relacionar la maduración de la sutura palatina media (SPM) y los estadios de mineralización del segundo molar mandibular (2MM) y tercer molar mandibular (3MM) mediante Tomografía computarizada cone beam (TCCB). Se realizó un estudio de tipo descriptivo, transversal, retrospectivo y correlacional. De 456 TCCB disponibles se evaluaron 121 que cumplieron con los criterios de selección. La edad de los pacientes de quienes se obtuvieron las tomografías se encontró en el rango de 5 a 30 años, las cuales fueron distribuidas en cinco grupos de edad previamente establecidos, se realizó un muestreo no estratificado para conservar todos los casos disponibles y así no perder información. Luego a partir de las tomografías se obtuvieron imágenes para determinar el estadio de maduración de la SPM mediante el método de Angelieri y los estadios mineralización del 2MM y 3MM mediante la clasificación de Demirjian. Se encontró que la relación de maduración de la SPM y el estadio de mineralización del 2MM presentó un coeficiente de 0.574 y que la relación de maduración de la SPM y estadios de mineralización del 3MM presentó un coeficiente de 0.548, en ambos casos una correlación positiva moderada. El análisis se realizó con el Coeficiente de Correlación de Spearman ($p \leq 0.05$). Se encontró una relación significativa entre la maduración de la sutura palatina media y la mineralización del segundo y tercer molar mandibular, lo cual permite una evaluación más precisa del desarrollo craneofacial. Tanto la maduración sutural palatina y la mineralización de las molares mostraron un avance progresivo en función de la edad cronológica, respaldando su utilidad como indicadores del crecimiento biológico.

PALABRAS CLAVE: Tomografía computarizada de haz cónico; Diagnóstico por imagen; Suturas craneales; Hueso paladar; Dientes molares; Tercer molar (DeCS).

INTRODUCTION

A relevant challenge in orthodontic practice is the management of transverse malocclusions due to their functional, aesthetic, and respiratory implications, which can significantly affect patients' quality of life. In particular, maxillary transverse deficiency or skeletal constriction is a common condition associated with posterior crossbite, dental crowding, and reduced arch space, as well as potential upper airway complications that may impact breathing and craniofacial development (1,2). Rapid maxillary expansion (RME) is considered the treatment of choice to correct these transverse discrepancies; however, the success of this therapy depends on several factors such as age, sex, degree of biological maturation, and especially the ossification stage of the midpalatal suture (MPS), whose bone resistance and potential for disjunction vary considerably depending on the stage of skeletal development (3,4).

During orthodontic treatment planning, assessing biological maturation is essential to determine the feasibility and optimal timing for applying orthopedic forces, thereby reducing risks and improving outcomes. Traditionally, hand-wrist and cervical vertebral radiographs have been used, along with dental indicators based on eruption and mineralization. However, chronological age is considered an unreliable marker due to the wide individual variability in growth and biological development (5). In this context, the method developed by Demirjian *et al.* (6) is recognized for its accessibility and accuracy in evaluating dental maturation, classifying the process into eight stages of mineralization. This method can be applied to specific teeth such as the mandibular second and third molars, which are relevant for studying development in adolescents and young adults (7,8). A recent study reported that molar mineralization may reflect skeletal maturation, even in Latin American populations (9). On the

other hand, MPS maturation has been described as highly variable among adolescents and adults, and a recent systematic review confirmed that chronological age is an unreliable predictor of such maturation, particularly in younger individuals (10,11).

Advances in imaging have improved diagnostic evaluation through Cone-Beam Computed Tomography (CBCT), which provides high-resolution three-dimensional images with relatively low radiation. This technique enables direct visualization of the midpalatal suture and accurate assessment of mandibular molars in panoramic reconstructions, allowing precise and integrated evaluation that supports individualized orthodontic treatment planning (12,13).

The analysis of the relationship between midpalatal suture maturation and the mineralization of the mandibular second and third molars using CBCT represents an innovative approach for assessing dental and skeletal diagnosis. This method enables a more precise determination of the optimal timing for orthopedic treatments such as rapid maxillary expansion, improving effectiveness and reducing complications. The aim of the present study was to evaluate this relationship in a sample of Peruvian patients.

MATERIAL AND METHODS

This study was approved by the Institutional Ethics Committee of the Universidad Nacional Federico Villareal (UNFV, Peru) under code 046-2025-UIIE-EUPG-UNFV. Data confidentiality was safeguarded through the coding of cone-beam computed tomography (CBCT) scans using consecutive random numbers. The design was correlational, descriptive, cross-sectional, and retrospective. The study population consisted of CBCT scans from the archive of patients who attended the private dental radiology center “Centro de Imágenes Life 3D” in Lima, Peru.

The sample size was calculated using the formula for correlational studies with a finite population, based on Spearman's correlation coefficient. The expected correlation was set at $r=0.30$, corresponding to a moderate association, with an acceptable margin of error of 5% and a 95% confidence level. A finite population correction was then applied, resulting in a sample size of 111. A total of 456 CBCT scans taken in 2023 and 2024 were reviewed, and 121 scans that met the inclusion and exclusion criteria were selected. All eligible scans were evaluated to ensure a more accurate representation of the population and greater reliability and precision of the results.

Inclusion criteria were CBCT scans performed for orthodontic diagnostic purposes, of medium field of view and good quality, from patients aged 5 to 30 years, with complete visualization of the MPS and M2 and M3. Exclusion criteria were CBCT scans of patients undergoing or with a history of orthodontic treatment, scans showing pathologies near the area of interest, signs of severe facial trauma or previous orthognathic surgery, agenesis or loss of both M2 or M3, or extensive restorative/prosthetic treatments involving these teeth.

The 121 CBCT scans were distributed into five predefined age groups (5-10 years, 11-15 years, 16-20 years, 21-25 years, and 26-30 years) based on the reviewed literature. Cases were assigned to each group according to their frequency in the sample. Stratified sampling was not performed, and group sizes were not equalized, since all available cases were preserved to avoid information loss and maintain the integrity of the final sample. A database was created including all scans that met the selection criteria. These were coded anonymously to prevent bias during evaluation.

The examiner responsible for all measurements was trained by a specialist in Oral and Maxillofacial Radiology (OMFR) with five years of experience, in the analysis of CBCT images and

the use of tomographic software. Interobserver calibration was performed with an OMFR specialist, and intraobserver calibration was carried out at two different time points, with a seven-day interval. Twelve randomly selected CBCT scans were used for both procedures. Agreement values were assessed using the Kappa index. Interobserver agreement was 0.745 for the MPS and 0.733 for the combined evaluation of the second and third mandibular molars. Intraobserver agreement was 0.625 for the MPS and 0.729 for the molars. These values correspond to a good to substantial level of agreement (14). Training and calibration procedures were conducted to ensure methodological efficiency, as well as validity, reliability, and reproducibility of the study results.

The CBCT scans were evaluated in a random sequence, and the variables were analyzed in two separate stages. Initially, the MPS was assessed in all scans, followed by the M2 and M3 on the left side.

Once the evaluation process was completed, the CBCT scans were organized according to the predefined age groups for analytical purposes, while maintaining the confidentiality of coded data.

VISUALIZATION OF THE MIDPALATAL SUTURE

The initial part of the protocol described by Angelieri *et al.* (15) was modified to obtain axial sections of the MPS, since this study was conducted using medium field-of-view CBCTs, which do not allow visualization of the entire craniofacial complex. The following steps were applied: the orientation of the tomographic volume was verified

and adjusted in all three planes of space, using the palate as reference; the software cursor was positioned in the midsagittal plane in both coronal and axial views; and in the sagittal view, the volume was adjusted to align the anteroposterior axis of the palate horizontally.

The axial slice to be analyzed was standardized. In the sagittal plane, the mid-sagittal transverse section was used to position the palate horizontally. A horizontal reference line was then traced along the palate to obtain the central transverse section in the vertical dimension, from the nasal to the oral surface (Figure 1). This procedure enabled the identification of the suture maturation stage according to the proposed classification (Figure 2): A, straight radiopaque line; B, scalloped high-density line; C, two parallel scalloped lines separated by hypodense areas; D, partial visualization of the suture, showing only two scalloped lines in the midline; and E, complete absence of the suture in the maxillary and palatine bones, indicating complete fusion (15).

In cases with a curved palate, two central axial slices were used, one for the anterior and one for the posterior region of the suture. A curved palate was defined when both regions could not be visualized in the same axial slice. In cases with a thick palate, evaluation was based primarily on central axial slices. A palate was considered thick when the MPS suture could be assessed in more than two slices (oral, central, and nasal).

All images were evaluated in Multiplanar Oblique Three-Dimensional Reconstruction (MPR) mode with a slice thickness of 0 mm.

VISUALIZATION OF THE MANDIBULAR SECOND AND THIRD MOLARS

To obtain the panoramic reformation, the manual panoramic curve tool was used, passing through all mandibular teeth and centered on the crowns.

Scans were assessed using MPR mode with a slice thickness of 10 mm, sufficient to include the buccolingual width of the mandibular second and third molars.

The mineralization stages were determined according to Demirjian's classification (6) (Figure 3), which consists of eight stages: A, initial cusp calcification; B, cusps mineralized and beginning to fuse; C, crown formation in progress with a defined occlusal surface and extension to half the crown; D, crown formation complete up to the cemento-enamel junction; E, initial root forma-

tion, roots shorter than the crown; F, root length greater than crown height with open apices; G, nearly complete root formation with minimal apical opening; and H, complete apical closure indicating full dental maturation.

In cases of agenesis of the left mandibular third molar, the right mandibular third molar was evaluated instead.

STATISTICAL ANALYSIS

Data were analyzed using SPSS v27. Descriptive statistics (mean, standard deviation, frequencies, and percentages) were calculated. Normality was assessed with the Kolmogorov-Smirnov test, which showed a non-normal distribution. Consequently, Spearman's rank correlation was applied, a non-parametric test suitable for ordinal or non-normally distributed variables. A significance level of 5% ($p < 0.05$) was adopted.

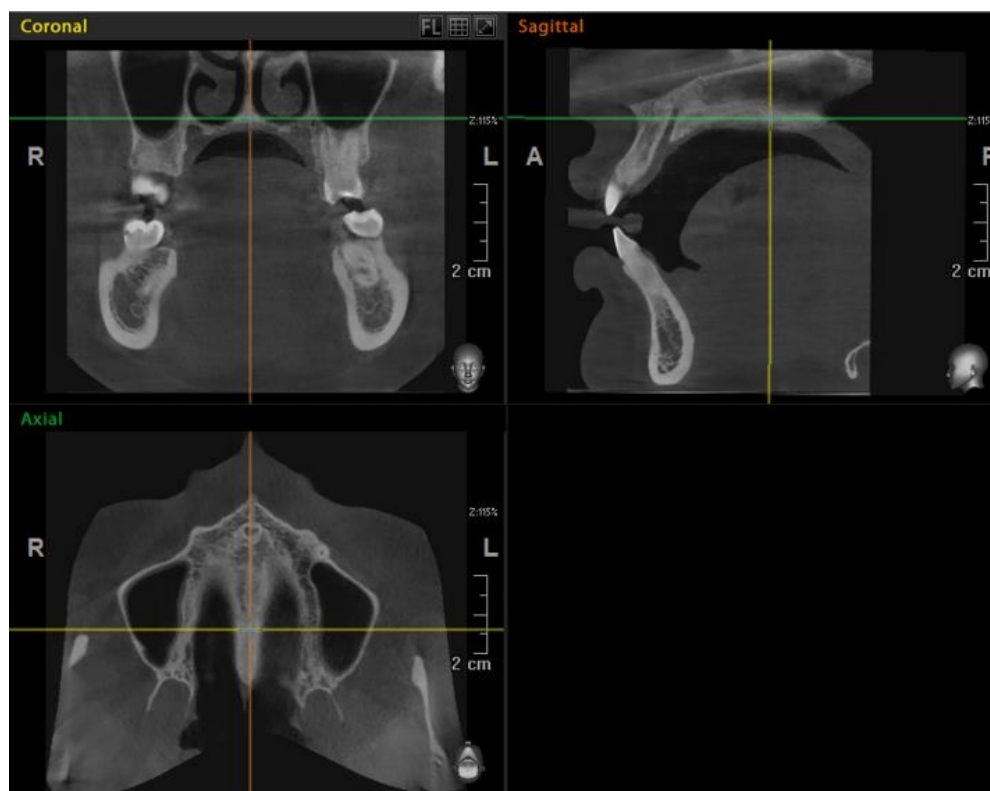

Figure 1. Image of standardization of the orientation of the tomographic volume to obtain the axial section to be evaluated. The position of the cursor in the coronal, sagittal and axial planes is observed.

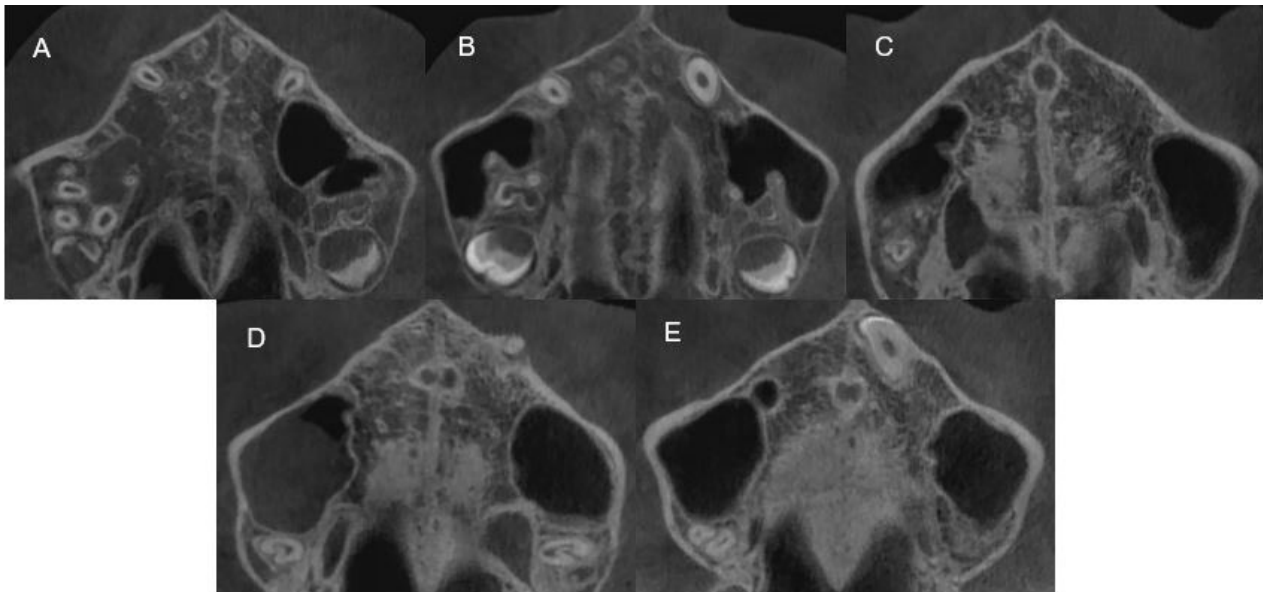


Figure 2. Angeliari *et al.* classification for MPS maturation in CBCT: A, straight radiopaque line; B, high-density scalloped line; C, two parallel lines separated by hypodense areas; D, partial suture visualization; E, complete absence of the suture indicating fusion.

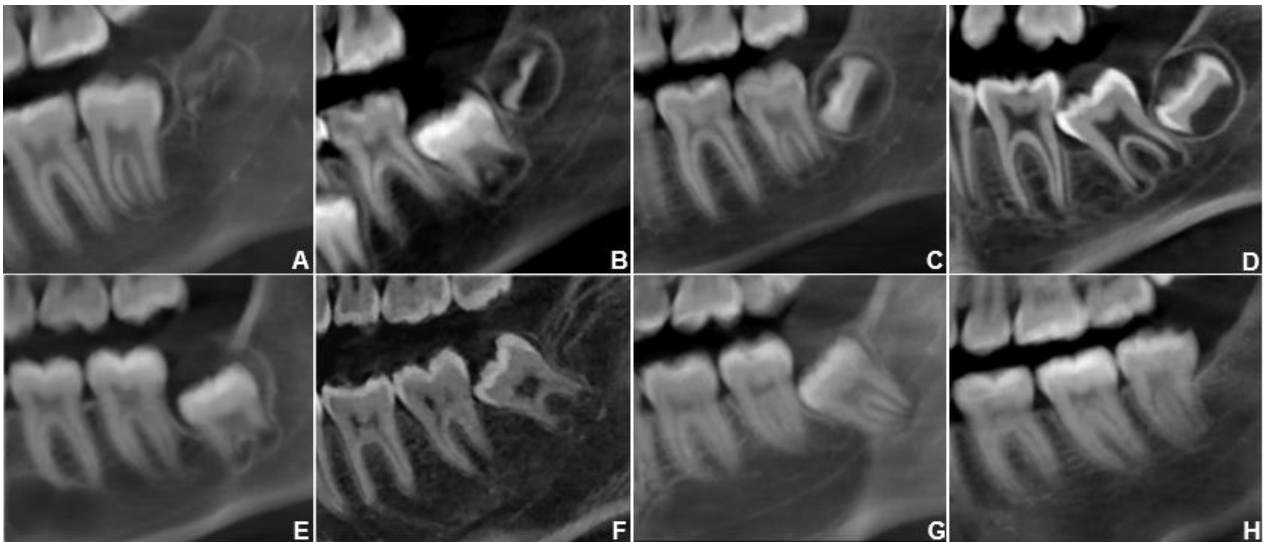

Figure 3. Demirjian *et al.* classification for mandibular molar mineralization in TCCB: A, onset of calcification; B, smelting mineralized cusps; C, crown halfway; D, crown completed; E, short roots; F, longer roots with open apices; G, apices almost closed; H, closed apices.

RESULTS

A defined progression in midpalatal suture (MPS) maturation was observed. Stages A-B were predominant in younger groups of (5 to <14 years), whereas stages D-E prevailed in older ages. In the 14-18-year group (n=44), 24 cases were in stage C, 9 in stage B, and none in stage A (Table 1).

Sex-related distribution was similar between males and females, with no relevant differences (Table 2).

For the mandibular second molar, early mineralization stages (C-E) were associated with early MPS maturation (A-B), while advanced stages (F-H) were related to intermediate and late phases

(C-E). Of 51 cases between C-G dental mineralization stages, only 3 corresponded to MPS stage D and none to stage E; in the total sample of 121 cases, 9 were located in stage E. Spearman's test showed a moderate positive correlation ($\rho=0.574$, $p<0.001$) (Table 3).

For the third molar, initial stages (A-D) were mostly related to early MPS maturation (A-B), while advanced stages (E-H) were more frequently associated with intermediate and late phases (C-E). Of 60 cases between A-E, only 5 were in MPS stage D or E; of 85 cases between A-G, only 2 were in stage E. In total, 9 of 121 cases were classified as stage E. Spearman revealed a positive correlation ($\rho=0.548$, $p<0.001$) (Table 4).

Table 1. Distribution of the stages of the midpalatal suture according to age group.

Stages of maturation of MPS	Age (years)										Total	
	5 to <10		10 to <14		14 to 18		>18 to 24		>24 to 30			
	n	%	n	%	N	%	n	%	n	%	n	%
To	6	4.97	2	1.65							8	6.62
B	7	5.79	18	14.88	9	7.44	2	1.65	1	0.82	37	30.58
C	2	1.65	10	8.26	24	19.83	7	5.79	5	4.13	48	39.66
D					10	8.26	5	4.13	4	3.31	19	15.7
E					1	0.82	4	3.31	4	3.31	9	7.44
Total	15	12.41	30	24.79	44	36.35	18	14.88	14	11.57	121	100.00

MPS, midpalatal suture.

Table 2. Distribution of the stages of the midpalatal suture according to age group and sex.

Stages of maturation of MPS	Sex	Age (years)										Total		
		5 to <10		10 to <14		14 to 18		>18 to 24		>24 to 30				
		n	%	n	%	N	%	n	%	n	%	n	%	
To	F	3	2.48										3	2.48
	M	3	2.48	2	1.65								5	4.13
B	F	5	4.13	5	4.13	3	2.48				1	0.83	14	11.57
	M	2	1.65	13	10.74	6	4.96	2	1.65				23	19.01
C	F	1	0.83	7	5.79	12	9.92	5	4.13	2	1.65		27	22.31
	M	1	0.83	3	2.48	12	9.92	2	1.65	3	2.48		21	17.36
D	F					4	3.31	4	3.31	4	3.31		12	9.92
	M					6	4.96	1	0.83				7	5.79
E	F					1	0.83	4	3.31	3	2.48		8	6.61
	M									1	0.83		1	0.83
Total	F+M	15	12.40	30	24.79	44	36.36	18	14.88	14	11.57		121	100

MPS, midpalatal suture; F, female; M, male.

Table 3. Relationship between maturation of the midpalatal suture and mineralization of the second mandibular molar.

Stages of maturation of MPS	Age		Stages of mineralization of the second mandibular molar												Total	
	Mean	SD	C		D		E		F		G		H			
			n	%	n	%	n	%	n	%	n	%	n	%	n	%
A	7.63	1.60	1	0.83	2	1.65			1	0.83	4	3.31			8	6.61
B	12.51	4.38					6	4.96	7	5.79	13	10.74	11	9.09	37	30.58
C	16.46	5.21					1	0.83	1	0.83	12	9.92	34	28.10	48	39.67
D	20.05	4.68							1	0.83	2	1.65	16	13.22	19	15.70
And	24.11	5.01											9	7.44	9	7.44
Total	16.15	4.18	1	0.83	2	1.65	7	5.79	10	8.26	31	25.62	70	57.85	121	100

MPS, midpalatal suture; SD, standard deviation.

Spearman's correlation coefficient r value = 0.574, p value=<0.001.

Table 4. Relationship between midpalatal suture maturation and mandibular third molar mineralization.

Stages of maturation of MPS	Age		Stages of mineralization of the third molar														Total			
	Mean	SD	A		B		C		D		E		F		G				H	
			n	%	n	%	n	%	n	%	n	%	n	%	n	%	n	%		
A	7.63	1.60	4	3.31			1	0.83	2	1.65	1	0.83							8	6.61
B	12.51	4.38	3	2.48	3	2.48	5	4.13	15	12.40	2	1.65	2	1.65	2	1.65	5	4.13	37	30.58
C	16.46	5.21					4	3.31	16	13.22	3	2.48	8	6.61	6	4.96	11	9.09	48	39.67
D	20.05	4.68							3	2.48			3	2.48	4	3.31	9	7.44	19	15.70
E	24.11	5.01						1	0.83	1	0.83						7	5.79	9	7.44
Total	16.15	4.18	7	5.79	3	2.48	10	8.26	37	30.58	7	5.79	13	10.74	12	9.92	32	26.45	121	100

MPS, midpalatal suture; SD, standard deviation.

Spearman's correlation coefficient r value = 0.548, p value=<0.001.

DISCUSSION

This study confirmed a significant association between midpalatal suture maturation and the mineralization of the mandibular second and third molars. The positive correlation observed supports the hypothesis that both biological processes develop in parallel during adolescence and early adulthood. The most relevant finding was the predominance of Angelieri's stage C in the 14-18-year group, which coincides with the pubertal stage described as critical for skeletal and dental development (15). This age group represents a therapeutic window in which the suture still allows a favorable response to orthopedic expansion, although the presence of stages D or E in some adolescents highlights the variability of sutural closure and the need for individualized evaluation through CBCT.

These results are consistent with Angelieri *et al.* (15) and other studies in Peruvian and international populations (16-19), which reported predominance of stages B and C in adolescents and stages D and E in young adults. The persistence of open sutures beyond 18 years has also been documented, confirming the variability of ossification influenced by genetic and environmental factors. Such variability indicates that patients of the same chronological age may present different maturation stages, underscoring the importance of individualized assessment in clinical practice.

Regarding molar mineralization, the correlation observed is in line with Munusamy *et al.* (20), who demonstrated that dental and skeletal maturation occur synchronously, particularly between 13 and 16 years. The present findings expand this evidence by including mandibular second and third molars as complementary indicators.

With respect to sex, no significant differences were found, in agreement with previous reports in Peruvian samples (16). However,

Šefeldaitė *et al.* (21) described a slight advance in females in other populations, possibly related to hormonal factors. The absence of differences in our sample may reflect group size and distribution or specific population characteristics.

Clinically, the predominance of stage C in 14-18 years supports its consideration as a favorable therapeutic window for conventional maxillary expansion, although the presence of advanced stages requires considering surgically assisted protocols when necessary (17,22). Recent reviews also highlight the value of CBCT in optimizing diagnosis and improving precision in orthodontic planning (23). Moreover, the integration of molar mineralization as a complementary parameter is of clinical relevance, as it helps identify developmental status even when full sutural assessment is not possible, thereby enhancing diagnostic accuracy and treatment planning.

In forensic practice, the association between sutural maturation and molar mineralization represents a valuable contribution to age estimation in adolescents and young adults. Gao *et al.* (19) emphasized the importance of combining dental and skeletal indicators for greater accuracy, which is supported by the present results. This is particularly relevant in legal contexts where determining the threshold between minority and adulthood is required. Recent forensic studies further confirm that combining dental and sutural indicators improves the accuracy of age estimation, reinforcing the potential of molar mineralization and sutural maturation as complementary tools in forensic odontology (24).

The main limitation of this study lies in its cross-sectional design, which prevents longitudinal evaluation of sutural and dental maturation in the same individuals. Additionally, although the sample was representative (n=121), other skeletal variables, such as vertical facial pattern, were not considered. Nevertheless, the methodological

strength lies in the use of CBCT, currently regarded as the most reliable technique for evaluating the midpalatal suture (15). The consistency of the results with previous research reinforces their external validity and clinical and forensic applicability.

Future studies should adopt longitudinal and multicenter designs, including populations from different regions and ethnic backgrounds. Furthermore, predictive models combining sutural maturation, dental mineralization, and other skeletal indicators may increase diagnostic precision and broaden clinical and forensic applications.

CONCLUSIONS

This study confirmed a significant relationship between midpalatal suture maturation and the mineralization of the mandibular second and third molars, demonstrating parallel developmental trajectories.

In the 14-18-year group, Angelieri's stage C was predominant, indicating this period as favorable for conventional maxillary expansion; however, the presence of more advanced stages in some individuals highlights the need for individualized evaluation through CBCT.

The correlation between sutural maturation and dental mineralization supports the combined use of dental and skeletal indicators, optimizing orthodontic diagnosis and the selection of the most appropriate biological timing for intervention.

This association also contributes to forensic practice, providing additional parameters for age estimation in adolescents and young adults, particularly in determining legal adulthood.

CONFLICT OF INTEREST: The authors declare that they have no conflict of interest.

ETHICAL APPROVAL: This study was approved by the Institutional Research Ethics Committee of the Federico Villarreal National University.

FUNDING: Self-funded.

AUTHOR CONTRIBUTION STATEMENT: Conceptualization and design: L.A.G.G. and R.M.L.; Literature review: L.A.G.G. and R.M.L.; Methodology and validation: L.A.G.G.; Formal analysis, R.M.L.; Research and data collection, L.A.G.G.; Resources: L.A.G.G. and R.M.L.; Data analysis and Interpretation: L.A.G.G. and R.M.L.; Writing-preparation of the original draft: L.A.G.G.; Writing-revision and editing: R.M.L.; Supervision, R.M.L.; Project administration: L.A.G.G.; Acquisition of funds: Self-financed.

REFERENCES

1. McNamara J.A. Maxillary transverse deficiency. *Am J Orthod Dentofacial Orthop.* 2000; 117 (5): 567-70.
2. Baccetti T., Franchi L., McNamara J.A. Jr. An improved version of the cervical vertebral maturation (CVM) method for the assessment of mandibular growth. *Angle Orthod.* 2002; 72 (4): 316-23.
3. McNamara J.A. Orthodontic treatment and timing: clinical and biological aspects. *Am J Orthod Dentofacial Orthop.* 2002; 121 (6): 569-70.
4. Baccetti T., Franchi L., McNamara J.A. Jr. The cervical vertebral maturation method for the assessment of optimal treatment timing in dentofacial orthopedics. *Semin Orthod.* 2005; 11 (3): 119-29.

5. Fishman L.S. Radiographic evaluation of skeletal maturation. A clinically oriented method based on hand-wrist films. *Angle Orthod.* 1979; 49 (4): 283-300.
6. Demirjian A., Goldstein H., Tanner J.M. A new system of dental age assessment. *Hum Biol.* 1973; 45 (2): 211-27.
7. Demirjian A., Goldstein H. New systems for dental maturity based on seven and four teeth. *Ann Hum Biol.* 1976; 3 (5): 411-21.
8. Kumar S., Srivastava A., Sharma P. Correlation of midpalatal suture maturation with chronological age and skeletal maturation. *J Clin Orthod Res.* 2024; 58 (2): 78-84.
9. Lecca-Morales J., Guerrero M.E., Flores-Mir C., Padilla M., Rodríguez-Cárdenas Y.A. Association between mandibular third molar mineralization stages and skeletal maturity in a Peruvian population. *J Forensic Leg Med.* 2017; 52: 188-92.
10. Villarroel-Dorrego M., Suazo G.I., Cantín M. Midpalatal suture maturation in adolescents and young adults: A CBCT study in a Chilean population. *Int J Morphol.* 2021; 39 (4): 1121-7.
11. González-Moreno P., Tarazona-Álvarez P., Paredes-Gallardo V., Zamora N., Cibrian R.M. Association between chronological age and midpalatal suture maturation: A systematic review. *J Clin Med.* 2022; 11 (21): 6502.
12. Demirturk K., Acar A., Erverdi N. Evaluation of midpalatal suture maturation using cone-beam computed tomography. *Eur J Orthod.* 2017; 39 (6): 638-44.
13. Perinetti G., Contardo L., Castaldo A., McNamara J.A. Jr., Franchi L. Diagnostic performance of dental maturity for identification of the circumpubertal growth phase. *Eur J Orthod.* 2016; 38 (6): 640-7.
14. Landis J.R., Koch G.G. The measurement of observer agreement for categorical data. *Biometrics.* 1977; 33 (1): 159-74.
15. Angelieri F., Cevidanes L.H., Franchi L., Gonçalves J.R., Benavides E., McNamara J.A. Jr. Midpalatal suture maturation: Classification method for individual assessment before rapid maxillary expansion. *Am J Orthod Dentofacial Orthop.* 2013; 144 (5): 759-69.
16. Chávez-Sevillano M.G., Tenorio J., Blanco-Victorio D., Lagravère M.O., Quintão C.C.A., Palomino-Gómez S.P. Evaluation of the suture ossification level according to age and sex in children, adolescents, and adults: A cross-sectional and observational 3D study. *Int Orthod.* 2021; 19 (1): 67-75.
17. Jiménez-Valdivia L.M., Lara-Díaz V.J., Rodríguez-Cárdenas Y.A., Ruíz-Mora G.A. Midpalatal suture maturation stages in adolescents and young adults: A CBCT cross-sectional study. *Prog Orthod.* 2019; 20 (1): 1-9.
18. Chutasripanich N., Mahatumarat K., Panmekiate S. Relationship between the midpalatal suture maturation, cervical vertebral maturation, and dental age in 8-18 years old patients. *J Orthod Sci.* 2020; 9 (5): 1-7.
19. Gao L., Lin J., Li W., Chen Y. Association between midpalatal suture maturation and chronological age, dental development, and cervical vertebral maturation: A CBCT study. *J Craniofac Surg.* 2021; 32 (5): e437-41.
20. Munusamy A., Raj A.S., Prasad K., Thomas A.M. Correlation between midpalatal suture maturation, cervical vertebral maturation,

- and dental calcification. *J Clin Diagn Res.* 2023; 17 (4): ZC01-ZC06.
21. Šefeldaitė R., Lopatienė K., Smailienė D. Assessment of midpalatal suture maturation stages in relation to age and sex using CBCT. *Stomatology.* 2023; 25 (2): 45-52.
 22. Booth T., Ali R., Perry J., Bister D., Johal A. Midpalatal suture maturation and its relevance to maxillary expansion: A narrative review. *Orthod Craniofac Res.* 2024; 27 (1): 1-12.
 23. Ferrillo M., Marotta N., Calafiore D., Ammendolia A., Fortunato L., de Sire A. Midpalatal suture maturation and rapid maxillary expansion: A narrative review on diagnostic and clinical implications. *Appl Sci.* 2024; 14 (2): 642.
 24. Shayani F., Javadinejad S., Ghaffari S., Ghaffari R., Ghaffari M. Age estimation through dental and skeletal indicators: A CBCT-based forensic study. *J Forensic Odontostomatol.* 2023; 41 (1): 20-8.