



LITERATURE REVIEW:

Use of Thyroid Shield in Cone-Beam Computed Tomography: A Literature Review

Usos de protector tiroideo en tomografía computarizada de haz cónico: revisión narrativa

Andrea Carrasco M. DDS, MSc¹ <https://orcid.org/0009-0005-0434-8404>

Lucía Barba R. DDS, MSc² <https://orcid.org/0000-0003-1457-7209>

Alejandro Hidalgo R. DDS, PhD³ <https://orcid.org/0000-0001-9341-9529>

¹MSc Oral and Maxillofacial Health Sciences. Specialist in Oral and Maxillofacial Radiology. Professor in the Department of Stomatology and in the Oral and Maxillofacial Radiology. Specialization Program, Faculty of Dentistry, University of Talca, Talca, Chile.

²MSc Oral and Maxillofacial Radiology, Specialist in Oral and Maxillofacial Radiology. Professor in the Department of Diagnostic and Surgical Sciences, Faculty of Dentistry, University of Costa Rica, San José, Costa Rica.

³PhD in Oral Radiology, Specialist in Oral and Maxillofacial Radiology. Professor in the Department of Stomatology and Director of the Oral and Maxillofacial Radiology Specialization Program, Faculty of Dentistry, University of Talca, Talca, Chile.

Correspondence to: Andrea Carrasco Meza - acarrasco@utalca.cl

Received: 14-III-2025

Accepted: 8-IV-2025

ABSTRACT: The aim of this literature review was to analyze the evidence and international recommendations on the use of thyroid shield (TS) in cone-beam computed tomography (CBCT) examinations. The search was conducted in three electronic databases (PubMed, Scopus, and Web of Science) in English from 2010 to date. This search included articles that provided recommendations or benefits of TS use in CBCT, as well as those that discouraged its use. A complementary search was conducted by reviewing guidelines, recommendations, or articles from international organizations and globally recognized journals, published on their official websites. Of the 23 articles reviewed, 19 indicate that using TS in CBCT reduces radiation doses in patients or recommend its use in these examinations, as it provides a benefit to the patient. However, some note specific cases where its use is not advised. On the other hand, two articles, from the British Institute of Radiology and the UK Health Security Agency, do not recommend the use of TS in CBCT examinations, except in specific cases. Finally, two articles, both from the American Dental Association, oppose TS use in all maxillofacial radiographic examinations, including CBCT. Although there is no consensus among the reviewed articles regarding recommendations or benefits of TS use in CBCT examinations, most articles indicate that it reduces ionizing radiation doses or recommend its use. However, in some cases, TS use may interfere with image quality, making deciding whether to use TS in CBCT examinations challenging for the operator.

KEYWORDS: Radiation protection; Cone-beam computed tomography; Guideline; Radiation, Ionizing; Thyroid gland; Radiography, Dental; Radiation dosage.

RESUMEN: El objetivo de la presente revisión narrativa fue analizar la evidencia y recomendaciones internacionales sobre el uso de protector tiroideo (PT) en exámenes con tomografía computarizada de haz cónico (TCHC). La búsqueda se realizó en tres bases de datos electrónicas (PubMed, Scopus y Web of Science) en idioma inglés desde el año 2010 en adelante. Esta búsqueda incluyó artículos que contuvieran recomendaciones o beneficios del uso de PT en TCHC, así como aquellos que desaconsejaran su uso. La búsqueda complementaria se basó en la revisión de guías, recomendaciones o artículos de organismos internacionales y de revistas de referencia mundial, publicados en su página oficial de internet. De los 23 artículos revisados, 19 indican que el uso del PT en TCHC reduce las dosis de radiación ionizante en los pacientes o recomiendan su uso en estos exámenes, ya que proporciona un beneficio al paciente. Sin embargo, algunos artículos señalan casos específicos en los que no se aconseja su uso. Por otro lado, dos artículos, del Instituto Británico de Radiología y la Agencia de Seguridad Sanitaria del Reino Unido no recomiendan el uso del PT en exámenes con TCHC, excepto en casos específicos. Finalmente, dos artículos, ambos de la Asociación Dental Americana, se oponen al uso de PT en todos los exámenes radiográficos maxilofaciales, incluyendo TCHC. No existe consenso entre los artículos revisados con respecto a las recomendaciones o beneficios del uso de PT en exámenes con TCHC. Sin embargo, la mayoría de los artículos reportan una reducción en las dosis de radiación o bien recomiendan su uso. En algunos casos, el uso de PT puede disminuir la calidad de la imagen, lo que representa un desafío para el operador al momento de decidir su aplicación en estos exámenes.

PALABRAS CLAVE: Protección radiológica; Tomografía computarizada de haz cónico; Guía; Radiación ionizante; Glándula tiroides; Radiografía dental; Dosis de radiación.

INTRODUCTION

Cone-beam computed tomography (CBCT) is a widely used radiological technology in dentistry that provides three-dimensional information of the maxillofacial region (1-3). Despite this benefit, there are concerns regarding the ionizing radiation doses associated with its use (4). This radiation, in addition to reaching the anatomical structures of interest, also affects nearby organs, some of which are radiosensitive (5). The thyroid gland is one of the most radiosensitive organs in the head and neck, and it is exposed to ionizing radiation during CBCT examination (6-8).

Children and young patients, especially girls, are groups of particular concern (4, 9-11). In children and young patients, the thyroid is smaller and positioned higher than in adults, resulting in higher radiation doses (4, 9, 10). Additiona-

lly, these patients have a longer life expectancy compared to adults (12), increasing the risk of long-term adverse radiation effects. Women have a 5.5 times higher risk of radiation-induced thyroid cancer than men from birth to age 10; however, this disparity decreases after this age (7, 11).

To establish guidelines and standards for ensuring the safety of individuals exposed to ionizing radiation, the International Commission on Radiological Protection has established three fundamental principles in radiological protection (10). One of these is the principle of optimization, also known as ALARA (As Low As Reasonably Achievable). This principle emphasizes the need to obtain images with radiation doses as low as reasonably possible, or as low as diagnostically acceptable (ALADA) (13). Due to variations among patients and exam indications, the acronym ALADAIP (As Low As Diagnostically Acceptable

being Indication-oriented and Patient-specific) has also been proposed (14).

There are different strategies to reduce radiation doses, including the use of protective devices for the patient, such as a thyroid shield (TS) (7). When using a TS, it should not compromise the diagnostic quality of the image in the region of interest (7, 15).

There is global controversy regarding the use of TS during dental radiographic examinations (7, 9, 16-18). On one hand, some authors emphasize the benefits of using TS in CBCT examinations to reduce patient radiation doses (7, 9, 19); however, it is not recommended if the region of interest lies within the area covered by the TS or is close to its upper axial level, as it can interfere with image quality (7). On the other hand, recent American guidelines advise against the use of TS in dentistry (16, 17).

The aim of this review was to analyze the evidence and international recommendations regarding the use of TS in CBCT examinations.

METHODS

SEARCH STRATEGY

A systematic primary search was conducted in PubMed, Scopus and Web of Science on 20 October 2024, including articles in English from 2010 to date. The MeSH terms "Radiation Protection", "Cone-Beam Computed Tomography" and "Thyroid Gland" and the free terms "Shielding", "Cone-Beam CT" and "Thyroid" were used, related to the Boolean operators AND and OR in PubMed as follows: ("Thyroid" OR "Thyroid Gland"[Mesh]) AND ("Radiation Protection"[Mesh] OR "Shielding") AND ("Cone-Beam Computed Tomography"[Mesh] OR "Cone-Beam CT"). The search was adapted for the other databases. Weekly alerts were programmed in the three databases to keep the search

updated and new articles were included using the same article selection strategy as the main search.

INCLUSION AND EXCLUSION CRITERIA

This search included articles that contained recommendations or benefits of using TS in CBCT, as well as those that advised against its use. Article selection was performed in two stages: title and abstract, and full text. Narrative reviews were excluded; systematic reviews were included, and the articles cited in these reviews were also analyzed to assess the inclusion of these articles in the present review, incorporating them in the complementary search. The complementary search was based on the review of guidelines, recommendations or articles from international organizations and world-renowned journals, published on their official website (Table 1).

DATA EXTRACTION

The main reviewer (AC), a specialist in Oral and Maxillofacial Imaging with more than five years of experience, recorded the identified articles in an Excel spreadsheet (Microsoft Corporation, Redmond, WA, USA), indicating first author, year of publication, title of the article, name of journal and whether there are recommendations or benefits of using TS in CBCT, or whether its use is discouraged. Duplicated articles were manually eliminated. The main reviewer evaluated the articles at the title and abstract stages. In case of doubts about including an article at this stage, it was included for evaluation in the next stage. The full-text articles included were independently evaluated by the main reviewer and a second reviewer (LB), a specialist in Oral and Maxillofacial Imaging with more than five years of experience. In case of disagreement with a full-text article, a third reviewer (AH), a specialist and PhD in Oral and Maxillofacial Radiology, with more than 10 years of experience, was consulted. The article selection process was represented by a diagram (Figure 1).

RESULTS

A total of 64 articles were identified across the three databases, of which 13 were ultimately included in this review. Additionally, 10 articles were selected by complementary search, which included three international guidelines on radiation protection (6, 20, 21) and seven expert recommendations (17, 22-27). This process resulted in a total of 23 articles included in the present review (Table 2).

Of the 23 articles reviewed, 19 indicate that the use of TS in CBCT reduces radiation doses in

patients or recommend its use in these examinations, as it provides a benefit to the patient (6, 7, 9, 19, 20, 22-26, 28-36). However, some of these articles highlight that there are specific cases where its use is not advised. On the other hand, two articles, from the British Institute of Radiology (21) and the UK Health Security Agency (27), do not recommend the use of TS in CBCT examinations, except in specific cases. Finally, two articles, both from the American Dental Association (ADA) (16, 17), oppose the use of TS in all maxillofacial radiographic examinations, including CBCT, and in any circumstances.

Table 1. International organizations and scientific journals included in the complementary search with their links.

International organization/journal	Official website
European Commission	https://commission.europa.eu/index_en
National Council on Radiation Protection and Measurements	https://ncrponline.org/
International Atomic Energy Agency	https://www.iaea.org/
American Thyroid Association	https://www.thyroid.org/
UK Health Security Agency	https://www.gov.uk/
European Society of Radiology	https://www.eurosafeimaging.org/
Image Gently	https://www.imagegently.org/
British Institute of Radiology	https://www.bir.org.uk/
American Dental Association	https://www.ada.org/
Thyroid	https://www.liebertpub.com/loi/thy/

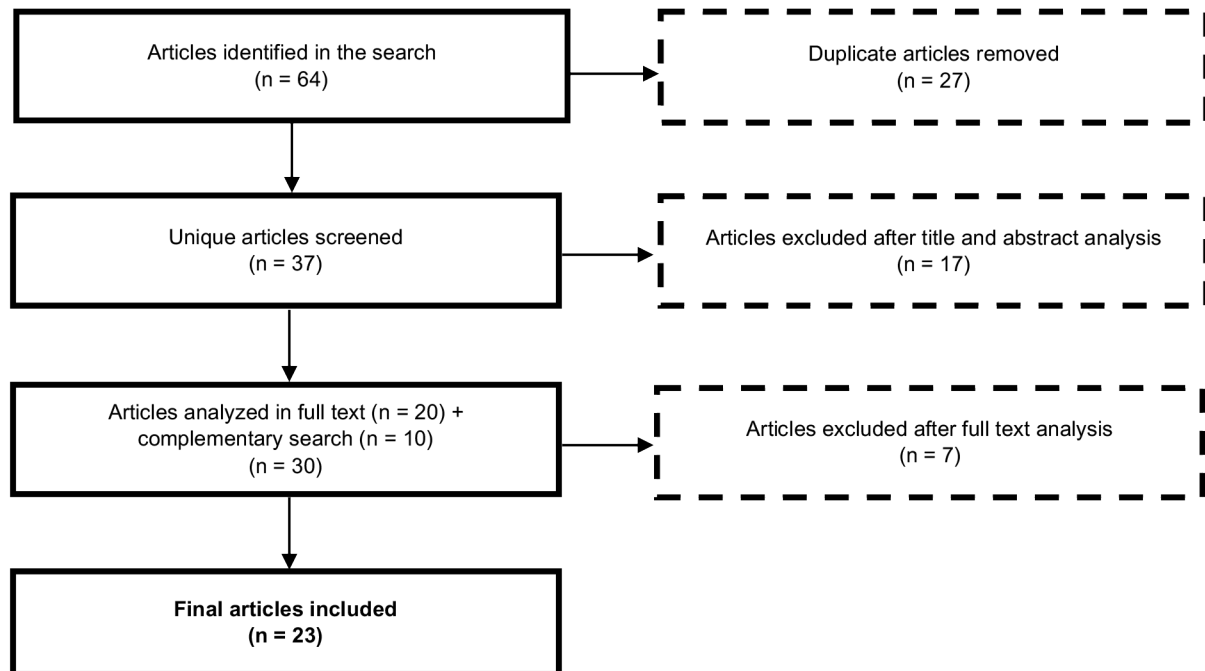


Figure 1. Flow diagram of the article selection process.

Table 2. Summary of articles analyzed regarding recommendations or benefits of using thyroid shield in cone-beam computed tomography examinations.

Author	Title	Year	Benefit/ Recommendation
Chen G, <i>et al.</i>	Monte Carlo simulation study of the effect of thyroid shielding on radiation dose in dental cone beam CT in an adult male phantom	2024	Yes
American Dental Association	Optimizing radiation safety in dentistry. Clinical recommendations and regulatory considerations	2024	No
American Dental Association / American Academy of Oral and Maxillofacial Radiology	Patient shielding during dentomaxillofacial radiography: Recommendations from the American Academy of Oral and Maxillofacial Radiology	2023	No
Saribal GS, <i>et al.</i>	Evaluation of the radiation protection effectiveness of a lead-free homopolymer in cone beam computed tomography	2023	Yes
Grünig M, <i>et al.</i>	Impact of thyroid gland shielding on radiation doses in dental cone beam computed tomography with small and medium fields of view	2022	Yes
Vogiatzi T, <i>et al.</i>	Effect of field of view (FOV) positioning and shielding on radiation dose in paediatric CBCT	2022	Yes ^a
International Atomic Energy Agency	Radiation Protection in Dental Radiology - Safety Reports Series No. 108	2022	Yes
Schneider AB, <i>et al.</i>	Thyroid collars in dental radiology: 2021 update	2021	Yes
Hiles P, <i>et al.</i>	European consensus on patient contact shielding	2021	Yes ^b
Attala D, <i>et al.</i>	Dose reduction in head and neck organs through shielding and application of different scanning parameters in cone beam computed tomography: an effective dose study using an adult male anthropomorphic phantom	2020	Yes
Van Acker JWG, <i>et al.</i>	Outcomes of different radioprotective precautions in children undergoing dental radiography: a systematic review	2020	Yes ^{a,c}
British Institute of Radiology	Guidance on using shielding on patients for diagnostic radiology applications	2020	No ^d
Pauwels R, <i>et al.</i>	Thyroid shielding in cone beam computed tomography: recommendations towards appropriate use	2019	Yes ^c
National Council on Radiation Protection and Measurements	Report No. 177 – Radiation protection in dentistry and oral & maxillofacial imaging: recommendations of the National Council on Radiation Protection and Measurements	2019	Yes ^c
Tsapaki, V. <i>et al.</i>	Radiation protection in dental radiology – recent advances and future directions	2017	Yes ^c
Hidalgo A, <i>et al.</i>	Effectiveness of thyroid gland shielding in dental CBCT using a paediatric anthropomorphic phantom	2015	Yes ^a
White SC, <i>et al.</i>	The Image Gently in dentistry campaign: promotion of responsible use of maxillofacial radiology in dentistry for children	2014	Yes ^a
Goren AD, <i>et al.</i>	Effect of leaded glasses and thyroid shielding on cone beam CT radiation dose in an adult female phantom	2013	Yes
American Thyroid Association	Policy statement on thyroid shielding during diagnostic medical and dental radiology	2013	Yes
Qu X, <i>et al.</i>	Thyroid shields for radiation dose reduction during cone beam computed tomography scanning for different oral and maxillofacial regions	2012	Yes
Qu XM, <i>et al.</i>	Dose reduction of cone beam CT scanning for the entire oral and maxillofacial regions with thyroid collars	2012	Yes
European Commission	Cone beam CT for dental and maxillofacial radiology: evidence-based guidelines - Radiation protection N° 172	2012	Yes
UK Health Security Agency	Guidance on the Safe Use of Dental Cone Beam CT (Computed Tomography) Equipment	2010	No ^f

^aRecommendations for pediatric patients.

^bThe use of a thyroid shield is not recommended when it overlaps with the primary beam or falls within the field of view.

^cThe thyroid shield should not be used when assessing structures covered by it or slightly above its upper axial level, or when a tube current modulation system is used during the scout. For automatic exposure control based on scout images, the thyroid shield should be placed only after the scout image has been acquired.

^dAvoid using the thyroid shield unless a large field of view is being used.

^eThe thyroid shield is recommended when it does not interfere with the examination.

^fRoutine use of the thyroid shield is not advised; rather, the need should be evaluated on a case-by-case basis.

DISCUSSION

This review analyzed the international evidence and recommendations on the use of TS in CBCT examinations, evaluating the different criteria that exist worldwide, to guide better practices in dentistry. Most of the articles reviewed describe a decrease in radiation doses associated with the use of TS in CBCT or recommend its use for the same reason. This group includes, in addition to renowned researchers, world-leading international organizations, such as the European Commission, the National Council on Radiation Protection and Measurements of the United States, the International Atomic Energy Agency, the American Thyroid Association, among others.

The ADA communicated its position in favor of the use of TS in dental radiographic examinations in a guideline published in 2012 (37), covering regulatory and radiographic safety aspects. This guideline stated that all precautions should be taken to minimize radiation exposure, and therefore recommended the use of TS whenever possible. In 2023, the ADA published a new guideline based on the recommendations of the American Academy of Oral and Maxillofacial Radiology (16). In this new guideline, the ADA advises against the use of TS in dental radiology, including CBCT examinations, as it could generate artifacts that negatively affect the diagnosis quality in extraoral images. Additionally, they highlight that exposure to ionizing radiation in the general population from intraoral radiographic examinations has an insignificant impact on thyroid carcinogenesis. In this regard, the ADA also indicates that thyroid radiation doses in examinations with CBCT are within the range of those obtained with intraoral radiographs, suggesting comparability in terms of thyroid radiation doses between both modalities. Another argument of the ADA to advise against the use of TS is also that there are more effective strategies

than the use of TS for reducing radiation doses in the patient, such as a correct indication of the radiographic examination, adequate collimation, and the use of digital equipment.

In 2024, the ADA published another article with clinical recommendations and regulatory considerations in the context of optimizing radiation safety in dentistry (17), based on the analysis of 95 documents. In this latest publication, the ADA again advises against TS in dental radiology, including CBCT examinations. However, the only citation supporting their recommendation is the article previously published by them (16), with the same justifications. Therefore, the ADA is the first and only organization worldwide that promotes the disuse of TS in dentistry.

Considering the ADA's rationale for formulating its recommendations, it is recognized that both radiation doses in dental radiology and the risk of radiation-induced cell damage are low (10). However, epidemiological studies have provided evidence of an increased risk of damage to the brain, salivary glands, and the appearance of thyroid tumors (6, 38) because of exposure to ionizing radiation in dental radiographic examinations. It should be noted that radiation doses in dental radiology are associated with stochastic effects, i.e. those that occur without a threshold dose level, whose probability of occurrence is proportional to the dose and its severity is independent of the dose (39). For this reason, strategies to reduce doses must be maximized, since the higher the radiation dose, the greater the probability of suffering cell damage. As noted by the ADA, it is accepted that there are more effective strategies than the use of TS to reduce radiation dose to the patient. However, based on the second principle of radiation protection, optimization or ALARA (10), radiographic images should be obtained with radiation doses as low as reasonably achievable.

ble. This second principle promotes the use of all strategies that minimize radiation doses, and not only those considered most effective.

In the present review, two other articles were found advising against the routine use of TS in CBCT examinations (21, 27), however, both were not as categorical in their recommendation as the ADA. In one of them, from the British Institute of Radiology (21), the use of TS is not recommended, except for large field of view, where there may be some benefit. The other article, from the UK Health Security Agency (27), although it does not recommend the routine use of TS, suggests evaluating the need for TS on a case-by-case basis.

The European Consensus (24) advises against the use of TS in all dental radiographs, when the TS is within the primary beam, stating that it can be used in those cases where the TS is outside the primary beam, except in cephalometric radiographs. Despite this recommendation, the European Consensus does not recommend the use of TS for examinations such as mammography, multidetector CT examinations, among others. However, the radiation dose that the thyroid could receive with these examinations would be similar to or higher than with CBCT (16). This situation could be due to the closer proximity of the thyroid to the primary beam during maxillofacial radiographic examination. Therefore, applying the inverse square law (5) and given the beam divergence, TS would fulfill its function in examinations with CBCT, but not in other radiographic examinations such as chest or breast, where the primary beam is not oriented towards the thyroid, and at the same time would be further away from it. For the use of TS to be effective, correct positioning of it in the patient is essential, since it has been shown that a poorly positioned TS decreases protection (31), and at the same time could alter the quality image, leading to the repetition of the examination (6).

It is widely accepted that, in some cases, the use of TS during CBCT examinations can alter image quality by generating artifacts (7). Regarding the interference of TS in the image, in the present review, several authors agree that TS should not be used when the region of interest corresponds to that covered by TS or that immediately adjacent to its upper axial level, since it could make diagnosis difficult (6, 7, 20, 33, 34). In this regard, some of the experimental investigations to determine radiation doses associated with the use of TS did not analyze the image quality obtained (19, 29-32, 35, 36), this being a primary factor in the decision-making regarding its use.

Some articles analyzed in the present review recommend the use of TS "where feasible" (28), "when it does not interfere with the examination" (22), or suggest "reducing thyroid radiation exposure as much as possible" (25), however, they do not specify which these situations are, so the recommendation could be ambiguous.

Regarding those articles that highlight the benefits of using TS in children in CBCT examinations (7, 9, 26, 32-34), the recommendations are addressed from different points of view, depending on the methodology used in each investigation. However, all these articles agree on the benefits of using TS in pediatric patients concerning the associated dose reduction. Even two of them (7, 33) recommend the use of TS in children routinely, except in those cases where the region of interest corresponds to that covered by the TS or that closest to its upper axial level.

The use of TS in CBCT may interfere with estimating the x-ray tube current settings in equipment equipped with an Automatic Exposure Control (AEC) system. In such systems, the x-ray tube current is automatically adjusted based on the scout views acquired during patient positio-

ning. In this regard, the articles that mention this function (7, 9, 33) recommend placing the TS after acquiring the preliminary images to prevent interference with the x-ray tube current estimation, thereby avoiding an unnecessary increase in radiation dose. There is a second type of AEC system during scanning, corresponding to Tube Current Modulation (TCM). This is a real-time feedback system, which regulates the x-ray tube current based on the attenuation or reduction of the primary beam intensity (7). If part of the TS is within the primary beam, a counterproductive effect occurs, since the CBCT equipment overestimates the density of the patient, increasing the intensity of the beam, and generating greater radiation. In this case, the recommendation is to avoid the use of TS unless it is outside the primary beam with absolute certainty (7, 33).

In addition to the use of TS, some articles from the present review highlight other strategies to reduce radiation dose to the thyroid. If an adult patient is carefully positioned during CBCT examinations, the thyroid should be exposed only to secondary radiation (9). Also, one method to distance this gland from the primary beam is to position the patient with the chin elevated and the lower edge of the mandible parallel to the floor (12, 19). On the other hand, some of the recommendations analyzed also guide the selection of a field of view as small as possible, covering the region of interest with the lowest possible dose without compromising the diagnostic image quality (19, 29, 30, 34), to avoid irradiating unnecessary regions. Also, some articles claim that the effectiveness of TS increases with the use of larger field of view sizes or when the primary beam is closer to the thyroid (20, 32, 36).

It is essential to correctly identify those cases where TS should or should not be used, to avoid repeat examinations due to artifacts generated using TS. The TS models available are varied

and not standardized (40); in addition, a wide range of CBCT equipment can be found on the market (4), each with varied fields of view and exposure parameters, which poses the challenge of identifying when the use of TS will interfere with the examination, so adequate operator training and education is essential (17).

In conclusion, although the reviewed articles do not agree on the recommendations or benefits of using TS in CBCT examinations, most studies indicate that TS usage reduces ionizing radiation doses. However, its use is not recommended when the region of interest is covered by the TS or is immediately adjacent to its upper axial level, as this can compromise image quality by generating artifacts, thereby hindering diagnosis. Given the varied and sometimes conflicting recommendations regarding the use of TS in CBCT examinations, further research is needed to achieve greater clarity and to unify criteria regarding TS use in CBCT examinations. Additionally, it is crucial to provide more explicit recommendations to address potential ambiguities, particularly in guidelines from international organizations. Clear guidance could help more professionals adopt better practices in radiation protection in dentistry.

AUTHOR CONTRIBUTIONS STATEMENT

Conceptualization and design: A.C.M. and A.H.R.
Literature review: A.C.M. and L.B.R.
Formal analysis: A.C.M., L.B.R. and A.H.R.
Writing-original draft preparation: A.C.M., L.B.R. and A.H.R.
Writing-review & editing: A.C.M., L.B.R. and A.H.R.
Supervision: A.H.R.

ACKNOWLEDGMENTS

The first author thanks InES-Género at the University of Talca for their support, contributing significantly to the advancement of this research.

REFERENCES

1. Arai Y., Tammisalo E., Iwai K., Hashimoto K., Shinoda K. Development of a compact computed tomographic apparatus for dental use. *Dentomaxillofac Radiol.* 1999; 28 (4): 245-8.
2. Mozzo P., Procacci C., Tacconi A., Martini P.T., Andreis I.A. A new volumetric CT machine for dental imaging based on the cone-beam technique: preliminary results. *Eur Radiol.* 1998; 8 (9): 1558-64.
3. Scarfe W.C., Farman A.G. What is cone-beam CT and how does it work? *Dent Clin North Am.* 2008; 52 (4): 707-30, v.
4. Ludlow J.B., Timothy R., Walker C., Hunter R., Benavides E., Samuelson D.B., et al. Effective dose of dental CBCT-a meta analysis of published data and additional data for nine CBCT units. *Dentomaxillofac Radiol.* 2015; 44 (1): 20140197.
5. European Commission. European guidelines on radiation protection in dental radiology: the safe use of radiographs in dental practice. Publications Office. 2004 [Accessed 06 March 2025]. Available from: <https://op.europa.eu/en/publication-detail/-/publication/ea20b522-883e-11e5-b8b7-01aa75ed71a1>
6. European Commission. Evidence-based guidelines on cone beam CT for dental and maxillofacial radiology. Office for Official Publications of the European Communities. Radiation Protection 172. 2012 [Accessed 06 March 2025]. Available from: http://ec.europa.eu/energy/nuclear/radiation_protection/doc/publication/172.pdf
7. Pauwels R., Horner K., Vassileva J., Rehani M.M. Thyroid shielding in cone beam computed tomography: recommendations towards appropriate use. *Dentomaxillofac Radiol.* 2019; 48 (7): 20190014.
8. Terashima S., Sano J., Osanai M., Toshima K., Ohuchi K., Hosokawa Y. Monte Carlo simulations of organ and effective doses and dose-length product for dental cone-beam CT. *Oral Radiol.* 2024; 40 (1): 37-48.
9. Hidalgo A., Davies J., Horner K., Theodorakou C. Effectiveness of thyroid gland shielding in dental CBCT using a paediatric anthropomorphic phantom. *Dentomaxillofac Radiol.* 2015; 44 (3): 20140285.
10. International Commission on Radiological Protection. The 2007 recommendations of the International Commission on Radiological Protection. ICRP publication 103 2007 [Accessed 06 March 2025]. Available from: [https://www.icrp.org/docs/icrp_publication_103-annals_of_the_icrp_37\(2-4\)-free_extract.pdf](https://www.icrp.org/docs/icrp_publication_103-annals_of_the_icrp_37(2-4)-free_extract.pdf)
11. National Research Council of the National Academies. Health risks from exposure to low levels of ionizing radiation: BEIR VII Phase 2 Washington, DC: The National Academies Press; 2006 [Accessed 06 March 2025]. Available from: <https://nap.nationalacademies.org/catalog/11340/health-risks-from-exposure-to-low-levels-of-ionizing-radiation>
12. Ludlow J.B., Walker C. Assessment of phantom dosimetry and image quality of i-CAT FLX cone-beam computed tomography. *Am J Orthod Dentofacial Orthop.* 2013; 144 (6): 802-17.
13. Jaju P.P., Jaju S.P. Cone-beam computed tomography: Time to move from ALARA to ALADA. *Imaging Sci Dent.* 2015; 45 (4): 263-5.
14. Oenning A.C., Jacobs R., Pauwels R., Stratis A., Hedesiu M., Salmon B., et al. Cone-beam CT in paediatric dentistry: DIMITRA project position statement. *Pediatr Radiol.* 2018; 48 (3): 308-16.
15. Hidalgo-Rivas J.A., Theodorakou C., Carmichael F., Murray B., Payne M., Horner K. Use of cone beam CT in children and young people in three United Kingdom dental hospitals. *Int J Paediatr Dent.* 2014; 24 (5): 336-48.
16. Benavides E., Bhula A., Gohel A., Lurie A.G., Mallya S.M., Ramesh A., et al. Patient shielding during dentomaxillofacial radio-

- graphy: Recommendations from the American Academy of Oral and Maxillofacial Radiology. *J Am Dent Assoc.* 2023; 154 (9): 826-35.e2.
17. Benavides E., Krecioch J.R., Connolly R.T., Allareddy T., Buchanan A., Spelic D., et al. Optimizing radiation safety in dentistry: Clinical recommendations and regulatory considerations. *J Am Dent Assoc.* 2024; 155 (4): 280-93.e4.
 18. Cascante-Sequeira D., Barba Ramírez L., Ruiz-Imbert A. The use of thyroid shielding and lead apron in dentistry. Position Statement from the Costa Rican Academy of Oral and Maxillofacial Radiology. *Odovtos-Int J Dent Sc.* 2024; 26 (3): 10-9.
 19. Qu X., Li G., Zhang Z., Ma X. Thyroid shields for radiation dose reduction during cone beam computed tomography scanning for different oral and maxillofacial regions. *Eur J Radiol.* 2012; 81 (3): e376-80.
 20. International Atomic Energy Agency. Radiation protection in dental radiology, safety reports series No. 108. Vienna. 2022 [Accessed 06 March 2025]. Available from: <https://www.iaea.org/publications/14720/radiation-protection-in-dental-radiology>
 21. British Institute of Radiology. Guidance on using shielding on patients for diagnostic radiology applications. 2020 [Accessed 05 October 2024]. Available from: www.bir.org.uk
 22. National Council on Radiation Protection and Measurements. Radiation protection in dentistry and oral & maxillofacial imaging: recommendations of the National Council on Radiation Protection and Measurements. NCRP Report No. 177: National Council on Radiation Protection and Measurements; 2019 [Accessed 06 March 2025]. Available from: <https://ncrponline.org/shop/reports/report-no-177/>
 23. Schneider A.B., Kaplan M.M., Mihailescu D.V. Thyroid Collars in Dental Radiology: 2021 Update. *Thyroid.* 2021; 31 (9): 1291-6.
 24. Hiles P., Gilligan P., Damilakis J., Briers E., Candela-Juan C., Faj D., et al. European consensus on patient contact shielding. *Insights Imaging.* 2021; 12 (1): 194.
 25. American Thyroid Association. Policy statement on thyroid shielding during diagnostic medical and dental radiology 2013 [Accessed 06 March 2025]. Available from: https://www.thyroid.org/wp-content/uploads/state-ments/ABS1223_policy_statement.pdf
 26. White S.C., Scarfe W.C., Schulze R.K., Lurie A.G., Douglass J.M., Farman A.G., et al. The Image Gently in Dentistry campaign: promotion of responsible use of maxillofacial radiology in dentistry for children. *Oral Surg Oral Med Oral Pathol Oral Radiol.* 2014; 118 (3): 257-61.
 27. United Kingdom Health Security Agency. Guidance on the safe use of dental cone beam CT (computed tomography) equipment. HPA-CRCE-010 2010 [Accessed 06 March 2025]. Available from: https://assets.publishing.service.gov.uk/government/uploads/system/uploads/attachment_data/file/340159/HPA-CRCE-010_for_website.pdf
 28. Grüning M., Koivisto J., Mah J., Bumann A. Impact of thyroid gland shielding on radiation doses in dental cone beam computed tomography with small and medium fields of view. *Oral Surg Oral Med Oral Pathol Oral Radiol.* 2022; 134 (2): 245-53.
 29. Attaia D., Ting S., Johnson B., Masoud M.I., Friedland B., Abu El Fotouh M., et al. Dose reduction in head and neck organs through shielding and application of different scanning parameters in cone beam computed tomography: an effective dose study using an adult male anthropomorphic phantom. *Oral Surg Oral Med Oral Pathol Oral Radiol.* 2020; 130 (1): 101-9.
 30. Goren A.D., Prins R.D., Dauer L.T., Quinn B., Al-Najjar A., Faber R.D., et al. Effect of leaded glasses and thyroid shielding on cone

- beam CT radiation dose in an adult female phantom. *Dentomaxillofac Radiol.* 2013; 42 (6): 20120260.
31. Qu X.M., Li G., Sanderink G.C., Zhang Z.Y., Ma X.C. Dose reduction of cone beam CT scanning for the entire oral and maxillofacial regions with thyroid collars. *Dentomaxillofac Radiol.* 2012; 41 (5): 373-8.
32. Vogiatzi T., Menz R., Verna C., Bornstein M.M., Dagassan-Berndt D. Effect of field of view (FOV) positioning and shielding on radiation dose in paediatric CBCT. *Dentomaxillofac Radiol.* 2022; 51 (6): 20210316.
33. Van Acker J.W.G., Pauwels N.S., Cauwels R.G.E.C., Rajasekharan S. Outcomes of different radioprotective precautions in children undergoing dental radiography: a systematic review. *Eur Arch Paediatr Dent.* 2020; 21 (4): 463-508.
34. Tsapaki V. Radiation protection in dental radiology - Recent advances and future directions. *Phys Med.* 2017; 44: 222-6.
35. Saribal G., Canger E.M., Yaray K. Evaluation of the radiation protection effectiveness of a lead-free homopolymer in cone beam computed tomography. *Oral Surg Oral Med Oral Pathol Oral Radiol.* 2023; 136 (1): 91-101.
36. Chen G., Yin Y., Sun L., Tang Z., Chen J. Monte Carlo simulation study of the effect of thyroid shielding on radiation dose in dental cone beam CT in an adult male phantom. *Radiat Prot Dosimetry.* 2024.
37. American Dental Association, US Department of Health and Human Services. Dental radiographic examinations: recommendations for patient selection and limiting radiation exposure. 2012 [Accessed 06 March 2025]. Available from: <https://www.ada.org/resources/ada-library/oral-health-topics/x-rays-radiographs>
38. Memon A., Rogers I., Paudyal P., Sundin J. Dental x-rays and the risk of thyroid cancer and meningioma: a systematic review and meta-analysis of current epidemiological evidence. *Thyroid.* 2019; 29 (11): 1572-93.
39. International Atomic Energy Agency. Dosimetry in diagnostic radiology: an international code of practice. Vienna. 2007 [Accessed 06 March 2025]. Available from: <https://www.iaea.org/publications/7638/dosimetry-in-diagnostic-radiology-an-international-code-of-practice>
40. Fakhoury E., Provencher J.A., Subramaniam R., Finlay D. J. Not all lightweight lead aprons and thyroid shields are alike. *J Vasc Surg.* 2019; 70 (1): 246-50.