



## CASE REPORT:

### Digital Transfer of the Emergence Profile After Immediate Implant Placement with Hard and Soft Tissue Management

Transferencia digital del perfil de emergencia tras la instalación inmediata de implantes con manejo de tejidos duros y blandos

Emil Correa Quispilaya DDS, MSc<sup>1</sup> <https://orcid.org/0009-0008-4549-0425>

Consuelo Marroquín-Soto DDS, MSc<sup>2</sup> <https://orcid.org/0000-0002-1433-6205>

César-Augusto Padilla-Avalos DDS, MSc, PhD<sup>3</sup> <https://orcid.org/0000-0002-8436-4113>

<sup>1</sup>Coordinator, Division of Periodontics and Implants, School of Dentistry, Universidad Científica del Sur. Lima, Perú.

<sup>2</sup>Associate Researcher, School of Dentistry, Universidad Científica del Sur. Lima, Perú.

<sup>3</sup>Research Professor, Research and Innovation Laboratory in Digital Dentistry, School of Dentistry, Universidad Científica del Sur. Lima, Perú.

Correspondence to: César-Augusto Padilla-Avalos, DDS, MSc, PhD - [cpadillaav@cientifica.edu.pe](mailto:cpadillaav@cientifica.edu.pe)

Received: 25-VII-2025

Accepted: 5-IX-2025

**ABSTRACT:** The purpose of this report is to describe a streamlined digital workflow to transfer conditioned emergence profiles after immediate implant placements with hard and soft tissue management. A 50-year-old woman with fractures in two maxillary premolars was treated by atraumatic extractions, immediate implant placements, guided bone regeneration with a particulate xenograft, and connective tissue grafting. Healing abutments were placed to support initial tissue maturation. After a 12-16-week healing period, the implants were activated, and screw-retained provisional restorations were delivered to condition the peri-implant mucosa. Once stable emergence profiles were achieved, at week 24, a digital protocol using three coordinated scans was implemented: (1) intraoral scan with the scan bodies, (2) intraoral scan with the provisional restorations in place, and (3) extraoral scan of the provisionals with a gingival barrier for alignment. The datasets were merged in CAD software to replicate critical and subcritical contours for the definitive prostheses. The three-scan protocol enabled an accurate transfer of the conditioned mucosal contours, facilitating the design of definitive implant-supported crowns with esthetic integration and tissue harmony. This approach avoided analog impressions and minimized digital complexity, suggesting a potentially efficient and biologically respectful workflow for soft tissue-driven implant rehabilitation in single-tooth or short-span cases. The digitally guided three-scan protocol provides a practical clinical method to replicate peri-implant mucosal contours following immediate implant placements and augmentations. Further studies are required to validate its reproducibility and long-term outcomes.

**KEYWORDS:** Dental implants; Intraoral scanner; CAD/CAM; Dental prosthesis design.



**RESUMEN:** El propósito de este reporte es describir un flujo de trabajo digital simplificado para transferir perfiles de emergencia condicionados tras colocaciones inmediatas de implantes con manejo de tejidos duros y blandos. Una mujer de 50 años con fracturas en dos premolares maxilares fue tratada mediante extracciones atraumáticas, colocaciones inmediatas de implantes, regeneración ósea guiada con un xenoinjerto particulado e injerto de tejido conectivo. Se colocaron pilares de cicatrización para favorecer la maduración tisular inicial. Tras un período de cicatrización de 12 a 16 semanas, los implantes fueron activados y se entregaron restauraciones provisionales atornilladas para acondicionar la mucosa periimplantaria. Una vez alcanzados perfiles de emergencia estables, en la semana 24 se implementó un protocolo digital con tres escaneos coordinados: (1) escaneo intraoral con los scan bodies, (2) escaneo intraoral con las restauraciones provisionales en boca y (3) escaneo extraoral de las provisionales con una barrera gingival para facilitar la alineación. Los registros se integraron en software CAD para replicar los contornos críticos y subcríticos en las prótesis definitivas. El protocolo de tres escaneos permitió una transferencia precisa de los contornos mucosos condicionados, facilitando el diseño de coronas definitivas implantosoportadas con integración estética y armonía tisular. Esta técnica evitó el uso de impresiones analógicas y redujo la complejidad digital, lo que sugiere un flujo de trabajo potencialmente eficiente y biológicamente respetuoso para rehabilitaciones guiadas por tejidos blandos en casos unitarios o de pequeño alcance. El protocolo digital guiado de tres escaneos constituye un método clínico práctico para replicar los contornos mucosos periimplantarios tras colocaciones inmediatas de implantes y aumentos tisulares. Se requieren estudios adicionales para validar su reproducibilidad y resultados a largo plazo.

**PALABRAS CLAVE:** Implantes dentales; Escáner intraoral; CAD/CAM; Diseño de prótesis dental.

## INTRODUCTION

Accurate replication of the peri-implant mucosal contour is fundamental to the long-term success of implant-supported prostheses, as it ensures soft tissue stability, esthetic integration, and biologic compatibility (1-4). In immediate implant placement cases involving guided bone regeneration and soft tissue augmentation, the outcome often depends on the precise transfer of the conditioned emergence profile (5-7).

Conventional analog techniques such as impression coping and elastomeric materials are highly technique-sensitive and susceptible to dimensional distortion. Similarly, digital workflows, although reducing material dependency, may also present inaccuracies depending not only on the software and hardware used but also on the operator's expertise in scanning and data alignment (3,4,8). While digital workflows have

minimized the reliance on physical materials, they often involve multi-step procedures (9) including segmentation, registration, and superimposition, which increase procedural complexity and the potential for error (10).

Capturing the three-dimensional architecture of conditioned peri-implant soft tissues remains clinically challenging, particularly following surgical and prosthetic soft tissue sculpting (9,11-13). There is a need for simplified, reproducible digital protocols that allow precise acquisition of peri-implant soft tissue morphology while preserving its architecture.

This clinical report presents a case where a simplified digital scanning protocol was used to transfer a conditioned emergence profile after soft tissue maturation following immediate implant placement with hard and soft tissue augmentation. A structured intraoral scanning sequence, using a

scan body and buccally positioned gingival barrier, enabled precise replication of the peri-implant mucosa for definitive prosthesis design (Table 1).

## CASE REPORT

### SURGICAL PHASE

A 50-year-old, systemically healthy woman presented with fractures in two maxillary premolars and high esthetic expectations. Clinical and cone-beam computed tomographic (CBCT) evaluation (Figure 1) supported a treatment plan involving atraumatic extraction followed by immediate implant placement (Type 1A) using bone-level tapered implants (Straumann® BLT, 3.3 × 10 mm and 3.3 × 12 mm, lot numbers PXL90 and KYK32) (5). The surgical procedure included simultaneous guided bone regeneration with a

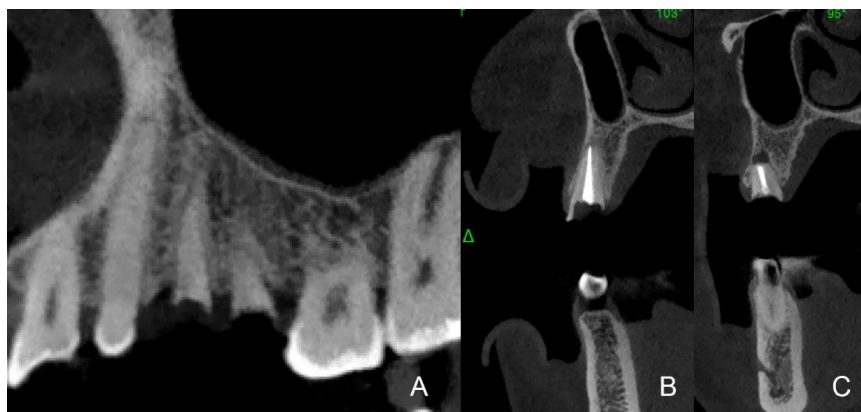
matrix bovine xenograft (Lumina Bone, Criteria, lot number LB0157/23\_2) and the placement of a subepithelial connective tissue graft harvested from the palate, positioned on the buccal aspect to preserve the buccal contour and enhance the gingival phenotype. Healing abutments (Straumann®) were placed to support mucosal maturation (Figure 2).

### PROVISIONALIZATION PHASE

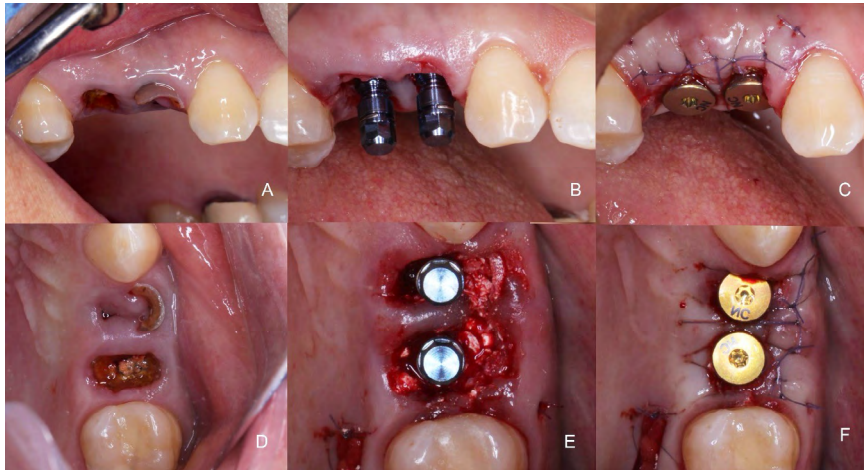
After a healing period, screw-retained provisional restorations were used to initiate peri-implant soft tissue conditioning. Progressive adjustments of their emergence profiles facilitated the development of a stable mucosal seal and formation of interproximal papillae, resulting in a symmetrical and biologically adapted soft tissue contour (1-4) (Figure 3).

**Table 1.** Summary of clinical procedures from surgical approach to implant-supported rehabilitation.

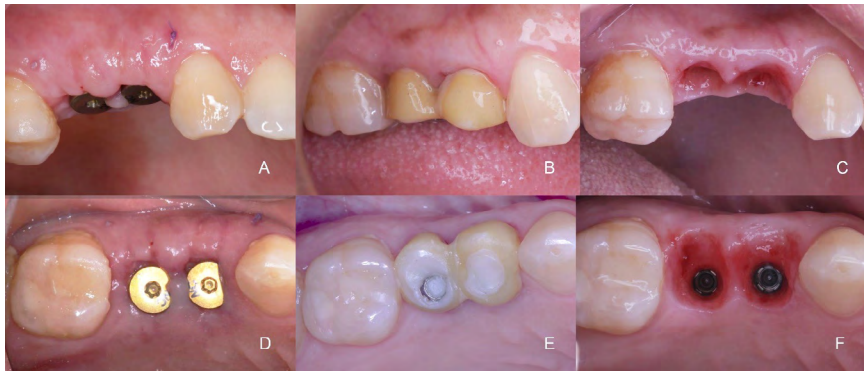Clinical stage	Timing	Phase
Atraumatic extraction; immediate implant placement; guided bone regeneration (GBR); connective tissue grafting; placement of healing abutments.	Day 1	Surgical Phase
Soft tissue conditioning and emergence profile development with a provisional restoration.	Weeks 12-16	Provisionalization Phase
Digital scanning to capture the conditioned soft tissue contours.	Week 24	Digital Workflow Phase (CAD-CAM)
Placement of the definitive implant-supported restoration.	Week 24	Final Rehabilitation Phase



**Figure 1.** CBCT imaging analysis of the maxillary right premolar region. A, Coronal view showing teeth 1.4 and 1.5 with apical radiolucencies indicative of chronic periapical lesions. B, Sagittal view of tooth 1.4 revealing failed endodontic treatment with associated bone loss. C, Sagittal view of tooth 1.5 showing similar periapical pathology. Both teeth were planned for extraction and immediate implant placement.



**Figure 2.** Surgical sequence of immediate implant placement with hard and soft tissue management. A, Initial clinical presentation showing root fracture and local infection. B, Atraumatic extraction and placement of two implants in the premolar region. C, Connective tissue grafting and primary closure. D, Occlusal view after socket debridement. E, Occlusal view confirming three-dimensional implant positioning. F, Healing abutments placed to support soft tissue maturation.



**Figure 3.** Soft tissue evolution during the provisionalization phase. A, Clinical view with healing abutments in place. B, Frontal view showing progressive soft tissue maturation and emergence profile development with a screw-retained provisional restoration. C, Mucosal contour after removal of the provisional, revealing a well-defined emergence profile. D, Occlusal view demonstrating mature peri-implant soft tissue contours. E, Provisional restoration guiding emergence profile development. F, Stabilized peri-implant tissues ready for the prosthetic phase.

## DIGITAL WORKFLOW PHASE: COMPUTER-AIDED DESIGN AND MANUFACTURING (CAD/CAM)

At this stage, the clinical objective was the accurate digital transfer of the conditioned peri-implant mucosa. Conventional analog (8) and digital workflows (10) often require customized scan abutments, gingival sculpting, or scan segmentation, which increase procedural complexity and risk of error. To streamline this process, a simplified intraoral scanning protocol was used to accurately replicate the emergence profile.

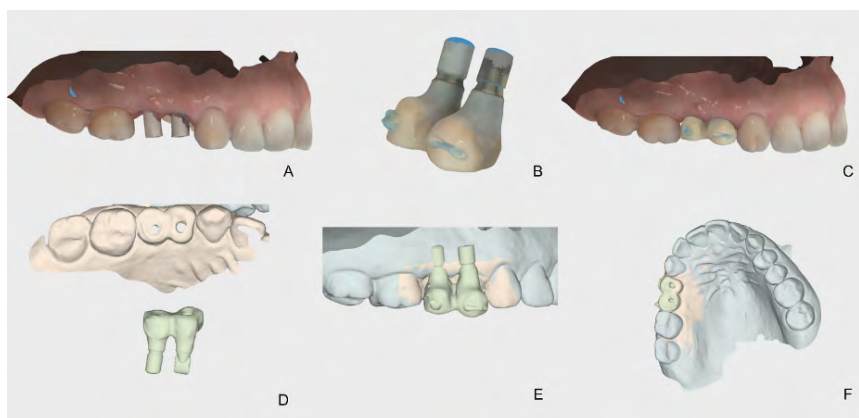
Immediately after removal of the provisional restoration, a digital scan of the maxillary arch was acquired using an intraoral scanner (Virtuo Vivo, Straumann), with the scan bodies fully seated and verified. This scan was saved as the "upper arch." The provisional restoration was then scanned extraorally to capture both critical and subcritical contours (11). A gingival barrier was applied to the buccal surface to serve as an optical landmark and to facilitate alignment accuracy during the merging process (9). This scan was saved as the "lower arch". Finally, the provisional was reinserted

intraorally, and a third scan was obtained to register its spatial relationship with the surrounding tissues; this scan was saved as the "bite registration."

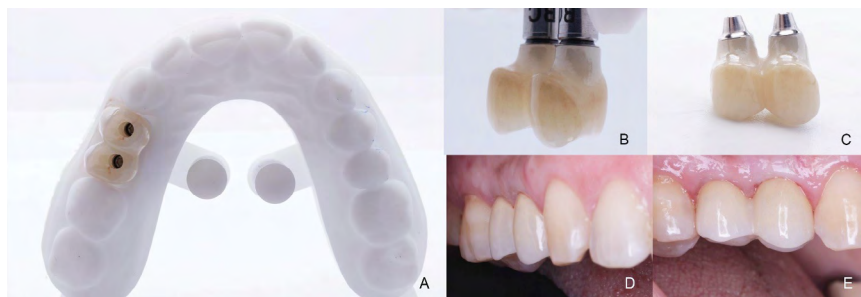
Using CAD software, the "bite registration" scan was aligned with the maxillary scan to digitally reposition the provisional. Occlusal reference points and scan body geometry were used to verify the accuracy of the superimposition. The final dataset was exported, and the scan bodies were virtually replaced with the corresponding library component. The definitive implant-supported crowns were then designed to replicate the conditioned mucosa and fabricated using either additive (3D printing) or subtractive manufacturing techniques (Figure 4).

## FINAL REHABILITATION PHASE

This digital protocol enabled the laboratory to deliver a definitive prosthesis that reproduced the emergence profile with high precision, resulting in esthetic harmony, functional integration, and complete patient satisfaction (1,2) (Figure 5).



**Figure 4.** Digital workflow for emergence profile transfer using a gingival barrier to enhance scan alignment. A, Maxillary arch scanned with scan bodies in place ("upper arch"). B, Provisional restoration scanned extraorally on a model with a gingival barrier to capture the emergence contour ("lower arch"). C, Provisional repositioned intraorally and scanned to register the conditioned soft tissue architecture ("bite registration"). D, Digital alignment of the provisional with the maxillary scan. E, Merged datasets used to guide the design of the definitive restoration. F, Final verification of emergence profile and mucosal contour in the digital model.



**Figure 5.** Definitive restoration and esthetic outcome. A, Definitive implant-supported crowns on the definitive cast, occlusal view. B, Restoration exhibiting an emergence profile adapted to the conditioned peri-implant mucosa. C, Intaglio surface of the two-unit zirconia restoration supported by titanium base abutments. D, Intraoral view demonstrating functional and esthetic integration. E, Final outcome showing soft tissue stability, symmetry, and harmonious.

## DISCUSSION

Precise transfer of the peri-implant emergence profile is essential to preserve soft tissue architecture and ensure both biologic and esthetic integration (1,2). This protocol addresses the challenge of replicating a conditioned mucosal contour following immediate implant placement with guided bone regeneration and soft tissue augmentation.

Unlike conventional analog workflows (8) or digital techniques (9,11-13) which involve multiple impression steps or segmentation, this method provides a simplified and standardized approach. It uses three coordinated scans (11): an intraoral scan with a scan body, an extraoral scan of the provisional, and a third intraoral scan with the provisional resealed. A buccally applied gingival barrier (9) serves as a landmark to improve alignment during scan merging.

Accurate replication of critical (emergence zone) and subcritical (tissue-supporting) contours

support peri-implant soft tissue architecture (1,2). By minimizing procedural steps, the protocol improves predictability and efficiency.

This protocol is most suitable for cases with mature and conditioned peri-implant soft tissues (3,4). It is not recommended in the absence of tissue conditioning, in immediate loading without provisionalization (5), or in full-arch cases requiring photogrammetry. Although simplified, the workflow still requires proficiency with digital tools and CAD software calibration (10).

Future integration of artificial intelligence may improve soft tissue detection, alignment, and data mergin (10). Long-term clinical studies are needed to evaluate soft tissue stability, esthetic outcomes, and patient satisfaction (6,7). This technique offers a practical, reproducible and biologically respectful solution for soft tissue-driven implant prosthodontics, especially in single-tooth or short-span cases requiring high precision with minimal complexity.

CONFLICTS OF INTEREST: The authors declare no conflict of interest.

PATIENT CONSENT: Written informed consent was obtained prior to the report.

FUNDING STATEMENT: This research did not receive any specific grant from public, commercial, or not-for-profit funding agencies.

AUTHOR CONTRIBUTION STATEMENT: Conceptualization: E.C.Q.; Methodology: E.C.Q.; Investigation: C.M.S. and E.C.Q.; Data curation, C.M.S.; Visualization: C.M.S. and E.C.Q.; Supervision: C.A.P.A.; Validation: C.A.P.A.; Writing-original draft preparation: C.M.S.; Writing-review and editing: C.A.P.A. All authors have read and agreed to the published version of the manuscript.

## REFERENCES

1. Gómez-Meda R., Esquivel J., Blatz M.B. The esthetic biological contour concept for implant restoration emergence profile design. *J Esthet Restor Dent.* 2021; 33 (2): 173-84.
2. Esquivel J., Gómez-Meda R., Villarroel M. Implant provisionalization: Decision-making and systematic workflow. *J Esthet Restor Dent.* 2024; 36 (6): 858-67.
3. Chu S.J., Kan J.Y., Lee E.A., Lin G.H., Jahangiri L., Nevins M., et al. Restorative emergence profile for single-tooth implants in healthy periodontium: Clinical guidelines and decision strategies. *Int J Periodontics Restor Dent.* 2019; 40 (1): 19-29.
4. Steigmann M., Monje A., Chan H.L., Wang H.L. Emergence profile design based on implant position in the esthetic zone. *Int J Periodontics Restor Dent.* 2014; 34 (4): 559-63.
5. Morton D., Wismeijer D., Chen S., Hamilton A., Wittneben J., Casentini P., et al. ITI Consensus Group 5 report: Protocols for implant placement and loading. *Clin Oral Implants Res.* 2023; 34 (2): 349-56.
6. Hamilton A., Gonzaga L., Amorim K., Wittneben J., Martig L., Morton D., et al. Selection criteria for immediate implant placement and loading for single-tooth replacement in the maxillary esthetic zone: Systematic review and meta-analysis. *Clin Oral Implants Res.* 2023; 34 (2): 304-48.
7. Wittneben J., Molinero-Mourelle P., Hamilton A., Alnasser M., Obermaier B., Morton D., et al. Clinical performance of immediately placed and loaded single implants in the esthetic zone: Systematic review and meta-analysis. *Clin Oral Implants Res.* 2023; 34 (2): 266-303.
8. Dos Santos P., Suzuki T.U., Martini A., Oliveira Reis B.D., Assunção W., Rocha E. Customization technique for emergence profile during implant transfer. *J Indian Prosthodont Soc.* 2019; 19 (2): 197-200.
9. Gallardo Y.N.R., Noriega J., Rodrigues-Olivio I., Sesma N. Digital technique to clone the emergence profile from provisional to definitive implant restorations. *J Prosthet Dent.* 2024; 132 (4): 598-602.
10. Revilla-León M., Gómez-Polo M., Vyas S., Barmak B.A., Gallucci G.O., Att W., et al. Artificial intelligence applications in dental implantology: Systematic review. *J Prosthet Dent.* 2023; 129 (2): 293-300.
11. Crockett R., Benko J., Chao D., Shah K.C. Customized digital impression technique to capture the developed emergence profile. *J Prosthet Dent.* 2019; 122 (4): 348-50.
12. Conejo J., Atria P.J., Hirata R., Blatz M.B. Copy-milling technique to duplicate the emergence profile in implant restorations. *J Prosthet Dent.* 2020; 123 (4): 671-4.
13. Doliveux S., Jamjoom F.Z., Nadra M., Gallucci G.O., Hamilton A. Fabrication technique for a customized emergence profile on 3D-printed models. *J Prosthet Dent.* 2020; 123 (4): 571-5.