

## Age influence in the natural resistance of white rat and mice to the protozoan *Toxoplasma gondii*

Olga M. Guerrero, Misael Chinchilla, Alfredo Castro and Elizabeth Abrahams

Centro de Investigación y Diagnóstico en Parasitología. Departamento de Parasitología, Facultad de Microbiología, Universidad de Costa Rica, San José, Costa Rica.

(Revised 7-XI-1994. Accepted 22-XI-1994)

**Abstract:** Groups of 1, 5, 10, 15 and 30 day old rats (Sprague Dawley) and Wistar mice were infected per os with different inocula of *Toxoplasma gondii* oocysts from an avirulent strain. Infection pattern was followed by determination of survival time, tissue lesions, parasite presence and serology. Although all the animals survived the total experimental period (30 day), there were important differences between both rodents regarding to *Toxoplasma* natural resistance. Brain cysts, as well as tachyzoites in other organs were regularly present in mice but not in rats. On the other hand, most of the organs from mice presented characteristic *T. gondii* lesions, while in rats a normal tissues were observed, with the exception of an acute reaction found in the brain of a 15d old animal.

**Key words:** Infection, resistance, protozoan, histology.

Differences in rat natural resistance against *Toxoplasma gondii* have been studied, specially in relation to age variations.

Lainson (1955) found that 21 day (d) old rats (*Rattus coucha*) were resistant to this parasite while Lewis and Markell (1958) reported that newborn Wistar rats presented more susceptibility to *Toxoplasma* tachyzoites infection than 3 week old animals. However, Chinchilla *et al.* (1981), using quantified inocula, established that natural resistance in rats (Sprague Dawley) starts at an early age and that  $10^7$  to  $10^8$  tachyzoites of the RH strain are needed to kill newborn animals. In these, as well as in other studies (Araujo *et al.* 1976, Ruchman and Fowler 1951, Remington *et al.* 1961, Dubey *et al.* 1991), *Toxoplasma* tachyzoites were injected i.p. Therefore it was interesting to determine the rat susceptibility to oocysts oral inoculation. In addition, mice were studied identically, in order to compare the results in a resistant and a susceptible animal. The differences observed in *Toxoplasma* infection for both rodents are reported in this paper.

## MATERIAL AND METHODS

Sprague Dawley rats and Wistar mice of different ages (1, 5, 10, 15) were caged with their mothers. All rodents, including 30 days animals were fed *ad libitum* with water and animal food.

Oocysts for infections were obtained and prepared as already described (Dubey *et al.* 1970, 1972). Groups of 20 rats and 20 mice were infected per os with  $10^4$ ,  $10^5$ ,  $10^6$  and  $10^7$  *Toxoplasma* oocysts (100 g body weight for rat) and  $10^0$ ,  $10^1$ ,  $10^2$  and  $10^3$  oocysts (1.5 g body weight per mouse).

The survival time was recorded and those that remained for 30 d were bled by cardiac puncture for serologic analysis by the Sabin and Feldman test. In addition, brain of all the animals were directly studied for *Toxoplasma* cysts.

Portions of brain, liver, spleen, lung, lymph nodes and heart were fixed in 10% formalin (pH 7) and studied for *T. gondii* presence.

## RESULTS AND DISCUSSION

All infected animals survived the experimental period, 30 days, according to our model.

Brain apposition smears of 20 to 80% of newborn (1 day) and 5 day rats infected with  $10^4$  and  $10^5$  oocysts, presented *Toxoplasma* cysts. Despite of the inocula, 50 per cent of the 10d old rats presented cysts. Also 15 and 30d old rats infected with higher number of oocysts presented cysts (Fig. 1A). *Toxoplasma* antibodies were found in all the rats. Mice infected with  $10^0$  or  $10^1$  oocysts presented variable results regarding brain cyst presence.

Brains of all the one day old mice infected with  $10^2$  or  $10^3$  oocysts and all the 30 day old infected animals were positive by *T. gondii* cysts, while low infections were observed in 5 day old mice (Fig. 1B).

Sabin-Feldman test was positive in all the animals inoculated with higher inocula (Fig. 1C).

One day old mice infected with  $10^0$  or  $10^1$  oocysts did not present parasites in any organ but 5 or 10 day old animals inoculated with higher number of oocysts, had *Toxoplasma* in the liver, spleen and lung. Fifteen and 30 day old mice presented parasites in all the organs (Table 1).

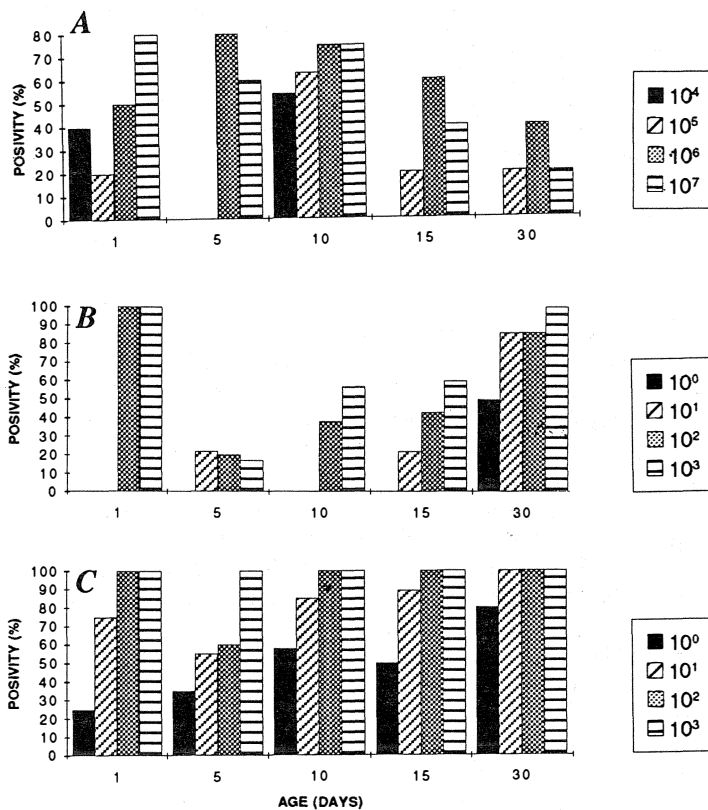


Fig. 1.A. Positivity (%) by brain cyst presence of different age rats infected with *T. gondii* oocysts. B. Positivity (%) by brain cyst presence of different age mice infected with *T. gondii* oocysts. C. Serology (Sabin-Feldman) of mice (different ages) infected with *T. gondii* oocysts.

TABLE 1  
*Toxoplasma gondii* presence in organs of oocyst infected mice (different ages)

Organ	Inocula(oocysts** / animal)			
	10 <sup>0</sup>	10 <sup>1</sup>	10 <sup>2</sup>	10 <sup>3</sup>
Liver	+(15) *	+(15,30)	+(10,15,30)	+(5,10,15,30)
Spleen	+(15) *	+(15,30)	+(10,15,30)	+(5,10,15,30)
Brain	—	+(30)	+(5,30)	+(30)
Heart	—	—	—	+(30)
Lymph node	—	+(30)	—	+(5)
Lung	—	+(30)	+(15,30)	+(10,15,30)

\* Age (days). At least one animal was positive at the indicated age.

+ parasite presence.

\*\* 1.5g body weight for mouse.

When tissues from rats were studied, *Toxoplasma* cysts were found occasionally in the brain and once in the heart. There were not any important lesions in the studied organs, except an acute inflammation reaction observed in the brain of a 15d old rat. In this case, some free tachyzoites and an apparent young cyst surrounded by lymphoid infiltration, edema and necrosis were observed.

Certain characteristic lesions (McLeod *et al.* 1984) were observed in lung, liver and spleen. In the heart of one animal, a slight lesion was present and in the brain we found *T. gondii* cysts without any important inflammatory reactions. Resistance of rodents to *Toxoplasma* infection depends on several factors such as genetic differences, animal strain, inoculation route and probably other aspects. Lainson (1955) working with the RH strain, found that 21 day old sucking rats presented the same resistance as adult animals. On the other hand, studies carried out by Chinchilla *et al.* (1981) using the same *Toxoplasma* strain, demonstrate that the survival time in one or 5d old rats infected with 10<sup>4</sup> or 10<sup>5</sup> parasites was lower than that of 15 or 30 day old rats. In these experiments it has been demonstrated that rats are also resistant to oocyst oral infection.

Furthermore, an increase in rat natural resistance according to the animal age was also

demonstrated. In fact, the number of animals with brain *Toxoplasma* cysts was higher in 10 or less day old rats, even when older animals received more oocysts due to their body weight (Fig. 1A).

On the other hand, all mice survived 30 day and presented positive serology. Probably due to the low inocula used for younger animals, 30 day old mice presented a higher brain positivity (Fig. 1B). Similar results reported Gardner and Remington in 1978 who found that 11 month old mice had more *Toxoplasma* cysts than 4 month old animals.

Although there were not important differences in susceptibility due to the age in rats and mice, the presence of lesions caused by the parasite in all mice organs, as already reported by McLeod *et al.* (1984), and the absence of important pathology in rats, confirm the natural resistant of these animals. This fact and the biology and immunology similarity with human beings as suggested by Godard *et al.* (1990), makes this rodent as an adequate experimental model to study the congenital toxoplasmosis (Dubey and Shen 1991).

## RESUMEN

Ratas y ratones de 1, 5, 10, 15 y 30 days fueron inoculados con diferentes concentraciones de oocistas de *T. gondii*. De acuerdo a

los parámetros de supervivencia, lesiones tisulares, presencia del parásito y serología quedó demostrada, una vez más, la mayor resistencia de la rata blanca, independientemente de la edad del animal.

#### ACKNOWLEDGEMENTS

This study was supported by grants No. 430-92-304 and 430-92-905 from the Vicerrectoría de Investigación, Universidad de Costa Rica. The authors thank Eddy Camacho for animal care and Aleida Quirós for her assistance.

#### REFERENCES

- Araujo, F.G., 1991. Depletion of L3T4+(CD4+) T lymphocytes prevents development for resistance to *Toxoplasma gondii* in mice. *Infect. Immun.* 59:1614-1619.
- Chinchilla, M., M. Alfaro & O.M. Guerrero. 1981. Adaptación natural de rata blanca a *Toxoplasma gondii*. *Rev. Biol. Trop.* 29: 273-282.
- Dubey, J.P., N.L. Miller & J.K. Frenkel. 1970. Characterization of the new fecal form of *Toxoplasma gondii*. *J. Parasitol.* 56:447-456.
- Dubey, J. P. & S.K. Shen. 1991. Rat model of congenital Toxoplasmosis. *Inf. Immun.* 59:3301-3302
- Dubey, J.P., G.V. Swan & J. K. Frenkel. 1972. A simplified method for isolation of *Toxoplasma gondii* from the feces of cats. *J. Parasitol.* 58:1005-1006.
- Gardner, I.D. & J.S. Remington. 1978. Aging and the immune response. I. Antibody formation and chronic infection in *Toxoplasma gondii* infected mice. *J. Immunol.* 120:939-943.
- Godard, I., F. Darcy, D. Daeslee, J.P. Dessaint & A. Capron. 1990. Isotypic profiles of antibody responses to *Toxoplasma gondii* infection in rats and mice: kinetic study and characterization of target antigens of immunoglobulin A antibodies. *Infect. Immun.* 58:2446-2451.
- Lainson, R. 1955. Toxoplasmosis in England II-Variation factors in the pathogenesis of *Toxoplasma* infections: the sudden increase in virulence of a strain after passage in multimate rats and canaries. *Ann. Trop. Med. Parasitol.* 49:384-416.
- Lewis, W.P. & E.K. Markell. 1958. Acquisition of immunity to toxoplasmosis by the newborn rat. *Exp. Parasitol.* 7:463-467.
- McLeod, R., R.G. Estes., D.G. Mack & H. Cohen. 1984. Immune response of mice to ingested *Toxoplasma gondii*: a model of *Toxoplasma* infection acquired by ingestion. *J. Infect. Dis.* 149:234-244.
- Remington, J. S., M.L. Melton, & L. Jacobs. 1961. Induced and spontaneous recurrent parasitemia in chronic infections with avirulent strains of *Toxoplasma gondii*. *J. Immunol.* 87:578-581
- Ruchman, I. & J.C. Fowler. 1951. Localization and persistence of *Toxoplasma* in tissues of experimentally infected white rats. *Proc. Soc. Exptl. Biol. Med.* 76:793-796.